



## Successful anesthetic and airway management in Coffin-Siris syndrome with congenital heart disease: Case report

Dilek Altun, Güray Demir, Asude Ayhan & Ayda Türköz

To cite this article: Dilek Altun, Güray Demir, Asude Ayhan & Ayda Türköz (2016) Successful anesthetic and airway management in Coffin-Siris syndrome with congenital heart disease: Case report, Egyptian Journal of Anaesthesia, 32:4, 593-596, DOI: [10.1016/j.egja.2016.08.012](https://doi.org/10.1016/j.egja.2016.08.012)

To link to this article: <https://doi.org/10.1016/j.egja.2016.08.012>



© Publishing services by Elsevier  
B.V. on behalf of Egyptian Society of  
Anesthesiologists.



Published online: 17 May 2019.



Submit your article to this journal [↗](#)



Article views: 5



View Crossmark data [↗](#)



Citing articles: 1 View citing articles [↗](#)



Case report

# Successful anesthetic and airway management in Coffin-Siris syndrome with congenital heart disease: Case report



Dilek Altun<sup>a,\*</sup>, Güray Demir<sup>b</sup>, Asude Ayhan<sup>c</sup>, Ayda Türköz<sup>d</sup>

<sup>a</sup> Baskent University, Istanbul Training and Research Center, Anesthesiology and Reanimation (Cardiovascular Intensive Care Unit), Turkey

<sup>b</sup> Bakirkoy Dr. Sadi Konuk Training & Research Hospital, Anesthesiology and Reanimation, Turkey

<sup>c</sup> Baskent University, Ankara Training and Research Center, Anesthesiology and Reanimation, Turkey

<sup>d</sup> Baskent University, Istanbul Training and Research Center, Anesthesiology and Reanimation, Turkey

Received 15 March 2016; accepted 16 August 2016  
Available online 9 September 2016

## KEYWORDS

Coffin-Siris syndrome;  
Congenital heart disease;  
Laryngomalacia;  
Difficult airway

**Abstract** *Introduction:* Coffin-Siris Syndrome (CSS) is a rare congenital malformation syndrome characterized with mild to severe developmental and cognitive delay, coarse facial features, fifth digit aplasia or hypoplasia associated with ectodermal, constitutional and organ-related (cardiac/neurological/gastrointestinal/genitourinary...) anomalies. Here, we have reported a successful anesthetic and airway management in a case of 5-year old boy with CSS who underwent congenital heart surgery. *Case report:* A 5-year old male child weighing 14 kg, who was diagnosed as CSS underwent operation for the repair of partial atrioventricular septal defect and secundum atrial septal defect. This case report pertains to the successful anesthetic and airway management in the background of difficult airway and presence of various cardiac abnormalities.

Although patient was anticipated to be difficult for intubation due to laryngomalacia, micrognathia, macroglossia, tracheal intubation was performed without any difficulty using fiber-optic laryngoscopy. At the end of the operation, the patient was transferred to the cardiovascular intensive care unit and was extubated when his spontaneous breathing was satisfactory 4 h later after the operation without any complication.

*Results and discussion:* CSS often requires surgery and anesthetic intervention. The abnormal facial and airway as well as mental related features may lead intubation difficult, potentially due to short neck, large tongue and lips, poor dentition and poor communication.

Thinking that the practicing anesthetist needs to have appropriate knowledge for this entity and the equipment for managing difficult airway should readily be available. One of these patients which successfully managed without any complication was described in this brief report.

© 2016 Publishing services by Elsevier B.V. on behalf of Egyptian Society of Anesthesiologists. This is an open access article under the CC BY-NC-ND license (<http://creativecommons.org/licenses/by-nc-nd/4.0/>).

\* Corresponding author at: Baskent University, Istanbul Training and Research Center, Department of Anaesthesiology and Reanimation (CICU), Oymaci Street, No: 734662 Altunizade, Istanbul, Turkey. Tel.: +90 532 493 27 67; fax: +90 216 651 98 58. E-mail address: [drdilekaltun@hotmail.com](mailto:drdilekaltun@hotmail.com) (D. Altun).

Peer review under responsibility of Egyptian Society of Anesthesiologists.

<http://dx.doi.org/10.1016/j.egja.2016.08.012>

1110-1849 © 2016 Publishing services by Elsevier B.V. on behalf of Egyptian Society of Anesthesiologists.

This is an open access article under the CC BY-NC-ND license (<http://creativecommons.org/licenses/by-nc-nd/4.0/>).

## 1. Introduction

Coffin-Siris Syndrome (CSS), known as “fifth digit syndrome” is a rare congenital anomaly characterized by many variable signs and symptoms, varying degree of intellectual and motor developmental problems, “coarse” facial features, abnormalities of the fifth fingers; cardiac/neurological/gastrointestinal/genitourinary anomalies. Respiratory infections and difficult feeding are common during infancy [1–3].

Congenital heart abnormalities are also heterogeneous, observed more than 30% of cases [4].

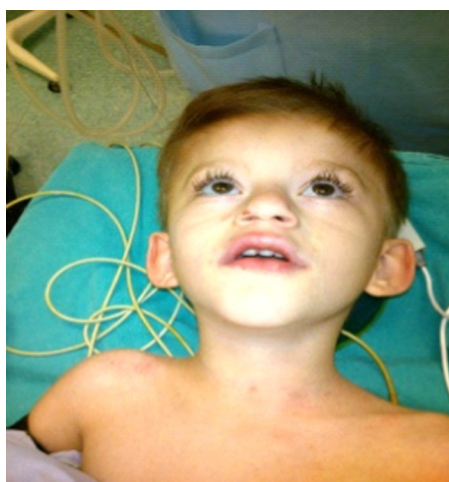Airway management can be difficult because micrognathia, macroglossia, hypotonia, and lax joint can also be the problem as well as mental status due to poor communication [2].

This report presents a successful anesthetic and airway management in a 5-year old boy with CSS who underwent congenital heart surgery.

## 2. Case report

A five-years-old boy with mental retardation, a height of 109 cm and weighs 14 kg having CSS was admitted to our hospital for the operation of congenital heart disease. At birth he had hypothyroidism, nephrocalcinosis, respiratory problems including snoring, noisy breathing, change of voice, recurrent croup, sleep apnea, partial atrioventricular septal defect (AVSD) with secundum atrial septal defect (ASD). Recurrent respiratory infections due to aspiration persisted throughout early childhood and feeding difficulties were present. Mental development was also significantly retarded.

Physical examination revealed three major must-have features of CSS, namely retarded mental and cognitive growth; coarse facies reflected by flat nasal bridge, abnormal ears, wide mouth, microglossia, full lips and micrognathia; hypoplastic fifth finger terminal phalanx and the three minor findings of the syndrome (hypotonia, pectus carinatus and laryngomalacia). Muscles were hypotonic and pectus carinatus was prominent (Fig. 1). The patient was scheduled for cardiac surgery for his cardiac abnormalities, partial AVSD and secundum ASD.

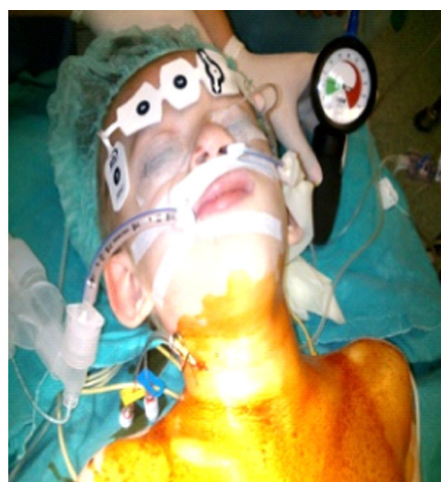

After premedication with midazolam (0.05 mg/kg IV) the patient was admitted to operating room. Continuous monitoring was performed by evaluation of noninvasive blood pressure, pulse-oximetry and electrocardiography. His initial vital signs showed blood pressure (BP) of 91/57 mmHg, pulse rate of 113 beats/min, respiratory rate of 31/min and oxygen saturation rate of 99%, and skin temperature was 36 °C.

General anesthesia was initiated with 2 mcg/kg/min remifentanyl infusion. Five minutes later, after establishing successful bag mask ventilation fiber-optic bronchoscopy (FOB) was carried out. Cuffed endotracheal tube number 5.5 mm internal diameter was safely placed into the trachea without trouble. Endotracheal cuff pressure was maintained among 10–15 cm H<sub>2</sub>O which was continuously monitored till extubation (Fig. 2). After confirming effective endotracheal intubation, sodium thiopental 4 mg/kg and rocuronium 0.6 mg/kg were given. Anesthesia was maintained with isoflurane 50% oxygen/air and continuous infusion of remifentanyl (0.01–1 mcg/kg/min) until the end of surgical procedures with the aim of keeping index of consciousness (IOC) values within 40–60, heart rate and blood pressure within the 30% range.

Depth of anesthesia was monitored with index of consciousness (IOC, Morpheus Medical, Spain) [K]. Cerebral (rSO-C) and somatic (rSOS) tissue oxygen saturation were monitored, were stable, and did not change compared to the initial values during operation (Fig. 3). Data were continuously updated at two readings per second and average recordings saved at 1 min intervals (Pediatric SomaSensor, Model SPFB, for children 4–40 kg by Somanetics Corporation, Troy, Michigan for the INVOS 5100 Cerebral oximeter). Operation and anesthesia were uneventful. Remifentanyl was preferred for slow induction of anesthesia being advantageous for hemodynamic stability in this case.

After operation, he was transferred to cardiovascular intensive care unit (CICU) where remifentanyl infusion and IOC monitoring were continued. Sedation level was assessed by Ramsay Sedation Score (RSS), and pain level was evaluated by Children’s Hospital Eastern Ontario Pain Scale (CHEOPS). In CICU, the patient was connected to Servo 300 ventilator (Siemens-Elema, Solna, Sweden). He received time-cycled SIMV volume control mode. When he remained stable



Figures 1–2 Facial features of Coffin-Siris Syndrome.

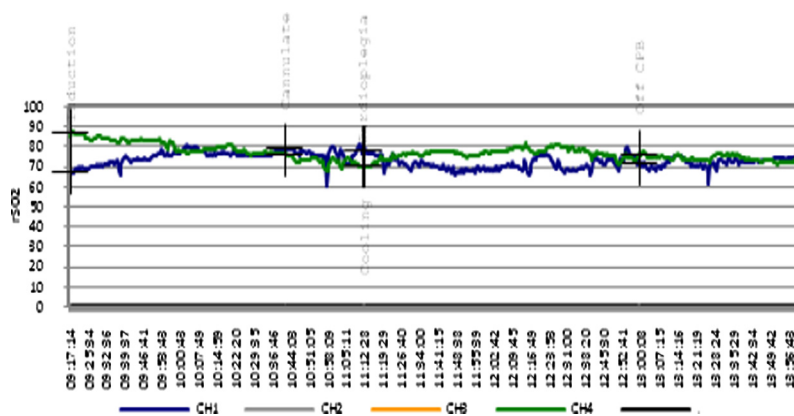


Figure 3 Perioperative rSO<sub>2</sub>-S/rSO<sub>2</sub>-C values.

clinically, ventilator support was changed first to SIMV rate of 8–10, PEEP 5 cm H<sub>2</sub>O and PS 6–8 cm H<sub>2</sub>O, then to CPAP of 5 cm H<sub>2</sub>O and PS 6–8 cm H<sub>2</sub>O. Then the patient was extubated four hours after operation without any problem. He woke up and started breathing spontaneously with a normal respiratory rate, tidal volume greater or equal to half the normal tidal volume for his age. He was discharged from CICU within 24 h and from hospital within 6 days without any complication.

### 3. Discussion

Congenital cardiac and vascular anomalies are not unique for, but frequently associated with CSS and significantly associated with congenital and acquired airway anomalies. In these patients, airway management can be difficult usually due to micrognathia and macroglossia [4]. Laryngomalacia is the most common congenital laryngeal anomaly and most frequent cause of inspiratory stridor and airway obstruction [5–7].

Providing general anesthesia to patients with tracheolaryngomalacia can be an important challenge to the anesthesiologist in terms of type of anesthetic agent used, airway and ventilator management. Easy collapsibility of trachea during coughing and recovery from anesthesia may make intubation extremely difficult, leading to prolonged intubation and ventilation in these patients [8,9].

The most common cause of mortality and serious morbidity due to anesthesia is from airway problems. The Flexible fiberoptic endoscope is the most valuable single tool available for anesthesiologist to manage difficult airway [10].

Fiber-optic intubation in awake state is recommended in cases with difficult airway. It could have been attempted at the onset with deeper sedation if spontaneous respirations could be maintained [10,11]. Alternatively, general anesthesia could have been induced and intubation performed with fiberoptic technique. In our case owing to the risks of detrimental effects of stress response on cardiac tissue in an awake state, we decided to proceed with intubation after establishing adequate depth of anesthesia.

After operation patient was transferred to CICU. We planned to apply fast track extubation that is why we used ultra-short acting opioid, remifentanyl, during surgery and CICU [12,13].

Endotracheal cuff (ETTc) pressure monitored till extubation between the ranges of 10–15 cmH<sub>2</sub>O. Tracheal tube cuff

should ideally seal the airway without compromising mucosal perfusion, and cuff pressure should be maintained around 10–15 cmH<sub>2</sub>O [14,15].

Achieving adequate depth of anesthesia during surgical procedures is desirable. We used IOC monitoring to determine the depth of anesthesia and to maintain optimal conditions for extubation [16,17].

With using transtracheal block and ultra-short opioid infusion, in order to provide smooth and uneventful perioperative course, successful fiberoptic intubation has been done in a patient with Coffin-Siris syndrome who has difficult airway and laryngomalacia. Moreover, by using ultra-short opioid infusion early extubation could be done.

We can conclude that for successful airway and anesthetic management in a case of CSS, one should have thorough and deep knowledge about the various anatomic abnormalities and pathophysiologic considerations so as to prevent any clinical disaster in the operation, especially for an elective surgery.

### Conflict of interest

The authors declare that there are no conflict of interests.

### References

- [1] Dimaculangan D, Lokhandwala B, Woody DR, Gross R. Difficult airway in a patient with Coffin-Siris syndrome. *Anesth Analg* 2001;92(2):554–5.
- [2] Khariwala Samir S, Lee Walter T, Koltai Peter J. Laryngotracheal consequences of pediatric cardiac surgery. *Arch Otolaryngol Head Neck Surg* 2005;131(4):336–9. <http://dx.doi.org/10.1001/archotol.131.4.336>.
- [3] Fleck BJ, Pandya A, Vanner L, Kerkerling K, Bodurtha J. Coffin-Siris syndrome: review and presentation of new cases from a questionnaire study. *Am J Med Genet* 2001;99(1):1–7.
- [4] Nemani L, Barik R, Patnaik AN, Mishra RC, Rao AM, Kapur P. Coffin-Siris syndrome with the rarest constellation of congenital cardiac defects: a case report with review of literature. *Ann Pediatr Cardiol* 2014;7(3):221–6. <http://dx.doi.org/10.4103/0974-2069.140859>.
- [5] Kosho T, Miyake N, Carey JC. Coffin-Siris syndrome and related disorders involving components of the BAF (SWI/SNF) complex: historical review and recent advances using next generation sequencing. *Am J Med Genet C Semin Med Genet* 2014;166C(3):241–51.

- [6] Cheng KS, Ng JM, Li HY, Hartigan PM. Vallecular cyst and laryngomalacia in infants: report of six cases and airway management. *Anesth Analg* 2002;95(5):1248–50 [table of contents].
- [7] Midulla F, Guidi R, Tancredi G, Quattrucci S, Ratjen F, Bottero S, et al. Microaspiration in infants with laryngomalacia. *Laryngoscope* 2004;114:1592–6.
- [8] Austin J, Ali T. Tracheomalacia and bronchomalacia in children: pathophysiology, assessment, treatment and anaesthesia management. *Paediatr Anaesth* 2003;13:3–11.
- [9] Suto Y, Tanabe Y. Evaluation of tracheal collapsibility in patients with tracheomalacia using dynamic MR imaging during coughing. *AJR: Am J Roentgenol* 1998;171(2):393–4.
- [10] Stackhouse RA. Fiberoptic airway management. *Anesthesiol Clin North Am* 2002;20:930–51.
- [11] Rodrigues Ascedio Jose, Scordamaglio Paulo Rogério, Palomino Addy Mejia, De Oliveira Eduardo Quintino, Jacomelli Marcia, Figueiredo Viviane Rossi. Difficult airway intubation with flexible bronchoscope. *Rev Bras Anesthesiol* 2013;63(4):358–61.
- [12] Vricella LA, Dearani JA, Gundry SR, Razzouk AJ, Brauer SD, Bailey LL. Ultra fast track in elective congenital cardiac surgery. *Ann Thorac Surg* 2000;69(3):865–71.
- [13] Schuller JL, Bovill JG, Nijveld A, Patrick MR, Marcelletti C. Early extubation of the trachea after open heart surgery for congenital heart disease: a review of 3 years' experience. *Br J Anaesth* 1984;56:1101–8.
- [14] Guyton DC, Barlow MR, Besselievre TR. Influence of airway pressure on minimum occlusive endotracheal tube cuff pressure. *Crit Care Med* 1997;25:91–4.
- [15] Efferen LS, Elsagr A. Post-extubation stridor: risk factors and outcome. *J Assoc Acad Minor Phys* 1998;9(4):65–8.
- [16] Punjasawadwong Y, Phongchiewboon A, Bunchungmongkol N. Bispectral index for improving anaesthetic delivery and postoperative recovery. *Cochrane Database Syst Rev* 2014(6): CD003843. <http://dx.doi.org/10.1002/14651858>.
- [17] Nguyen-Ky T, Wen PP, Li Y, Gray R. Measuring and reflecting depth of anesthesia using wavelet and power spectral density. *IEEE Trans Inf Technol Biomed* 2011;15(4):630–9.