

case report

Retroperitoneal paraganglioma presenting as right-sided varicocele: case report

Nihat Ates,^a Mustafa Yüksel,^b Serdar Yılmaz,^c Mani Habibi,^d Tumay Ipekci^e

From the ^aDepartment of Urology, Antalya Atatürk State Hospital, Antalya, Turkey; ^bDepartment of Urology, Konya Training and Research Hospital, Antalya, Turkey; ^cDepartment of Urology, Konya Training and Research Hospital, Antalya, Turkey; ^dDepartment of General Surgery, Esenler Maternity and Child Health hospital, Istanbul, Turkey; ^eDepartment of Urology, Baskent University Medical Faculty, Alanya Practice and Research Center, Alanya, Turkey

Correspondence: Dr. Mani Habibi · Department of General Surgery, Esenler Maternity and Child Health Hospital, Istanbul, Turkey, Havaalanı Mh., Taşocağı Cd. No:19 Esenler, Istanbul · T: +90 212 440 39 00 F: +90 212 629 13 03 · manihabibi@gmail.com

Ann Saudi Med 2016; 36(2): 148-151

DOI: 10.5144/0256-4947.2016.21.3.1135

Varicocele, the most important identifiable pathological cause of male infertility, is rarely observed on the right side. In isolated cases of right-sided varicocele, the presence of retroperitoneal masses compressing the inferior vena cava should be considered by further investigation. The retroperitoneal masses that are detected tend to grow rapidly due to their location and may be very large at the time of diagnosis. Soft tissue sarcomas are the most common cause of retroperitoneal masses, while paragangliomas are rare causes. Retroperitoneal paragangliomas should be diagnosed via detection of symptoms caused by hormonal activity, observation of the compression effect of the mass, or incidentally during imaging studies.

SIMILAR CASES PUBLISHED: This study presents the first case of retroperitoneal paraganglioma in a 41-year old man as isolated right-sided varicocele that has been described in the published reports.

Varicocele is the most important identifiable pathological cause of male infertility. Although presenting on the left side in 85% to 90% of all cases, varicocele has rarely been observed on the right side in isolated cases.¹ In cases of right-sided varicocele, the presence of retroperitoneal masses should be considered and further studies be conducted for its detection. Although rarely observed, these retroperitoneal masses that are detected grow rapidly due to their location, and may be very large at the time of diagnosis. Soft tissue sarcomas are the most common cause of retroperitoneal masses, while paragangliomas are rare causes.² In this study, we present the first case of retroperitoneal paraganglioma as isolated right-sided varicocele that has been described in the published reports.

CASE

A 41-year-old man was admitted to our outpatient clinic suffering from severe right-sided scrotal pain. Physical examination revealed grade 3 isolated right-sided varicocele (**Figure 1**), while abdominal examination revealed no palpable masses. The review of his medi-

cal history and records revealed no personal or family history of varicocele or related diseases. Right-sided varicocele showing reflux flow via the Valsalva maneuver was confirmed by scrotal Doppler ultrasonography.

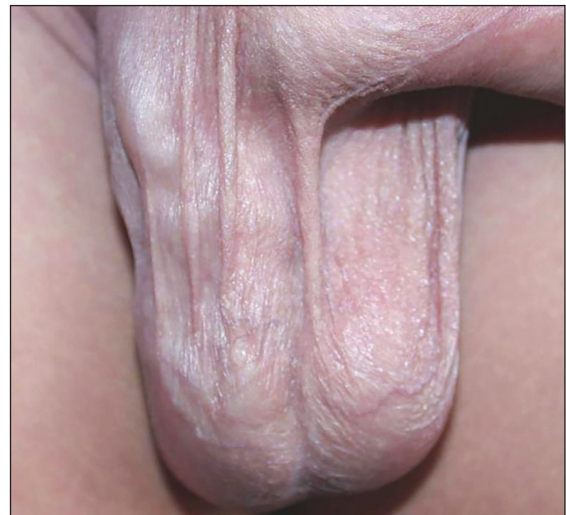

Figure 1. Grade 3 isolated right-sided varicocele.

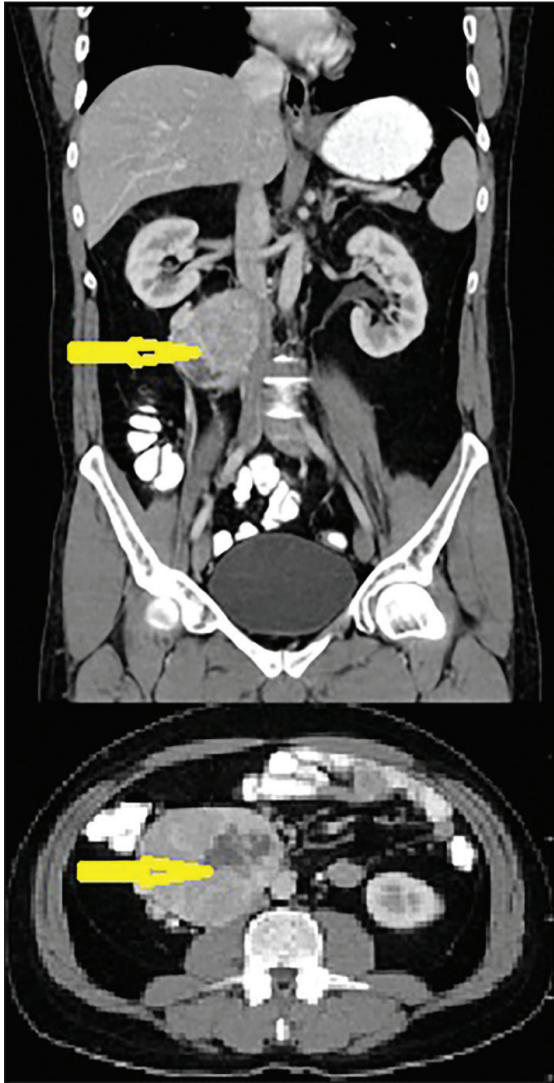

Figure 2. CT image of a 92×87 mm², irregularly shaped, contrast-enhanced mass detected in the precaval and aortocaval areas at an infrarenal level contiguous with the duodenum.

The parameters of the spermiogram test were normal. Contrast-enhanced CT detected an irregularly shaped mass measuring 92×87 mm² in the precaval and aortocaval areas at an infrarenal level contiguous with the duodenum (**Figure 2**). Although the mass was compressing the inferior vena cava (IVC), no invasion was detected.

With an initial diagnosis of retroperitoneal mass, laparotomy was performed. During the removal of the retroperitoneal mass contiguous with the IVC and duodenum, no symptoms of catecholamine discharge, such as hypertension or abnormalities in electrocardiography measurements, were observed. The pathological report described the detection of a capsulated, well-

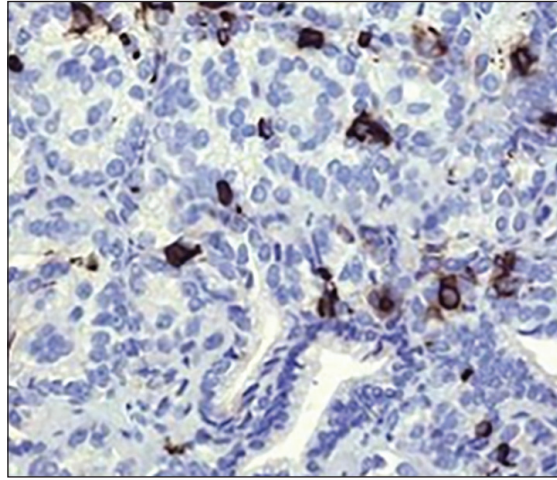


Figure 3. Positive staining with chromogranin in immunohistochemical examination.

grained tumor with cells containing pleomorphic-hyperchromatic nuclei and wide cytoplasm and displaying intercellular mitosis. Histochemical staining revealed the sustentacular cells to be S100 protein positive and the tumor cells to be synaptophysin positive and chromogranin positive. Based on these histochemical findings, paraganglioma was diagnosed (**Figure 3**). Postoperative urinary metanephrine and normetanephrine levels were normal, and the patient was discharged without any complications on postoperative day 4. Metaiodobenzylguanidine (MIBG) scintigraphy performed on the second postoperative week showed no metastasis or local enhancement.

DISCUSSION

Defined as the dilatation of pampiniform plexus veins, varicocele affects 10% to 15% of the male population and is an important cause of male infertility.^{3,4} The most common type of varicocele is isolated left-sided disease due to the entrance angle of the left testicular vein into the left renal vein. Bilateral varicocele is observed in 10% of cases, while right-sided varicocele is rarely alone.¹ As the right gonadal vein enters directly into the IVC, the presence of retroperitoneal masses compressing the IVC should be considered in cases of isolated right-sided varicocele. Although the most common causes of these retroperitoneal masses are renal masses and sarcomas, adrenocortical carcinoma,^{5,6} Burkitt lymphoma,⁷ Wilms tumor,⁸ and IVC malformation caused by situs inversus⁹ appear in the published reports. Review of the MEDLINE database indicates that the case reported here is the first case of retroperitoneal paraganglioma presenting as isolated right-sided varicocele, as described in the published reports.

Tumors originating from extra-adrenal chromaffin cells are defined as paragangliomas and those from adrenal chromaffin cells as pheochromocytomas. Paraganglioma has an incidence of 2 to 8 per million cases per year¹⁰ and is primarily diagnosed between the third and fifth decades of life.¹¹ Most (approximately two thirds) of paragangliomas are seen in the head and neck. Approximately 75% of paragangliomas occupying the sympathetic nervous chain originate from the abdomen.¹² Paragangliomas might occur sporadically or as symptoms of several hereditary syndromes. Approximately 25% of cases of pheochromocytoma and paraganglioma are associated with classical hereditary syndromes.¹⁰ Multiple endocrine neoplasia type 2 (RET mutations), von Hippel Lindau disease (VHL mutations), hereditary paraganglioma/pheochromocytoma syndrome (succinate dehydrogenase [SDHx] mutations), and, rarely, neurofibromatosis type 1 (NF1 mutations) are some of these syndromes.¹³ Retroperitoneal paragangliomas should be diagnosed via detection of symptoms caused by hormonal activity, observation of the compression effect of the mass, or incidentally during imaging studies.

Patients with hormonally active tumors might present with headache, sweating, and hypertension associated with severe catecholamine release, symptoms that also present in pheochromocytoma. To date, no consensus regarding the histological criteria for determining malignancy in paraganglioma has been reached. Nevertheless, the most applicable criterion is believed to be metastasis. The most preferred local imaging methods for detecting and examining paraganglioma

are currently CT and MRI. MIBG scintigraphy is the preferred imaging method due to its high specificity and sensitivity for examining residual tissues and detecting metastasis. Because of its cost-effectiveness, especially in examining paragangliomas, which are related to SDHx mutations, fluorodeoxyglucose–positron emission tomography (FDG-PET) is another option for imaging.¹⁴ In some series, the 18F-DOPA PET scan was reported superior to MIBG scintigraphy.¹⁵ Urinary metanephrine and normetanephrine levels are more significant in determining hormonal activity than plasma catecholamine levels because of their high specificities.

The gold standard treatment for paraganglioma is the aggressive surgical removal of the primer mass and metastatic masses. In hormonally active tumors, the administration of preoperative alpha-blockers is mandatory for preventing intraoperative arrhythmia and hypertension. The use of this treatment option, together with embolization,¹⁷ radiotherapy,¹⁸ and chemotherapy¹⁹ as adjuvant treatment options, has resulted in an intraoperative mortality rate for paraganglioma of less than 1%.¹⁶

In conclusion, isolated right-sided varicocele is a rare pathologic condition that may be accompanied by the compression of the IVC by retroperitoneal masses. Although this pathologic condition is mostly caused by the growth of renal masses and sarcomas, other rare causes, such as paragangliomas, should be considered. While the patient described here was diagnosed with hormonally inactive paraganglioma, preoperative hormonal studies in cases of retroperitoneal masses should be considered due to the risk of intraoperative cardiac complications.

REFERENCES

1. Skoog SJ, Roberts KP, Goldstein M, Pryor JL. The adolescent varicocele: what's new with an old problem in young patients? *Pediatrics* 1997;100:112–22.
2. Rajiah P, Sinha R, Cuevas C, Dubinsky TJ, Bush WH, Jr, Kolokythas O. Imaging of uncommon retroperitoneal masses. *Radiographics*. 2011;31:949–976.
3. Niedzielski J, Paduch D, Raczynski P. Assessment of adolescent varicocele. *Pediatr Surg Int* 1997;12:410–3.
4. Meacham RB, Townsend RR, Rademacher D, et al. The incidence of varicoceles in the general population when evaluated by physical examination, gray scale sonography and color Doppler sonography. *J Urol* 1994;151:1535–8.
5. Brand TC, Morgan TO, Chatham JR, et al. Adrenal cortical carcinoma presenting as right varicocele. *J Urol* 2001;165:503.
6. Cheungpasitporn W, Horne JM, Howarth CB. Adrenocortical carcinoma presenting as varicocele and renal vein thrombosis: a case report. *J Med Case Rep* 2011;5:337.
7. Roy CR, Wilson T, Raife M, et al. Varicocele as the presenting sign of an abdominal mass. *J Urol* 1989;141:597–9.
8. Monroe K1, Navoy J, Odrezin GT, Nichols MH, Polhill R. Varicocele as a presenting feature of Wilms' tumor. *Pediatr Emerg Care*. 1995 Oct;11(5):300–1.
9. Preziosi P, Miano R, Bitelli M, et al. Right varicocele associated with inferior vena cava malformation in situs inversus: percutaneous treatment with retrograde sclerotherapy. *J Endourol* 2001;15:1001–3.
10. Stenstrom G, Svardsudd K. Pheochromocytoma in Sweden 1958–1981. An analysis of the National Cancer Registry Data. *Acta Med Scand* 1986;220:225–32.
11. Neumann HP, Bausch B, McWhinney SR, et al. Germ-line mutations in nonsyndromic pheochromocytoma. *N Engl J Med* 2002;346:1459–66.
12. Lee JA, Duh, QY. Sporadic paraganglioma. *World J Surg* 2008;32:683–7.
13. Neumann HP. Harrison's principles of internal medicine. 17th ed. New York and London: McGraw-Hill Medical; 2008.
14. Van Berkel A, Rao JU, Kusters B, et al. Correlation between in vivo 18F-FDG PET and immunohistochemical markers of glucose uptake and metabolism in pheochromocytoma and paraganglioma. *J Nucl Med* 2014;55:1253–9.
15. Hoegerle S, Nitzsche E, Althoefer C, et al. Pheochromocytomas: detection with 18F DOPA whole body PET—initial results. *Radiology* 2002;222:507–12.
16. Niemann U, Hiller W, Behrend M. 25 years' experience of the surgical treatment of pheochromocytoma. *Eur J Surg* 2002;168:716–9.
17. Carlsen CS, Godballe C, Krogdahl AS, et al. Malignant vagal paraganglioma: report of a case treated with embolization and surgery. *Auris Nasus Larynx* 2003;30:443–6.
18. Vogel J, Atanacio AS, Prodanov T, et al. External beam radiation therapy in treatment of malignant pheochromocytoma and paraganglioma. *Front Oncol* 2014;4:166.
19. Niemeijer ND, Alblas G, van Hulsteijn LT, et al. Chemotherapy with cyclophosphamide, vincristine and dacarbazine for malignant paraganglioma and pheochromocytoma: systematic review and meta-analysis. *Clin Endocrinol (Oxf)* 2014;81:642–51.