

Pediatric Mass Lesions of the Head and Neck Region and Fine-Needle Aspiration Biopsy Results

Erkan Eşki¹, Volkan Akdoğan¹, Seda Babakurban Türkoğlu¹, Muhammed Furkan Sökmen¹, Fatma Çaylaklı¹, Cem Özer¹, Emine Tuba Canpolat², İsmail Yılmaz¹

¹Department of Otorhinolaryngology, Başkent University School of Medicine, Ankara, Turkey

²Department of Pathology, Başkent University School of Medicine, Ankara, Turkey

Original Investigation

Abstract

Objective: 1. To provide a classification of pediatric mass of the head and neck region and evaluate their frequency. 2. To examine the findings of fine-needle aspiration biopsy (FNAB) in pediatric patients along with its contribution to diagnosis.

Methods: Totally, 233 pediatric patients (125 boys and 108 girls) operated at Başkent University for head and neck mass were included. Clinical, radiological, and histopathological data were retrieved from medical records.

Results: The mean age was 119±65 months, and the mean duration of follow-up was 75±49 months. Localization of the masses was as follows: 208 (89%) in the neck, 21 (9%) in the oral cavity, 2 (1%) in the neck and nasopharynx, and two (1%) in the larynx. The most common surgical procedure was open excisional biopsy (n=105, 45%) followed by cystic mass excision (n=72, 31%) and salivary gland excision (n=33, 14%). Based

on histopathological findings, benign cystic lesions were the most common disease group (n=77, 33.1%), whereas reactive lymphadenopathy was the most common condition (n=36, 15%) when a single disease was considered. Infectious/inflammatory diseases, malignancies, and benign salivary gland diseases were present in 49 (21%), 24 (10.3%), and 22 (9.4%) patients, respectively. FNAB was performed in 29.8% of the patients with an accuracy of 90.3% (95% CI, 80.1–96.4).

Conclusion: The differential diagnosis of head and neck masses during childhood includes a wide spectrum with the different conditions being benign cystic diseases of congenital origin and reactive lymphadenopathies. Owing to its high predictive value, FNAB represents a rapid and reliable method that can be commonly used in both adult and pediatric patients.

Keywords: Pediatric, neck, tumor, histopathology, fine needle aspiration biopsy

Introduction

Neck masses are common among pediatric population. The etiology is wide-spectrum. Inflammatory, congenital and neoplastic masses must be considered in differential diagnosis (1-3). Although the most common cause is conventionally accepted to be congenital lesions, some authors suggest that reactive lymphadenopathies (LAP) that develop following viral and bacterial infections are the most common cause (4, 5). The final diagnosis is established through pathological examination after excision, but fine needle aspiration biopsy (FNAB) from the mass can be performed for pre-diagnosis (6). In the studies conducted in USA over the past 20 years, it has been reported that the results of FNAB in pediatric cases are as correct as those in adult patients and FNAB protects patient from negative outcomes such as general anesthesia, pain, scar, wound infection, and delayed diagnosis (7-10).

In this study, it was aimed to classify pediatric masses of the head and neck region in general, to determine their frequency, and to compare with literature, also to examine the findings of FNAB in pediatric patients, and to reveal the contribution of FNAB to the diagnosis.

Methods

This study was approved by Başkent University Medical and Health Sciences Research Committee (Project no: KA 1/290) and supported by the Research Fund of Başkent University. Pediatric patients followed due to head-neck masses in Başkent University Ear-Nose-Throat Departments between 1998 and 2015 were evaluated retrospectively. The patients older than 204 months were excluded from the study. The location of mass, surgical procedure that was applied, the results of pathology, and the findings of FNAB and radiological examination were obtained from the medical records. Histopathological diagnoses



Address for Correspondence:

Erkan Eşki,

E-mail: eskierkan@myynet.com

Received Date: 15.12.2015

Accepted Date: 29.04.2016

© Copyright 2016 by Official Journal of the Turkish Society of Otorhinolaryngology and Head and Neck Surgery Available online at www.turkarchotorhinolaryngol.org

DOI: 10.5152/tao.2016.1371

Table 1. Classification of histopathological diagnoses and cases undergoing FNAB

Groups	Sub-groups	n (%)	Performed FNAB/Consistent with pathology (n/n) (%)*
Benign cystic diseases	Developmental cysts (congenital cysts)	77 (33.1)	9/9 (100)
	• Thyroglossal cyst (n:19)		
	• Dermoid cyst (n:9)		
	• Branchial cyst (n:3)		
	• Foregut cyst (n:1)		
	• Mature cystic keratome (n:1)		
	Epithelial cysts	33	3/3
	• Epidermal cyst (n:12)		
	• Benign epithelial cyst (n:10)		
	• Epithelial cyst (n:8)		
	• Epidermoid cyst (n:2)		
	Lymphoepithelial cysts	32	4/4
	• Lymphangioma (n:3)		
• Lymphoepithelial cyst (n:2)			
• Benign lymphoid cyst (n:1)			
Secondary or retention cysts	6	2/2	
• Retention cyst (n:3)			
• Benign mucinous cyst (n:2)			
Odontogenic cysts	5	-	
• Retention cyst (n:3)			
• Benign mucinous cyst (n:2)			
Infectious/Inflammatory	Odontogenic cysts	1	-
	Hyperplastic lymph node	49 (21)	22/18 (81.8)
	Chronic inflammation	18	11/10
	• Chronic lymphadenitis (n:9)		
	• Castleman disease (n:2)		
	• Rosai-Dorfman disease (n:2)		
	• Abortive granulomas (n:1)		
	Atypical lymphoid hyperplasia	14	4/2
	Caseating granulomatous inflammation	7	2/2
	Granulomatous inflammation	7	3/2
Lymphohistiocytic inflammation	2	2/2	
1	1	-	
Reactive LAP	36 (15.5)	8/8 (100)	
Malignancy	Malignancy	24 (10.3)	7/6 (85.7)
	Hodgkin lymphoma	8	-
	Non-Hodgkin lymphoma	4	-
	Thyroid papillary carcinoma	3	3/3
	Thyroid medullary carcinoma metastasis	2	2/2
	Rhabdomyosarcoma metastasis	2	-
	Thyroid papillary carcinoma metastasis	1	1/1
	Carcinoma metastasis	1	1/0
	Mucoepidermoid carcinoma	1	-
	Malignant mesenchymal tumor	1	-
Primitive neuroectodermal tumor (PNET)	1	-	

Table 1. Classification of histopathological diagnoses and cases undergoing FNAB (Continue)

Groups	Sub-groups	n (%)	Performed FNAB/Consistent with pathology (n/n) (%)*
Benign salivary gland diseases		22 (9.4)	9/9 (100)
	Ranula	9	-
	Pleomorphic adenoma	7	6/6
	Sialoadenitis	5	3/3
	Sialolithiasis	1	-
	Other		
		25 (10.7)	7/6 (85.7)
	Soft tissue lesions	15	4/3
	• Hemangioma (n:7)		
	• Fibromatosis (n:5)		
	• Lipoma (n:1)		
	• Schwannoma (n:1)		
	• Neurofibroma (n:1)		
	Skin-related benign lesions	5	-
	• Pre-auricular sinus (n:7)		
• Pilomatrixoma (n:2)			
• Lichenoid dermatitis (n:1)			
• Fibroepithelial polyp (n:1)			
• Papilloma (n:1)			
Thyroid-related lesions	5	3/3	
• Multinodular goiter (n:4)			
• Adenomatosis nodule (n:1)			
Total		233 (100)	62/56 (90.3)

FNAB: fine-needle aspiration biopsy; LAP: lymphadenopathy

of patients were separately evaluated by dividing into sub-age groups, which is a method that is conventionally used in the specialization areas of Pediatrics. According to this method, the sub-age group of 0-2 years was defined as infant; the sub-age group of 3-12 years was defined as child; and the sub-age group of 13-17 years was defined as adolescence.

For the statistical analysis of data, SPSS 17.0 statistical software (Version 17.0, SPSS Inc.; Chicago, IL, USA) was used. Categorical data were summarized as number and percentage. Continuous variables were presented as mean and standard deviation (as median and minimum-maximum when needed). By considering the results of pathology as the golden standard, the superiority of the results of FNAB was evaluated by calculating sensitivity, positive predictive value, and accuracy.

Results

A total of 233 pediatric patients (125 boys and 108 girls) operated for head and neck mass were included in the study. The ages of patients at the time of surgery were between 1 month and 204 months (mean=119±65 months) and the mean duration of follow-up was 75±49 months (1-192 months).

The mass location was in the neck in 208 patients (89%), in the oral cavity in 21 patients (9%), and in both the neck and nasopharynx in 2 patients (1%), and in the larynx in 2 patients (1%).

Neck biopsy expressed open excisional biopsy process and it was the surgical procedure that was applied mostly [in 105 cases (45%)]. It was followed by the excision of cystic mass in 72 cases (31%) and the excision of the salivary gland in 33 cases (14%) (Figure 1).

Considering the histopathological diagnoses separately, the most common was reactive lymphadenopathy at the rate of 15% (n=36). With regard to the groups, the most common diagnosis was benign cystic diseases, most of which were congenital masses (n=77, 33.1%). Of the patients, 49 (21%) were diagnosed with infectious/inflammatory disease, 24 (10.3%) were diagnosed with malignancy, and 22 (9.4%) were diagnosed with benign salivary gland disease (Figure 2). All histopathological diagnoses and patients undergoing FNAB are given in Table 1.

Histopathological diagnoses of patients according to the sub-age groups (infant: 0-2 years; child: 3-12 years; adolescence: 13-17 years) are presented in Table 2. It was noted that benign

Table 2. Distribution of histopathological diagnoses according to age groups

Age groups	Pathology						Total
	Benign cystic diseases	Infectious/Inflammatory	Reactive LAP	Malignancy	Benign salivary gland diseases	Other	
Infant (0-24 months)	8	2	6	3	1	3	23
Child (24-156 months)	37	28	21	5	10	21	122
Adolescent (156-216 months)	32	19	9	16	11	1	88
Total	77	49	36	24	22	25	233

LAP: lymphadenopathy

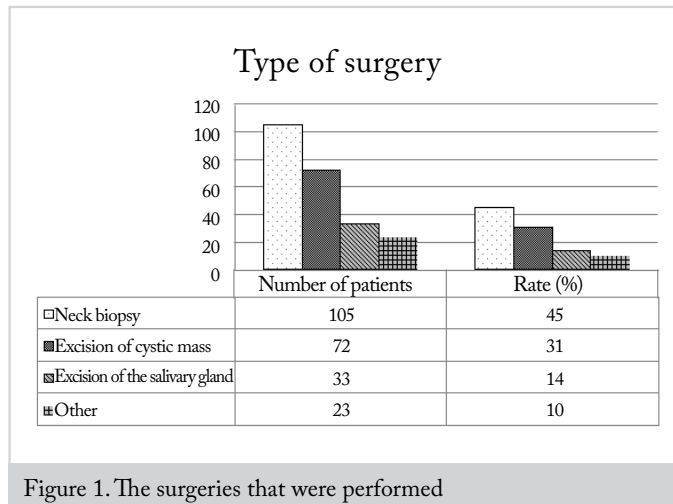


Figure 1. The surgeries that were performed

cystic diseases were mostly seen in all age groups; 58% of reactive LAPs were in the subgroup of child; malignancies were more common among adolescences, and infectious/inflammatory diseases were observed mostly in the sub-group of children (Table 2).

Of the patients with neck mass (n=208), 62 (29.8%) underwent FNAB. 56 of FNAB processes matched with the result of histopathologic examination. Accordingly, the rate of accuracy was found to be 90.3% [sensitivity 100% (CI 93.6%-100%) – positive predictive value 90.3% (CI 80.1%-96.4%)]. According to histopathological sub-groups, the accuracy of FNAB was the highest in the groups of benign cystic disease, reactive LAP and benign salivary gland disease with the rate of 100% and the lowest in the group of infectious /inflammatory disease group with the rate of 81.8% (Table 1). The rates of FNAB application were 11.7%, 44.9%, 22.2%, 29.2%, 40.9%, and 28% in benign cystic diseases, infectious/inflammatory diseases, reactive LAP, malignancy, benign salivary gland diseases, and other group, respectively.

In 264 radiological examinations, the most commonly used was ultrasonography (USG) at the rate of 58% (n=154). It was followed by computed tomography (CT) (18%, n=47) and magnetic resonance imaging (MRI) (14%, n=37).

Discussion

The differential diagnosis of pediatric masses of the head and neck region is quite wide. Medical history, physical examina-

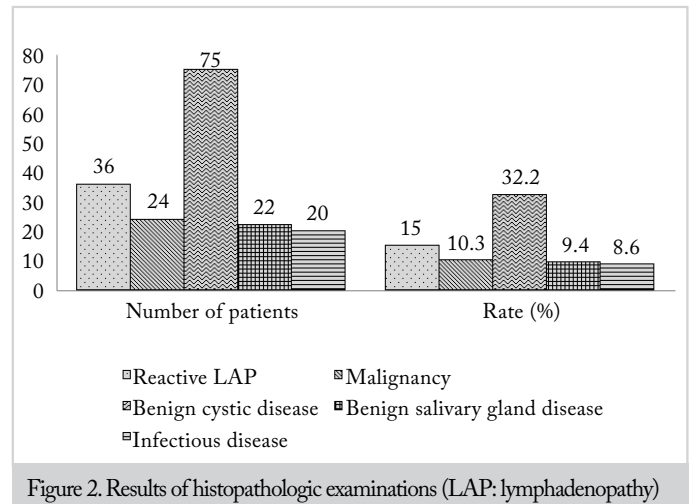


Figure 2. Results of histopathologic examinations (LAP: lymphadenopathy)

tion findings, and imaging techniques are highly important in the diagnosis of congenital, inflammatory and tumoral causes. The mostly preferred imaging technique after physical examination of patients is USG because it is inexpensive, easily accessible, and harmless and it provides rapid differentiation of solid-cystic masses (11). Also in our study, the most commonly used technique was found to be USG at the rate of 58%. Particularly for branchial, thyroglossal, and dermoid congenital cystic masses of the neck, USG does not require histopathological evaluation and it is diagnostic at a high rate of accuracy. On the other hand, CT is not preferred as the first choice because of ionized radiation. However, CT and MRI can be used for the masses that have deeper localization and the character of which cannot be defined through USG (12). In our study, while the usage rate of CT was detected to be 18%, MRI was used in 14% of cases. Although radiological examinations are important for the establishment of diagnosis, histopathological evaluation must definitely be performed in order to make the final diagnosis.

In the approach to pediatric head-neck masses, FNAB must be performed after radiological examinations, especially in lateral neck masses. Fine-needle aspiration biopsy can reduce the number of surgical interventions planned to be performed for diagnostic purpose owing to its high predictive value. In this way, children are kept away from negative outcomes such as general anesthesia, wound infection, pain, scar and delayed diagnosis (7-10). D'anza et al. (13) reported the sensitivity

of FNAB as 87.5% and the specificity as 100% for revealing malignancy of pediatric neck masses. In our study, 62 patients with neck masses (29.8%) underwent FNAB and the match rate of FNAB result to histopathological diagnosis was generally 90.3% and 85.7% in malignant masses. In the study with the widest series in literature, FNAB sensitivity was detected to be 97.1% and sensitivity was 93.2% (13). In the study of Dilber et al. (14) with 17 pediatric and 110 adult patients, the accuracy of FNAB in all age groups was reported to be 94.3% for congenital-developmental pathologies, 89.4% for infectious-inflammatory pathologies (93.5% for specific infections), and 83.7% for neoplastic pathologies (85.9% for malignant neoplasms). They reported no statistically significant difference between the accuracy of FNAB and age group. Despite that, due to the establishment of clinical diagnosis through medical history, physical examination and radiological examinations in many cases and FNAB's requiring pediatric cytopathologist and sometimes general anesthesia reduce the rates of FNAB in pediatric neck masses.

The most common cause of pediatric neck masses is known to be congenital lesions in general (4). However, some changes can be observed in the distribution depending to the socio-economic status (15). According to Meier and Grimmer (5) and D'anza (13), the most common pathology is reactive lymphadenopathy following upper respiratory tract infection. On the other hand, the most common cause is the inflammatory group according to Al-Mayoof (15) (57%) and it is attributed to the socio-economic situation of the country where the study was conducted. In our study, general congenital lesions were more common and the most frequent disease was reactive LAP at the rate of 15% when the diseases were considered one by one. Total rate of reactive LAP and infectious/inflammatory groups was found to be 36% in our study and the result was consistent with the socio-economic situation of our country.

In pediatric population, the rate of malignant neck mass is between 11% and 15% (16). Malignancy was detected in 10% of our cases. The most common malignancy was Hodgkin lymphoma (8/24=33.3%). Although most of patients were benign, the suspect of malignancy increases when the mass grows rapidly, exists for a long time, and occurs especially in supraclavicular and posterior-cervical regions (4).

Fine-needle aspiration biopsy is a minimal invasive method used for the diagnosis of neoplastic and non-neoplastic lesions in the head and neck region. The procedure is generally without complication and it is safe, and well-tolerable by patients. It usually does not require anesthesia and the results are obtained rapidly. It serves as a complementary diagnostic method for histopathological examination. It is important that it allows the identification of benign reactive LAP, which is common in childhood, without any need for open biopsy (17). In this study, cytological and histological findings were consistent and the rate of accuracy was quite high. Therefore, it has been concluded that FNAB is an effective diagnostic method in the diagnosis and treatment of pediatric head-neck masses.

Conclusion

As a result, the etiology of pediatric head-neck masses is highly wide-spectrum. The rates of different pathologies in our study were found to be consistent with literature. Moreover, FNAB can be used in pediatric cases with head-neck mass because it can decrease the number of surgical interventions planned to be performed for diagnosis owing to its high predictive value in the establishment of diagnosis. These results display the importance of cytopathological examination for making the final diagnosis, as well as medical history, physical examination and imaging techniques.

Ethics Committee Approval: Ethics committee approval was received for this study from the ethics committee of Başkent University.

Informed Consent: Informed consent was not obtained from patients due to the retrospective design of the study.

Peer-review: Externally peer-reviewed.

Author Contributions: Concept - İ.Y.; Design - İ.Y., M.F.S.; Supervision - İ.Y.; Resources - E.E.; Materials - M.F.S., E.E., V.A., S.B., C.Ö., F.Ç., E.T.C.; Data Collection and/or Processing - E.E., V.A., S.B., C.Ö., F.Ç., E.T.C.; Analysis and/or Interpretation - İ.Y.; Literature Search - M.F.S., E.E.; Writing Manuscript - M.F.S., E.E.; Critical Review - İ.Y.

Conflict of Interest: No conflict of interest was declared by the authors.

Financial Disclosure: This study has received of financial support by Başkent University research fund.

References

- Dickson PV, Davidoff AM. Malignant neoplasms of the head and neck. *Semin Pediatr Surg* 2006; 15: 92-8. [\[CrossRef\]](#)
- Turkington JR, Paterson A, Sweeney LE, Thornbury GD. Neck masses in children. *Br J Radiol* 2005; 78: 75-85. [\[CrossRef\]](#)
- Tracy TF Jr, Muratore CS. Management of common head and neck masses. *Semin Pediatr Surg* 2007; 16: 3-13. [\[CrossRef\]](#)
- Karaca İ. Çocuklarda baş boyun patolojileri. *Turk Ped Ars* 2010; 45: 20-2. [\[CrossRef\]](#)
- Meier JD, Grimmer JF. Evaluation and management of neck masses in children. *Am Fam Physician* 2014; 89: 353-8.
- Niedzińska G, Kotowski M, Niedziński A, Dybiec E, Wiczorek P. Cervical lymphadenopathy in children – incidence and diagnostic management. *Int J Pediatr Otorhinolaryngol* 2007; 71: 51-6. [\[CrossRef\]](#)
- Mobley DL, Wakely PE, Frable MS. Fine-needle aspiration biopsy: application to pediatric head and neck masses. *Laryngoscope* 1991; 101: 469-72. [\[CrossRef\]](#)
- Cohen MB, Bottles K, Ablin AR, Miller TR. The use of fine needle aspiration biopsy in children. *Western J. Med.* 1989; 150: 665-7.
- Derias NW, Chong WH, O'Conner AF. Fine needle aspiration cytology of a head and neck swelling in a child: a non-invasive approach to diagnosis. *J Laryngol Otol* 1992; 106: 755-7. [\[CrossRef\]](#)
- Liu E, Bernstein J, Sculateri N, Wu H. Fine needle aspiration biopsy of pediatric head and neck masses. *Int J Pediatr Otorhinolaryngol* 2001; 60: 135-40. [\[CrossRef\]](#)

11. Rooks VJ, Cable BB. Head and neck ultrasound in the pediatric population. *Otolaryngol Clin N Am* 2010; 43: 1255-66. [\[CrossRef\]](#)
12. Shekdar KV, Mirsky DM, Kazahaya K, Bilaniuk LT. Magnetic resonance imaging of the pediatric neck: an overview. *Magn Resonance Imaging Clin N Am* 2012; 20: 573-603. [\[CrossRef\]](#)
13. D'anza B, Kraseman SJ, Helwig CC, Grene JS, Wood WE. FNA biopsy of pediatric cervicofacial masses and validation of clinical characteristics of malignancy. *Int J Pediatr Otorhinolaryngol* 2015;79: 1196-200. [\[CrossRef\]](#)
14. Dilber M, Erişen L, Yerci Ö, Coşkun H, Basut O, Onart S, et al. Tiroid dışı baş-boyun kitlelerinde ince iğne aspirasyon sitolojisi sonuçlarımız: Uludağ deneyimi. *Turk Otorhinolaryngol Arch* 2005; 45: 86-93.
15. Al-Mayoof AF. Neck masses in paediatric population: An experience with children attended the Central Teaching Hospital of Pediatrics in Baghdad 2008-2009. *African J Paediatr Surg* 2015; 12: 136-9. [\[CrossRef\]](#)
16. Rosenberg HK. Sonography of pediatric neck masses. *Ultrasound Q* 2009; 25: 111-27. [\[CrossRef\]](#)
17. Anne S, Teot LA, Mandell DL. Fine needle aspiration biopsy: Role in diagnosis of pediatric head and neck masses. *Int J Pediatr Otorhinolaryngol* 2008;72: 1547-53. [\[CrossRef\]](#)