



## Tips and Tricks in Laparoscopic Surgery in Light of 172 Patients, From A Gynecological Point of View in Turkey

### 172 Hastalık Seride Jinekolojik Bakış Açısından Laparoskopik Cerrahide İncelikler ve İpuçları

Tricks and Safety in Laparoscopy

Kadir Bakay<sup>1</sup>, Fatih Aytekin<sup>1</sup>, Ahmet Tunckiran<sup>2</sup>

<sup>1</sup>Kadın Hastalıkları ve Doğum Kliniği, <sup>2</sup>Üroloji Kliniği, Baskent Üniversitesi Alanya Uygulama Merkezi, Alanya, Antalya, Türkiye

#### Özet

**Giriş:** Bu çalışmada laparoskopik cerrahide edindiğimiz tecrübeleri paylaşmayı amaçladık. **Gereç ve Yöntem:** Prospektif vaka kontrollü çalışmada Başkent Üniversitesi Alanya Uygulama Merkezi Kadın Hastalıkları ve Doğum kliniğindeki Nisan 2012 ve Mart 2014 tarihleri arasında opere edilen 172 hastadan elde edilen veriler kullanıldı. **Bulgular:** Batın duvarı elle tutulduğunda veya çamaşır klempile tutulduğunda trokar girişi sırasında uygulanan güce bağlı değişiklik; elle tutulduğunda 1cm'den 3cm'ye (ortalama: 2.13±1cm), çamaşır klempile tutulduğunda 0.5cm'den 3cm'ye (ortalama: 0.89±0.8cm) kadar ölçülmüş ve aradaki fark istatistiksel olarak anlamlı bulunmuştur (p<0.05). **Tartışma:** Laparoskopik cerrahi veya genel anlamda minimal invaziv cerrahi, gelecekte tıbbın neredeyse tüm alanlarına hakim olacaktır. Bu nedenle tüm cerrahi branşların hem mezuniyet öncesi hem de mezuniyet sonrası cerraha yeterli eğitimi sunması elzemdir.

#### Anahtar Kelimeler

Laparoskopi; Laparoskopik Dikiş; Güvenli Giriş

#### Abstract

**Aim:** In this prospective study we aim to discuss and share our experience of what we have learned in laparoscopic surgery in general. **Material and Method:** Prospective case controlled study. Data obtained from 172 laparoscopic procedures performed in Baskent University Alanya hospital gynecology clinic were collected between April 2012 and March 2014. **Results:** Difference in abdominal wall elevation measurements with force applied during primary trocar entry ranged from 1 cm to 3 cm (mean: 2.13±1 cm) when elevated manually and 0.5 cm to 3 cm (mean: 0.89±0.8 cm) with the towel clips. The difference was statistically significant (p<0.05). **Discussion:** Laparoscopic surgery or minimally invasive surgery in general will undoubtedly dominate all fields of medicine in the near future, therefore it would be mandatory for almost every surgical branch to provide adequate training and skills for the operator in the both pre and post graduation period.

#### Keywords

Laparoscopy; Laparoscopic Suturing; Safe Entry

DOI: 10.4328/JCAM.2754

Received: 25.08.2014 Accepted: 13.09.2014 Printed: 01.05.2016 J Clin Anal Med 2016;7(3): 321-6

Corresponding Author: Kadir Bakay, Baskent Üniversitesi Kadın Hastalıkları ve Doğum Kliniği, Alanya Uygulama Merkezi, Alanya, Antalya, Türkiye.

GSM: +905308265868 E-Mail: drkadirbakay@gmail.com

## Introduction

Laparoscopic surgery, when practically compared with laparotomy, is more favorable in terms of hospital stay, pain management, recovery and post operational scar formation [1]. Although relatively safe, a steep learning curve that is mainly centered on skill, need for advanced equipment and serious complications concerning intestinal, vesical and vascular damage has somehow limited its use in our country.

In Turkey, learning and performing advanced laparoscopic procedures in gynecology can best be described as early in development. Although certain renown centers are performing various operations with success, a newly graduated gynecologist usually does not possess the necessary skills and experience required to be sufficient, either due to lack of training because of the absence of experienced instructors or the lack of available equipment which in turn often leads to a vicious cycle. In the end, fear of complications and a low self esteem solidify as an immobile obstacle for most gynecologists, that might otherwise have become skilled endoscopic surgeons under different circumstances.

Complications, as in any other surgical method, are inevitable in laparoscopic surgery as well but the priority must always be in early awareness and the ability to address it fast and effectively, and when such a complication is identified, factors like the experience of the team, availability of required equipment, patient hemodynamics and any other accompanying medical conditions should always be handled professionally.

It is also wise to remark that, in terms of patient safety and health, a decision to revert to conventional surgery to better interfere a problem should always be considered a well made decision rather than facing undesired consequences later.

The main challenge a surgeon will face when dealing with endoscopic surgery is the adaptation of a 2 dimensional virtual image into a 3 dimensional reality without the familiar finger-touch effect through an angle of anatomy that she/he is generally not accustomed to. This obstacle though, can be overcome with skill and constant training along with experience.

Severe complications in laparoscopy are usually encountered during initial abdominal entry, currently there are a number of techniques described in order to minimize entry-related injuries including the Veress-pneumoperitoneum-trocar, "classic" or closed entry [2] the open (Hasson) technique [3] direct trocar insertion without pneumoperitoneum [4] use of shielded disposable trocars [5,6] optical Veress needle [7,8] optical trocars, [9,10] radially expanding trocars [11,12] and a trocarless reusable, visual access cannula [13,14], yet none of them are proven to be safer than the other.

Abdominal wall elevation by hand or using towel clips during Veress needle entry or primary trocar insertion is considered to be an effective safety measure by many surgeons [15,16]. In a study using a suprapubic port for measurement to compare the efficacy of manual abdominal wall elevation below the umbilicus and of towel clips placed within and 2 cm from the umbilicus it was reported that only towel clips proved a significant peritoneal elevation during primary trocar insertion [16].

Even after an ideal operating field is established an endoscopic surgeon has various other challenges to overcome, especially in advanced procedures, including but not limited to; avoiding

bladder and ureter injury, avoiding bowel injury and proper suturing and knot tying, the latter which can be stressful at times. In this prospective study we aim to discuss and share our experience of what we have learned in laparoscopic surgery over the years, hoping that it would provide useful insight and shed more light over crucial aspects such as the ideal angle of operative ports, safer abdominal entry, intracorporeal suturing and knot-tying techniques to make it become better understood and performed by presenting simple tricks and videos from a gynecologist's point of view.

## Material and Method

All authors listed state that the protocol for the research project has been approved by a suitably constituted Ethics Committee of the institution within which the work was undertaken. All patients were required to fill and sign a specific informed consent form detailing the procedure.

As a first note, we put no limitations while deciding on laparoscopic surgery to patients according to their body mass index; number of previous surgeries, approximate weight of the uterus, age or any other accompanying disease that they might have and all operations were carried out using two operative trocars with the extra supra-pubic trocar being used only for taking measurements during initial entry.

To obtain objective measurements during abdominal entry the suprapubic port was used to visualize and take the measurements and a trocar (Figure 1) was used as a ruler.



Figure 1. (instruments used to take the measurements)

First, elevation distance between the intestines and abdominal wall was measured by inserting the ruler trocar through the umbilical port to the point where it touched the intestinal surface by visualizing via the suprapubic port with a 5mm optical trocar after PP was established for both methods.

Abdominal wall thickness was measured the same way by visualizing the umbilical ruler trocar via the suprapubic port.

After these measurements were obtained, PP was released and the abdominal wall was elevated with both the towel clips and by using hands. The distance between intestines and abdominal wall was measured for both methods, again using the same technique and to calculate the difference in abdominal wall when force applied, we used this formula for each individual

patient:

(Distance between intestines and abdominal wall with PP) - (wall thickness + distance between intestines and abdominal wall with no PP). All of these measurements were taken for both towel clips and hands usage and then compared statistically.

Operative trocars were placed with an estimated angle of 40-50 degrees with respect to the central line passing through the umbilicus and distanced approximately 15 cm to the central line and approximately 24 cm apart from each other, forming two identical 3-4-5 triangles (Figure 2).

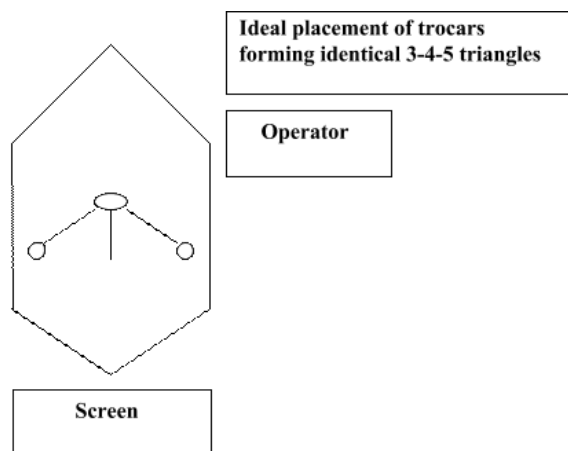


Figure 2. (port positions)

Our study group is comprised of 172 patients that had underwent laparoscopic surgery in our clinic for various benign gynecological diseases with procedures ranging from a simple cystectomy to myomectomy and total laparoscopic hysterectomy (TLH), between April 2012 and March 2014.

Patients that had underwent hysterectomy were also subgrouped according to; age, body mass index (BMI), parity, indications for surgery, duration of operation, intra-operative complications, uterine weight, blood loss, decide on laparotomy and post-operative complications (Table 2,3).

Duration of operation in TLH was defined as the time from the placement of operative trocars to the successful closure of the vaginal cuff.

Intra-operative complications were defined as; major vascular injury, bladder injury and bowel injury.

Post-operative complications were defined as; vaginal cuff dehiscence, pelvic abscess and ileus.

Blood loss was measured by estimating the total amount of fluid aspirated during the operation.

Abdominal wall elevation distance, in centimeters using the trocar as a reference, with both the towel clips and hands only method were recorded both before and after establishing pneumoperitoneum (PP) along with wall elevation change with force applied during primary trocar entry.

Mann-Whitney U test was used to evaluate the data obtained in the study. Results were evaluated in a 95% safety zone and a probability (P) value lower than 0.05 was considered to be statistically significant.

## Results

Abdominal wall elevation distance before establishing pneu-

moperitoneum, in centimeters using the trocar as a reference, ranged from 2 cm to 7 cm (mean:  $4.15 \pm 2$  cm) when elevated manually and 4 cm to 14 cm (mean:  $8.34 \pm 4$  cm) with the towel clips.

The Z-Score is -3.38. The p-value is 0.001. The U-value is 6.5.

The critical value of U at  $p \leq 0.05$  is 26 therefore the difference was statistically significant ( $p < 0.05$ ) (Table 1).

Table 1. (Mann Whitney U test comparing data between two groups)

(n=172)	Manual	Towel Clips	P
Abdominal wall elevation before PP (cm)	$4.15 \pm 2$	$8.34 \pm 4$	.001**
Abdominal wall elevation after PP (cm)	$9.18 \pm 4$	$11.81 \pm 3$	.103
Abdominal wall thickness (cm)	2.28	2.28	
Elevation change with force (cm)	$2.13 \pm 1$	$0.89 \pm 0.8$	.001**

Mann WhitneyU test \*\*  $p < 0.05$

Abdominal wall thickness measurements ranged from 1 cm to 5 cm (mean:  $2.28 \pm 2$  cm).

Abdominal wall elevation distance after establishing pneumoperitoneum, in centimeters using the trocar as a reference, ranged from 6 cm to 16 cm (mean:  $9.18 \pm 4$  cm) when elevated manually and 9 cm to 14 cm (mean:  $11.81 \pm 3$  cm) with the towel clips.

The Z-Score is 1.62. The p-value is 0.103. The U-value is 16.

The critical value of U at  $p \leq 0.05$  is 13 therefore the difference was not found to be statistically significant (Table 1).

Difference in abdominal wall elevation measurements with force applied during primary trocar entry ranged from 1 cm to 3 cm (mean:  $2.13 \pm 1$  cm) when elevated manually and 0.5 cm to 3 cm (mean:  $0.89 \pm 0.8$  cm) with the towel clips.

The Z-Score is 3.39. The p-value is 0.001. The U-value is 68.5.

The critical value of U at  $p \leq 0.05$  is 119 therefore the difference was statistically significant ( $p < 0.05$ ) (Table1).

Largest uterus in the TLH series was 1550 grams (Figure 3,4).

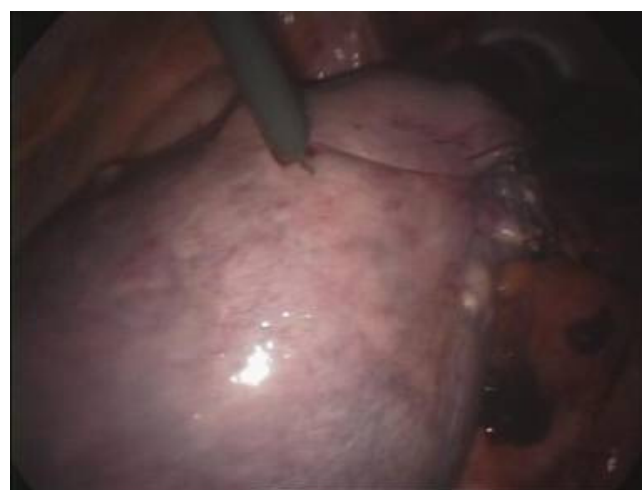

Figure 3. (giant uterus)

Largest myoma removed was 16x9x7 cm.

Shortest operation time recorded for TLH was 48 minutes.

Largest blood loss in the TLH series was 750 ml due to severe pelvic adhesions (Figure 5,6).

One case in the TLH series had a large 12x10x10 cm torsioned dermoid cyst (Figure 7).

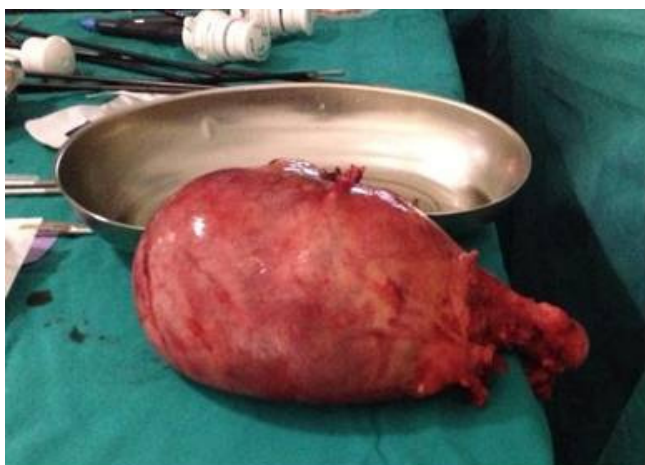

Figure 4. (giant uterus)

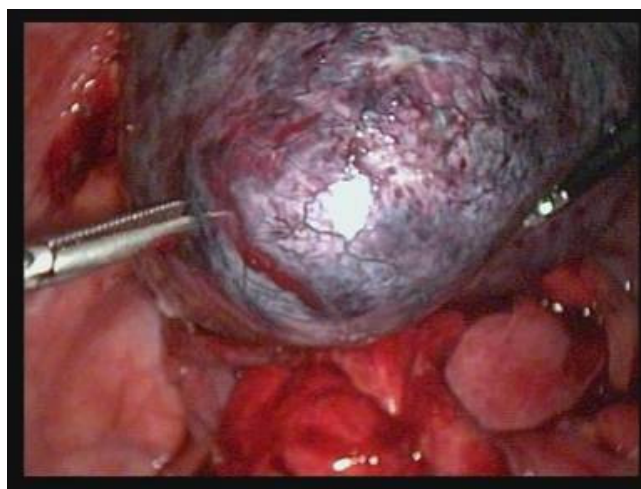

Figure 7. (torsioned dermoid cyst in hysterectomy)

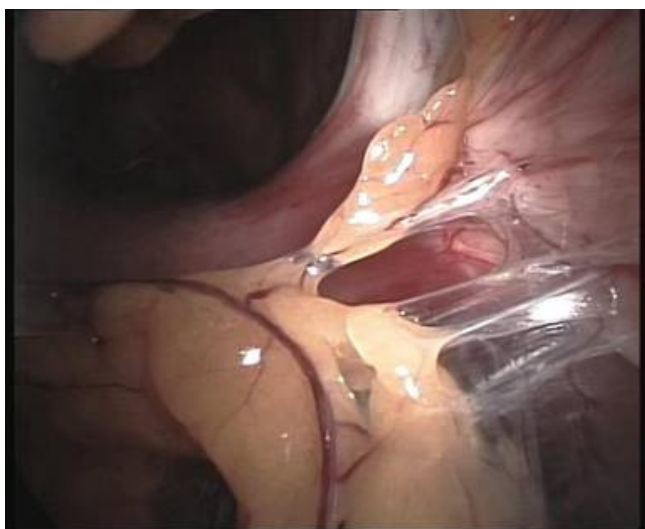

Figure 5. (pelvic adhesions)

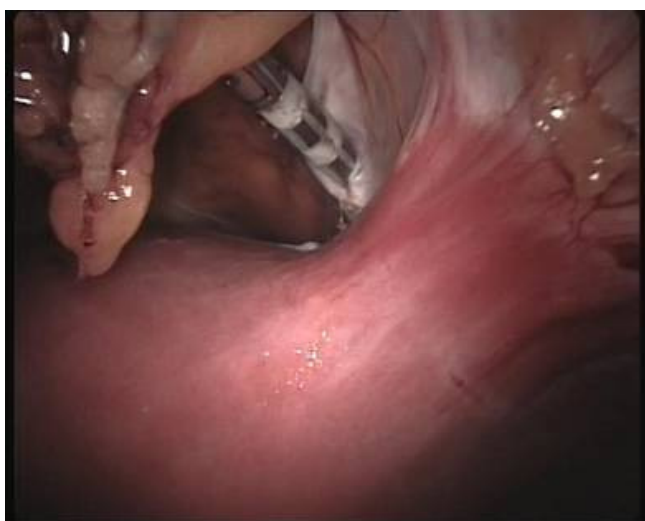

Figure 6. (pelvic adhesions)

In two cases during TLH, a decision to convert to laparotomy was made due to inadequate exposure caused by the location of a single giant myoma blocking the view required for vesico-uterine peritoneal dividing. There were 2 intra-operative complications in the TLH series, bladder damage during vesicouterine peritoneal dividing was

identified and the damage was repaired with intracorporeal suturing using 3/0 polyglactin 210 (Vicryl) and tested by bladder filling for any possible leakage. Foley catheterization remained for 7 days in both patients. One recovered with no fistula formation, one patient on the other hand presented with vesicovaginal fistula 36 days after the operation and was re-operated with laparotomy. All patients were discharged at day 1 after the operation and recalled at day 7 and day 30 during follow-up. One patient had pelvic abscess on post-op day 8 which resolved by antibiotherapy. One patient had post-operative ileus which resolved by palliative treatment (Table 2,3).

Table 2. (Patient data of TLH operations)

(n=51)	Mean
Age (years)	49.15±5.2
BMI (kg/m <sup>2</sup> )	30.15±9.3
Parity	3.5±1.1
Indications	n
1: Myoma Uteri	29
2: Endometrial Polyp	3
3: Endometrial Hyperplasia	8
4: Post-menopausal bleeding	4
5: Adnexial Mass	7

Table 3. (TLH operation related data)

(n=51)	Mean
Duration of operation (minutes)	69.25±22.21
Blood loss (ml)	320±190
Weight of uterus (g)	355.25±230.1
Intra-op complications	n
Vascular injury	0
Bladder injury	2 (3.9%)
Bowel injury	0
Laparotomy	2 (3.9%)
Post-op complications	n
Cuff dehiscence	0
Pelvic abscess	1 (1.96%)
Ileus	1 (1.96%)



## Discussion

Despite the technique's difficulties, minimally invasive surgery in general has gained an increasing popularity and acceptance as the modern method of surgery in the last decade and will likely to gain much more widespread support in the following years as shown by the recent introduction of robotic surgery.

Over the years there are certain fine points we have managed to learn, debate, test and apply repeatedly, based on experience gained in our clinical practice that we would like to share and discuss to better perform an effective surgery.

First of all, primarily for advanced operations, the patient should in preference be prepared in a supine position with arms attached to the hips, meaning, arms not spread in the conventional "T" formation which hinders operator movement.

Most gynecological procedures can be performed with 2 operative trocars providing they are aligned properly. We have found that the ideal placement needed for advanced surgery is to form 2 identical 3-4-5 triangles, as described in the methods section, which is adequately distanced to enable freedom of movement without swording and yet close enough for suturing and knot tying.

One of the serious complications an endoscopic surgeon might face is bladder injury during laparoscopic hysterectomy and as mentioned before the most important aspect is early awareness of the defect, rather during the operation. As a very useful remark concerning this, it is always wise to check on the foley on a regular basis since any kind of bladder injury will tend to inflate the reservoir bag like a balloon, due to constant high intra-abdominal carbon dioxide pressure.

We have encountered 2 cases of bladder injuries in the TLH series which is slightly higher (3.9%) than the current literature [17]. Being the only reference center performing laparoscopic surgery in our region might explain that.

We have also observed that while dividing the vesicouterine peritoneum to form the peritoneal fold in TLH, a slight irrigation with Ringer Lactate significantly eases the dissection, very helpful especially if adhesions are present due to previous surgeries.

If the surgeon is able and experienced in laparoscopic suturing and knot tying, most bladder injuries can be repaired without converting to laparotomy but it is important to mention that any other accompanying medical conditions, namely diabetes mellitus, should also be taken in full consideration as in all post operative wound healing process' in general.

Our patient that presented with vesico-vaginal fistula after 36 days had unregulated diabetes and was persistently resisting medical treatment for it.

It is clear that introduction of robotic surgery dramatically reduced the steep learning curve demanded for laparoscopic suturing by enabling angled unhindered wrist movements [18]. But it is also clear that the system will not be widely available anytime soon due to high financial costs for both initial purchase and regular upkeep and in that regard laparoscopic suturing and knot tying is still an essential skill that needs to be acquired by an endoscopic surgeon.

For quite some time we had to use micro needle holders for suturing that were withered with age and not firm enough to handle the necessary stability required to pass a curved needle

for vaginal cuff suturing but we have observed that straightening the needle is a satisfactory alternate option and it helped us realize that it is actually a better and easier way to train in intracorporeal knot tying for reasons discussed below.

Though for definitive suturing, the curved needle must be the next step.

The key point of intracorporeal knot tying is to provide a stable rotational movement centered on the neck of the off-hand assistant needle holder, with slightly open jaws (optional), and the pivoting needle around it that is held by the tip, preferably perpendicular to the shaft (Video 1). We have found this method to be especially comfortable with straight needles due to natural geometry in establishing perpendicular alignment of the straight needle and the needle holder.

As being a detail usually dismissed in the heat of surgery, we have also decided worthy of mention that if the surgeon's height is approximately between 165 cm and 180 cm, stepping on a 10 cm platform, in particular during suturing and knot tying, corrects the wrist angle thus enabling more range for the rotational wrist movements required for the procedure.

As noted before the main risk in laparoscopy is in the initial phase where the abdominal wall is passed to create pneumoperitoneum or likewise in primary trocar entry. Ponsky JL reported on one of the first laparoscopic cholecystectomies that; subcutaneous emphysema, gastrointestinal perforations, solid organ and visceral injuries along with abdominal wall bleeding can be seen as complications associated with abdominal entry and establishing pneumoperitoneum [19].

Just as Nezhad FR et al. mentioned before [15] we also regard abdominal wall elevation during Veress needle or primary trocar entry, be it with towel clips or manual, to be an important safety measure.

Aside from that we peculiarly aimed to put emphasis on the method used for abdominal wall elevation. Roy GM et al. reported that elevating the abdominal wall using towel clips provides the greatest distance between parietal peritoneum and the underlying viscera, thus enabling the maximum margin of safety during entry [16]. Our results were in similar range with this study.

Hill and Maher on the other hand reported 26 (4.8%) omental perforations during 542 direct trocar insertions for laparoscopic access by manual elevation instead of towel clips [20].

There were no entry related complications in our study group.

We also deemed of importance to mention that the difference in abdominal wall elevation measurements with force applied during primary trocar entry when compared between using towel clips and manual elevation is statistically lower in the towel clips group pointing out to the fact that elevating the abdominal wall with towel clips provides a more stable platform during primary trocar entry, even when a sizeable amount of force is required.

Serious complications in laparoscopic surgery, albeit rare, are mainly encountered during the initial phase of the operation where the surgeon attempts to pass the abdominal wall, in order to insert necessary surgical equipment from a small incision, without damaging major vascular structures and organs.

Many authors consider abdominal elevation to be a safer approach during entry and in our study we have observed abdominal wall elevation using towel clips to be the safer method when

compared with manual elevation.

### Conclusions

Laparoscopic surgery or minimally invasive surgery in general will undoubtedly dominate all fields of medicine in the near future, therefore it would be inevitably mandatory for almost every surgical branch to provide adequate training and skills for the operator in the both pre and post graduation period.

With all that is said and done in that regard, we aimed to share and provide both statistical evidence based data and other useful tips and tricks that cannot be statistically measured but derived from our own surgical experience, humbly hoping it will be beneficial.

### Competing interests

The authors declare that they have no competing interests.

### References

1. Chapron C, Fauconnier A, Goffinet F, Dubuisson JB. Laparoscopic surgery is not inherently dangerous for patients presenting with benign gynecological pathology. Results of meta-analysis. *Hum Reprod* 2002;17:1334-42.
2. Palmer R. Safety in laparoscopy. *J Reprod Med* 1974;13:1-5.
3. Hasson HM. A modified instrument and method for laparoscopy. *Am J Obstet Gynecol* 1971;110:886-7.
4. Dingfelder JR. Direct laparoscopic trocar insertion without prior pneumoperitoneum. *J Reprod Med* 1978;21:45-7.
5. Byron JW, Fujiyoshi CA, Miyazawa K. Evaluation of the direct trocar insertion technique at laparoscopy. *Obstet Gynecol* 1989;74(3-1):423-5.
6. Lanvin D, Elhage A, Querleu D. Does the use of pneumoperitoneum and disposable trocars prevent bowel injury at laparoscopy? A randomized experimental study in the rabbit. *Gynaecol Endosc* 1996;5:343-8.
7. Riek S, Bachmann KH, Gaiselmann T, Hoernstein F, Marzusch K. A new insufflation needle with a special optical system for use in laparoscopic procedures. *Obstet Gynecol* 1994;84:476-8.
8. McGurgan P, O'Donovan P. Optical Veress as an entry technique. *Gynaecol Endosc* 1999;8:379-92.
9. Kaali SG. Introduction of the Opti-Trocar. *J Am Assoc Gynecol* 1993;1(1):50-3.
10. Mettler L, Schmidt EH, Frank V, Semm K. Optical trocar systems: Laparoscopic entry and its complications. *Gynaecol Endosc* 1999;8:383-9.
11. Turner DJ. A new radially expanding access system for laparoscopic procedures versus conventional cannulas. *J Am Assoc Gynecol Laparosc* 1996;34:609-15.
12. Turner DJ. Making the case for the radially expanding access system. *Gynaecol Endosc* 1999;8:391-5.
13. Vilos GA, Ternamian A, Dempster J, Laberge PY. Laparoscopic entry: a review of techniques, technologies, and complications. *J Obstet Gynaecol Can* 2007;29(5):433-65.
14. Schoonderwoerd L, Swank DJ. The role of optical access trocars in laparoscopic surgery. *Surg Technol Int* 2005;14:61-7.
15. Nezhat FR, Silfen SL, Evans D, Nezhat C. Comparison of direct insertion of disposable and standard reusable laparoscopic trocars and previous pneumoperitoneum with Veress needle. *Obstet Gynecol* 1991;78(1):148-50.
16. Roy GM, Bazzurini L, Solima E, Luciano AA. Safe technique for laparoscopic entry into the abdominal cavity. *J Am Assoc Gynecol Laparosc* 2001;8(4):519-28.
17. Sendag F, Akman L, Oztekin K. Intraoperative management and urinary system complications during total laparoscopic hysterectomy. *J Turk Soc Obstet Gynecol* 2013; 10(1):26-30.
18. Yohannes P, Rotariu P, Pinto P, Smith AD, Lee BR. Comparison of robotic versus laparoscopic skills: is there a difference in the learning curve? *Urology* 2012;60(1):39-45.
19. Ponsky JL. Complications of laparoscopic cholecystectomy. *Am J Surg* 1991;161:393-5.
20. Hill DJ, Maher PJ. Direct cannula entry for laparoscopy. *J Am Assoc Gynecol Laparosc* 1996;4(1):77-9.

### How to cite this article:

Bakay K, Aytekin F, Tunckiran A. Tips and Tricks in Laparoscopic Surgery in Light of 172 Patients, From A Gynecological Point of View in Turkey. *J Clin Anal Med* 2016;7(3): 321-6.