










Global evaluation of echocardiography in patients with COVID-19

Marc R. Dweck ^{1*}, Anda Bularga¹, Rebecca T. Hahn ², Rong Bing ¹, Kuan Ken Lee¹, Andrew R. Chapman ¹, Audrey White¹, Giovanni Di Salvo³, Leyla Elif Sade⁴, Keith Pearce⁵, David E. Newby ¹, Bogdan A. Popescu ⁶, Erwan Donal⁷, Bernard Cosyns ⁸, Thor Edvardsen ^{9,10}, Nicholas L. Mills^{1,11†}, and Kristina Haugaa ^{9,10†}

¹Centre for Cardiovascular Science, University of Edinburgh, UK; ²Columbia University Irving Medical Center, NY, USA; ³University Hospital Padua, Paediatric Cardiology, Padua, Italy; ⁴Department of Cardiology, University of Baskent, Ankara, Turkey; ⁵University Hospital South Manchester, Cardiology, Wythenshawe, Manchester, UK; ⁶Department of Cardiology, University of Medicine and Pharmacy 'Carol Davila'-Eurocolab, Emergency Institute for Cardiovascular Diseases 'Prof. Dr. C. C. Iliescu', Bucharest, Romania; ⁷University of Rennes, CHU Rennes, Inserm, LTSI-UMR 1099, Rennes, France; ⁸Centrum voor Hart en Vaatziekten, Universitair Ziekenhuis Brussel, Vrij Universiteit van Brussel, Brussels, Belgium; ⁹Department of Cardiology, Oslo University Hospital, Rikshospitalet, Oslo, Norway; ¹⁰Faculty of Medicine, University of Oslo, Oslo, Norway; and ¹¹Usher Institute, University of Edinburgh, UK

Received 22 May 2020; editorial decision 26 May 2020; accepted 2 June 2020; online publish-ahead-of-print 18 June 2020

Aims

To describe the cardiac abnormalities in patients with COVID-19 and identify the characteristics of patients who would benefit most from echocardiography.

Methods and results

In a prospective international survey, we captured echocardiography findings in patients with presumed or confirmed COVID-19 between 3 and 20 April 2020. Patient characteristics, indications, findings, and impact of echocardiography on management were recorded. Multivariable logistic regression identified predictors of echocardiographic abnormalities. A total of 1216 patients [62 (52–71) years, 70% male] from 69 countries across six continents were included. Overall, 667 (55%) patients had an abnormal echocardiogram. Left and right ventricular abnormalities were reported in 479 (39%) and 397 (33%) patients, respectively, with evidence of new myocardial infarction in 36 (3%), myocarditis in 35 (3%), and takotsubo cardiomyopathy in 19 (2%). Severe cardiac disease (severe ventricular dysfunction or tamponade) was observed in 182 (15%) patients. In those without pre-existing cardiac disease ($n = 901$), the echocardiogram was abnormal in 46%, and 13% had severe disease. Independent predictors of left and right ventricular abnormalities were distinct, including elevated natriuretic peptides [adjusted odds ratio (OR) 2.96, 95% confidence interval (CI) 1.75–5.05] and cardiac troponin (OR 1.69, 95% CI 1.13–2.53) for the former, and severity of COVID-19 symptoms (OR 3.19, 95% CI 1.73–6.10) for the latter. Echocardiography changed management in 33% of patients.

Conclusion

In this global survey, cardiac abnormalities were observed in half of all COVID-19 patients undergoing echocardiography. Abnormalities were often unheralded or severe, and imaging changed management in one-third of patients.

Keywords

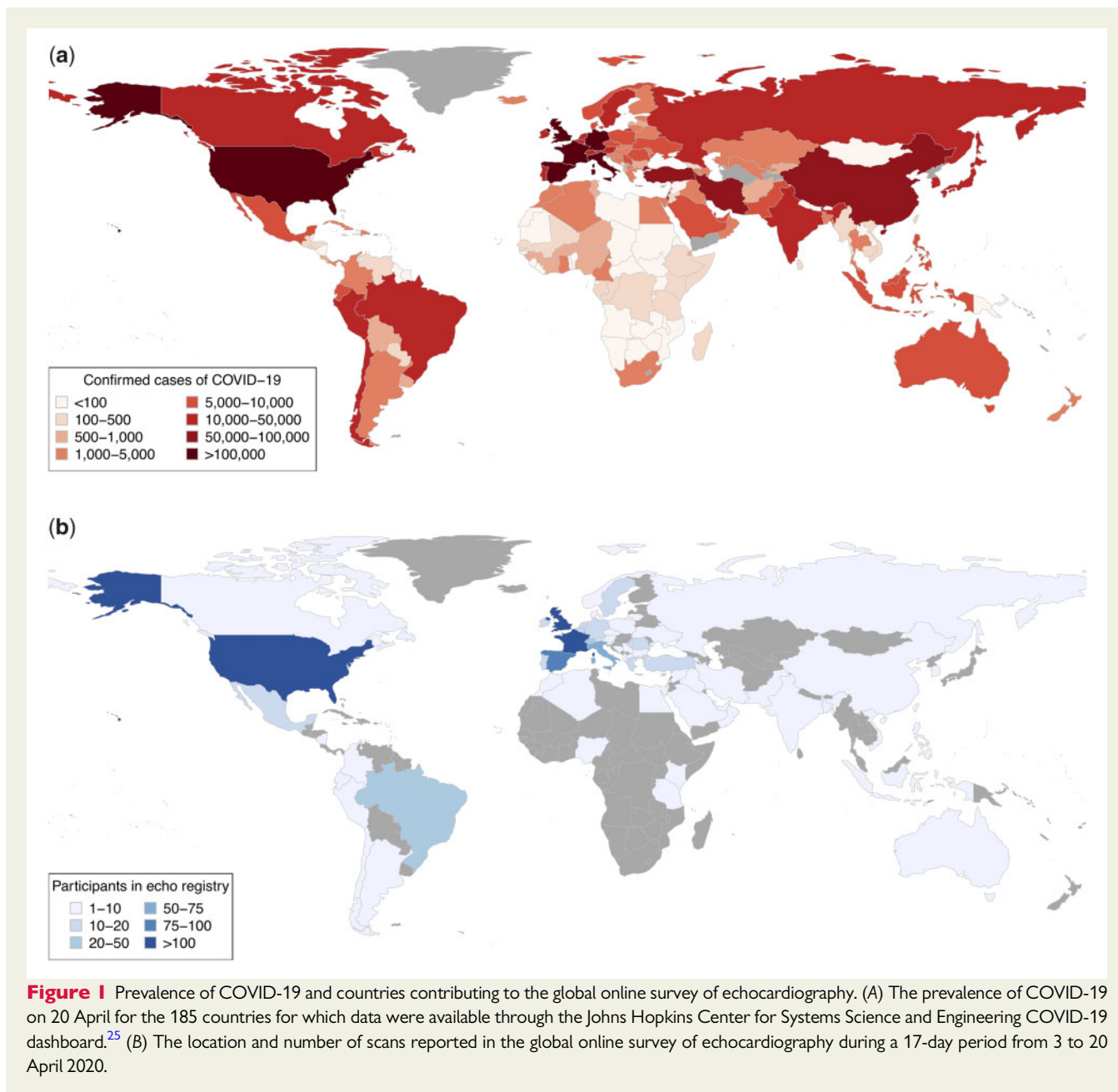
COVID-19 • Echocardiography

* Corresponding author. BHF/University Centre for Cardiovascular Science, The University of Edinburgh, Chancellor's Building, 49 Little France Crescent, Edinburgh EH16 4SB, UK, Email: marc.dweck@ed.ac.uk

† These authors contributed equally to this work.

© The Author(s) 2020. Published by Oxford University Press on behalf of the European Society of Cardiology.

This is an Open Access article distributed under the terms of the Creative Commons Attribution License (<http://creativecommons.org/licenses/by/4.0/>), which permits unrestricted reuse, distribution, and reproduction in any medium, provided the original work is properly cited.



Overall, 60% of scans were performed in a critical care setting (54% intensive care, 2% high dependency unit and coronary care unit, 5% emergency room, and 1% cardiac catheter laboratory), with the remainder performed in general medicine, cardiology, respiratory, and dedicated COVID-19 wards (Table 1). Correspondingly, 54% of patients had severe symptoms and 19% had evidence of pneumonia. Pre-existing cardiac disease was reported in 26% of patients due to a combination of ischaemic heart disease (14%), heart failure (9%), or valvular heart disease (7%). Hypertension (37%) and diabetes mellitus (19%) were also common. The most common indications for echocardiography were suspected left-sided heart failure (40%), elevated cardiac biomarkers (26%), and right-sided heart failure (20%). Chest pain with ST-segment elevation on the electrocardiogram (9%), circulatory shock (8%), ventricular arrhythmia (3%), and suspected

cardiac tamponade (2%) were less frequent, as were other indications, such as suspected pulmonary embolism (5%), endocarditis (6%), and myocarditis (1%).

Echocardiographic findings

Compared with patients with a normal echocardiogram ($n = 549$, 45%), patients with an abnormal scan ($n = 667$, 55%) were older and had a higher prevalence of pre-existing ischaemic heart disease, heart failure, or valvular heart disease, but a similar prevalence of hypertension or diabetes mellitus. The proportion of males was similar in both groups (Table 1; Figure 2, Central Illustration).

Table 1 Patient characteristics and indications for echocardiography

	Overall (n = 1216)	Abnormal scan (n = 667)	Normal scan (n = 549)	P-value*
Age	62 (52–71)	64 (53–73)	60 (51–69)	<0.001
Sex				0.600
Female	365 (30%)	195 (29%)	170 (31%)	
Male	844 (70%)	468 (71%)	376 (69%)	
Location of scan				0.053
Critical care	726 (60%)	382 (57%)	344 (63%)	
Non-critical care	486 (40%)	284 (43%)	202 (37%)	
COVID-19 status				<0.001
Confirmed	813 (73%)	409 (68%)	404 (79%)	
High probability	298 (27%)	193 (32%)	105 (21%)	
Evidence of pneumonia	232 (19%)	135 (20%)	97 (18%)	0.300
Symptom severity				<0.001
Mild	215 (18%)	98 (15%)	117 (23%)	
Moderate	327 (28%)	210 (32%)	117 (23%)	
Severe	625 (54%)	340 (52%)	285 (55%)	
Co-morbidities				
Hypertension	445 (37%)	254 (38%)	191 (35%)	0.300
Diabetes mellitus	233 (19%)	136 (20%)	97 (18%)	0.300
Ischaemic heart disease	167 (14%)	137 (21%)	30 (6%)	<0.001
Heart failure	113 (9%)	106 (16%)	7 (1%)	<0.001
Valvular heart disease	80 (7%)	53 (8%)	27 (5%)	0.045
Indication				
Suspected left heart failure	491 (40%)	294 (44%)	197 (36%)	0.011
Suspected right heart failure	243 (20%)	145 (22%)	98 (18%)	0.200
Chest pain and ST-elevation	107 (9%)	76 (11%)	31 (6%)	0.001
Elevated cardiac biomarkers	314 (26%)	216 (32%)	98 (18%)	<0.001
Troponin	239 (20%)	164 (25%)	75 (14%)	<0.001
BNP	129 (11%)	97 (15%)	32 (6%)	<0.001
Ventricular arrhythmia	38 (3%)	33 (5%)	5 (1%)	<0.001
Cardiac tamponade	20 (2%)	13 (2%)	7 (1%)	0.600
Circulatory shock	95 (8%)	65 (20%)	30 (6%)	0.017
Change in management				<0.001
Yes	405 (33%)	297 (45%)	108 (20%)	
No	675 (56%)	309 (46%)	366 (67%)	
Not known	136 (11%)	61 (9%)	75 (14%)	
Management group				<0.001
Disease-specific therapy	171 (14%)	130 (19%)	41 (8%)	
Level of care	32 (3%)	20 (3%)	12 (2%)	
Haemodynamic support	51 (4%)	35 (5%)	16 (3%)	
Other	151 (12%)	112 (17%)	39 (7%)	

Median (interquartile range), number (%). Abbreviations: BNP, brain B-type natriuretic peptide; COVID-19, coronavirus disease 2019.

*Between-group comparisons are χ^2 test or independent samples t-tests

Missing values in the overall population: age = 18; sex = 7; location of scan = 4; COVID-19 status = 8; symptom severity = 49; indication = 9.

Left ventricular abnormalities were reported in 479 (39%) patients, with echocardiographic evidence of new myocardial infarction in 36 (3%), myocarditis in 35 (3%), and takotsubo cardiomyopathy in 19 (2%). Left ventricular impairment was classified as mild, moderate, or severe in 17, 12, and 9% of patients, respectively. Right ventricular abnormalities were reported in 397 (33%) patients, with mild or moderate right ventricular impairment in 19% and severe impairment in 6%. Right ventricular dilatation (15%), elevated

pulmonary artery pressures (8%), and a D-shaped left ventricle (4%) were reported less frequently. Cardiac tamponade and endocarditis were reported in 11 (1%) and 14 (1%) patients, respectively. Severe cardiac disease, defined as severe left or right ventricular dysfunction or cardiac tamponade, was reported in 1 in 7 patients ($n = 182$, 15%; [Supplementary material online, Table S1](#)).

Abnormalities on the echocardiogram were more common in those where the indication for imaging was chest pain with ST-

Table 2 Echocardiographic findings stratified by indication

	Overall* [†] (n = 1216)	Suspected left heart failure (n = 491)	Suspected right heart failure (n = 243)	Chest pain and ST elevation (n = 107)	Elevated cardiac biomarkers (n = 314)	Elevated troponin (n = 239)	Elevated BNP (n = 129)	Multiple indications (n = 276)	Other [‡] (n = 299)
Overall findings									
Normal echocardiogram	549 (44%)	197 (40%)	98 (40%)	31 (29%)	98 (31%)	75 (31%)	32 (25%)	76 (28%)	180 (60%)
Abnormal echocardiogram	667 (53%)	294 (60%)	145 (60%)	76 (71%)	216 (69%)	164 (69%)	97 (75%)	200 (72%)	119 (40%)
Severe cardiac disease [§]	182 (15%)	81 (16%)	40 (16%)	11 (10%)	62 (20%)	44 (18%)	33 (26%)	63 (23%)	40 (13%)
Left ventricle*									
Normal	745 (61%)	247 (50%)	186 (77%)	33 (31%)	139 (44%)	109 (46%)	45 (35%)	114 (41%)	223 (75%)
Mild impairment	203 (17%)	92 (19%)	33 (14%)	38 (36%)	74 (24%)	60 (25%)	32 (25%)	66 (24%)	33 (11%)
Moderate impairment	140 (12%)	81 (16%)	10 (4%)	22 (21%)	50 (16%)	32 (13%)	25 (19%)	41 (15%)	18 (6%)
Severe impairment	112 (9%)	66 (13%)	12 (5%)	9 (8%)	45 (14%)	32 (13%)	26 (20%)	49 (18%)	21 (7%)
Dilated	66 (5%)	40 (8%)	8 (3%)	7 (7%)	31 (10%)	22 (9%)	19 (15%)	31 (11%)	11 (4%)
Evidence of new MI	36 (3%)	13 (3%)	4 (2%)	14 (13%)	22 (7%)	22 (9%)	7 (5%)	19 (7%)	4 (1%)
Evidence of myocarditis	35 (3%)	21 (4%)	4 (2%)	8 (8%)	24 (8%)	19 (8%)	13 (10%)	24 (9%)	4 (1%)
Evidence of takotsubo	19 (2%)	5 (1%)	1 (1%)	4 (4%)	11 (4%)	10 (4%)	5 (4%)	8 (3%)	6 (2%)
Right ventricle*									
Normal	842 (69%)	335 (68%)	124 (51%)	79 (74%)	206 (66%)	158 (66%)	79 (61%)	163 (59%)	224 (75%)
Mild to moderate impairment	236 (19%)	100 (20%)	64 (26%)	23 (21%)	79 (25%)	61 (26%)	37 (29%)	79 (29%)	48 (16%)
Severe impairment	77 (6%)	27 (6%)	32 (13%)	4 (4%)	20 (6%)	14 (6%)	9 (7.0%)	22 (8%)	16 (5%)
Dilated	181 (15%)	56 (11%)	76 (31%)	5 (5%)	44 (14%)	33 (14%)	21 (16%)	48 (17%)	41 (14%)
D-shaped left ventricle	46 (4%)	10 (2%)	22 (9%)	0 (0%)	8 (3%)	5 (2%)	6 (5%)	8 (3%)	12 (4%)
Elevated PAP	99 (8%)	31 (6%)	46 (19%)	3 (3%)	33 (11%)	23 (10%)	15 (12%)	31 (11%)	18(6%)
Other									
Tamponade	11 (1%)	3 (1%)	1 (1%)	0 (0%)	2 (1%)	2 (1%)	1 (1%)	3 (1%)	6 (2%)
Endocarditis	14 (1%)	3 (1%)	1 (1%)	0 (0%)	2 (1%)	1 (1%)	1 (1%)	2 (1%)	11 (4%)
Change in management									
Yes	405 (33%)	169 (34%)	85 (35%)	41 (38%)	123 (39%)	96 (40%)	53 (41%)	119 (43%)	96 (32%)
No	675 (56%)	243 (49%)	118 (49%)	62 (58%)	178 (57%)	133 (56%)	73 (57%)	134 (49%)	182 (61%)
Not known	136 (11%)	79 (16%)	40 (16%)	4 (4%)	13 (4%)	10 (4%)	3 (2%)	23 (8%)	21 (7%)
Management group									
Disease-specific therapy	171 (14%)	63 (13%)	38 (16%)	16 (15%)	53 (17%)	39 (16%)	26 (20%)	47 (17%)	42 (14%)
Level of care	32 (3%)	9 (2%)	3 (1%)	3 (3%)	6 (2%)	6 (3%)	1 (1%)	4 (1%)	13 (4%)
Haemodynamic support	51 (4%)	21 (4%)	11 (5%)	4 (4%)	12 (4%)	10 (4%)	3 (2%)	16 (6%)	14 (5%)
Other	151 (12%)	76 (15%)	33 (14%)	18 (17%)	52 (17%)	41 (17%)	23 (18%)	52 (19%)	27 (9%)

Values are number (%). BNP, brain natriuretic peptide; PAP, pulmonary artery pressure; LV, left ventricle; MI, myocardial infarction; RV, right ventricle.

*Groups are not mutually exclusive as patients may have more than one indication for echocardiography or abnormality.

[†]Nine patients included in the analysis had missing indications.

[‡]The other group includes patients with indication of ventricular arrhythmia, tamponade, circulatory shock, and a combination of free-text indications such as suspected endocarditis, or pulmonary embolus.

[§]Severe cardiac disease is defined as severe left ventricular or right ventricular dysfunction or cardiac tamponade.

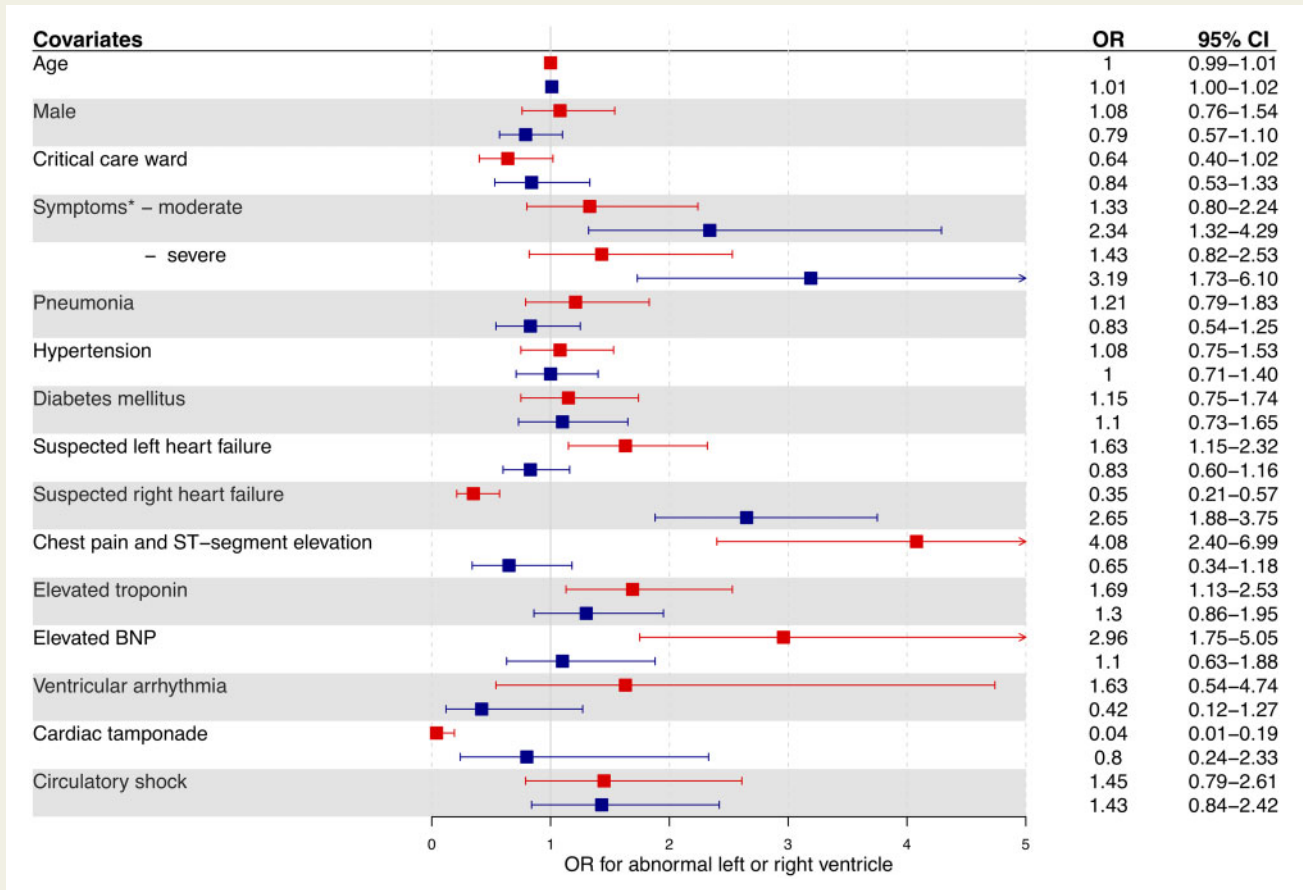


Figure 4 Predictors of an abnormal left (red) and right (blue) ventricle on echocardiography in patients with COVID-19 without pre-existing cardiac disease.

Two multivariable logistic regression models examined the associations of clinical covariates with abnormal left ventricular or abnormal right ventricular findings on echocardiography. Categorical covariate data comprised only those answers that were pre-defined in survey questions and were selected *a priori* based on clinical relevance. *Those with mild symptoms were the referent group for symptom severity. BNP, brain type natriuretic peptide.

patients had echocardiography performed in an intensive care unit. In this setting, optimization of management may have been previously instituted or changes in management limited by severe respiratory or haemodynamic compromise. Few previous studies have reported the impact of echocardiography on changes in management, and none has been performed in a critical care setting.²¹ To put our findings into context, Bethge *et al.* report in an outpatient setting that whilst 22% of patients had abnormal findings, management changed in only 3% of patients.²² Finally, we suggest that information supporting the continuation of a management strategy may be as clinically relevant as information that leads to the initiation of an alternative strategy.

The complex logistics involved in performing echocardiography in patients with COVID-19 and the risk of virus transmission necessitates robust selection of patients for imaging.²³ Our data do not imply that all patients with COVID-19 require an echocardiogram. Indeed, patients undergoing echocardiography here had clearly defined clinical indications. Our data suggest that cardiac biomarkers may help improve the selection of patients for imaging, with elevated BNP and cardiac troponin concentrations independent predictors of left and right ventricular abnormalities, respectively. Building on this study,

there is now a need for future imaging and biomarker studies to systematically investigate the cardiovascular manifestations of COVID-19, and to establish their true prevalence. The CAPACITY-COVID European Registry aims to determine the role of cardiovascular disease in the COVID-19 pandemic through standardized large-scale data collection.²⁴ Imaging with echocardiography and cardiovascular magnetic resonance following recovery from COVID-19 will be more readily achievable and will be well placed to define any residual cardiac damage caused by the condition. Similarly, studies investigating whether cardiac biomarkers can better direct clinical imaging and improve patient outcomes would be welcome.

Our study suffers from the usual limitations associated with an observational survey. Whilst by design we sought to conduct a rapid survey capturing key echocardiographic findings during the pandemic's peak, this limited the amount and granularity of the data we could capture. We are reliant on operator-reported findings, as is common in clinical practice, and acknowledge that definitive assessment and core lab verification of cardiac function with echocardiography in critically ill patients is challenging. A proportion of the data was collected from free text-fields, and as such may be biased and represent an underestimate of these findings or clinical variables. Additionally, this

survey is subject to substantial case selection bias. For example, we do not know the prevalence of abnormalities in those who did not undergo scanning. In view of the complex logistics around scanning, echocardiography was probably limited to those with clear clinical indications or those with increased disease severity. Furthermore, the use of echocardiography has probably decreased in the current pandemic due to concerns over viral transmission, and this may further contribute to the selection of patients for scanning. We did not capture patient outcomes, but many of the relevant outcomes have yet to occur. Finally, there were relatively few data from certain countries, including China. As the survey continues, we will seek to better target and gather more information from these countries, with further reports to follow.

In this global survey, cardiac abnormalities were observed in half of all COVID-19 patients undergoing echocardiography. Abnormalities were often unheralded or severe, and imaging changed management in one-third of patients.

Supplementary material

Supplementary material is available at *European Heart Journal – Cardiovascular Imaging* online.

Acknowledgements

We would like to acknowledge all of the sonographers and clinicians world-wide who contributed data to this survey under challenging conditions to further our collective knowledge. We also wish to recognize the significant help and support provided by the EACVI staff in conducting this survey, in particular Oceane Marie, as well as national echocardiographic societies including the British Society of Echocardiography. We acknowledge Professor Ewen Harrison and the DataSurg collaborative who inspired the mosaic plot.

Funding

This work was supported by a British Heart Foundation (BHF) Research Excellence Award to the University of Edinburgh (RE/18/5/34216). M.R.D., D.E.N., and N.L.M. are supported by the BHF through the award of an Intermediate Clinical Research Fellowship (FS/14/78/31020), Chair (CH/09/002), and Senior Clinical Research Fellowship (FS/16/14/32023), respectively. D.E.N. is the recipient of a Wellcome Trust Senior Investigator Award (WT103782AIA). M.R.D. is the recipient of the Sir Jules Thorn Award for Biomedical Science (15/JTA). A.R.C. is supported by a Starter Grant for Clinical Lecturers from the Academy of Medical Sciences, which is supported by the Wellcome Trust, the Medical Research Council, the British Heart Foundation, Versus Arthritis, Diabetes UK, and the British Thoracic Society [SGL021/1075].

Conflict of interest: N.L.M. has received honoraria and consultancy from Abbott Diagnostics, Roche Diagnostics Siemens Healthineers, and LumiraDx. E.D. has received material facilities from General Electric Healthcare and an educational grant from Bristol-Myer-Squibb. All other authors have no conflicts to declare.

Data availability: Data will be made available upon request to the corresponding author.

References

- Guan WJ, Ni ZY, Hu Y, Liang WH, Ou CQ, He JX, Liu L, Shan H, Lei CL, Hui DSC, Du B, Li LJ, Zeng G, Yuen KY, Chen RC, Tang CL, Wang T, Chen PY, Xiang J, Li SY, Wang JL, Liang ZJ, Peng YX, Wei L, Liu Y, Hu YH, Peng P, Wang JM, Liu JY, Chen Z, Li G, Zheng ZJ, Qiu SQ, Luo J, Ye JC, Zhu SY, Zhong NS. Clinical characteristics of coronavirus disease 2019 in China. *N Engl J Med* 2020; **382**:1708–1720.
- Gates B. Responding to Covid-19 – a once-in-a-century pandemic? *N Engl J Med* 2020;**382**:1677–1679.
- Huang C, Wang Y, Li X, Ren L, Zhao J, Hu Y, Zhang L, Fan G, Xu J, Gu X, Cheng Z, Yu T, Xia J, Wei Y, Wu W, Xie X, Yin W, Li H, Liu M, Xiao Y, Gao H, Guo L, Xie J, Wang G, Jiang R, Gao Z, Jin Q, Wang J, Cao B. Clinical features of patients infected with 2019 novel coronavirus in Wuhan, China. *Lancet* 2020;**395**:497–506.
- Li B, Yang J, Zhao F, Zhi L, Wang X, Liu L, Bi Z, Zhao Y. Prevalence and impact of cardiovascular metabolic disease on COVID-19 in China. *Clin Res Cardiol* 2020; **109**:531–538.
- Zhou F, Yu T, Du R, Fan G, Liu Y, Liu Z, Xiang J, Wang Y, Song B, Gu X, Guan L, Wei Y, Li H, Wu X, Xu J, Tu S, Zhang Y, Chen H, Cao B. Clinical course and risk factor for mortality of adult inpatients with COVID-19 in Wuhan, China: a retrospective cohort study. *Lancet* 2020;**395**:1054–1062.
- Shi S, Qin M, Shen B, Cai Y, Liu T, Yang F, Gong W, Liu X, Liang J, Zhao Q, Huang H, Yang B, Huang C. Association of cardiac injury with mortality in hospitalized patients with COVID-19 in Wuhan, China. *JAMA Cardiol* 2020;doi: 10.1001/jamacardio.2020.0950.
- Bangalore S, Sharma MHA, Slotwiner A, Yatskar L, Harari R, Shah B, Ibrahim H, Friedman GH, Thompson C, Alviar CL, Chadow HL, Fishman GI, Reynolds HR, Keller N, Hochman JS. ST-segment elevation in patients with Covid-19 – a case series. *N Engl J Med* 2020;doi: 10.1056/NEJMc2009020.
- Hu H, Ma F, Wei X, Fang Y. Coronavirus fulminant myocarditis saved with glucocorticoid and human immunoglobulin. *Eur Heart J* 2020;doi: 10.1093/eurheartj/ehaa190.
- Meyer P, Degrauwe S, Delden CV, Ghadri JR, Templin C. Typical takotsubo syndrome triggered by SARS-CoV-2 infection. *Eur Heart J* 2020;**41**:1860.
- Chapman AR, Bularga A, Mills NL. High-sensitivity cardiac troponin can be an ally in the fight against COVID-19. *Circulation* 2020;**141**:1733–1735.
- Tavazzi G, Pellegrini C, Maurelli M, Belliato M, Sciutti F, Bottazzi A, Sepe PA, Resasco T, Camporotondo R, Bruno R, Baldanti F, Paolucci S, Pelenghi S, Iotti GA, Mojoli F, Arbustini E. Myocardial localization of coronavirus in COVID-19 cardiogenic shock. *Eur J Heart Fail* 2020;**22**:911–915.
- Varga S, Flammer AJ, Steiger P, Haberecker M, Andermatt R, Zinkernagel AS, Mehra MR, Schuepbach RA, Ruschitzka F, Moch, H. Endothelial cell infection and endotheliitis in COVID-19. *Lancet* 2020;**395**:1417–1418.
- Haugaa KH, Marsan NA, Cameli M, D'Andrea A, Dweck MR, Carvalho RF, Holte E, Manka R, Michalski B, Podlesnikar T, Popescu BA, Schulz-Menger J, Sitges M, Stankovic I, Maurer G, Edvardsen T. Criteria for surveys: from the European Association of Cardiovascular Imaging Scientific Initiatives Committee. *Eur Heart J Cardiovasc Imaging* 2019;**20**:963–936.
- Cameli M, Marsan NA, D'Andrea A, Dweck MR, Fontes-Carvalho R, Manka R, Michalski B, Podlesnikar T, Sitges M, Popescu BA, Edvardsen T, Fox KF, Haugaa KH. EACVI survey on multimodality training in ESC countries. *Eur Heart J Cardiovasc Imaging* 2019;**20**:1332–1336.
- Michalski B, Dweck MR, Marsan NA, Cameli M, D'Andrea A, Carvalho RF, Holte E, Robert TP, Haugaa KH. The evaluation of aortic stenosis, how the new guidelines are implemented across Europe: a survey by EACVI. *Eur Heart J Cardiovasc Imaging* 2020;**21**:357–362.
- Madjid M, Miller CC, Zarubaev VV, Marinich IG, Kiselev OI, Lobzin YV, Filippov AE, Casscells SW 3rd. Influenza epidemics and acute respiratory disease activity are associated with a surge in autopsy-confirmed coronary heart disease death: results from 8 years of autopsies in 34 892 subjects. *Eur Heart J* 2007;**28**:1205–1210.
- Kwong JC, Schwartz KL, Campitelli MA, Chung H, Crowcroft NS, Karnauchow T, Katz K, Ko DT, McGeer AJ, McNally D, Richardson DC, Rosella LC, Simor A, Smieja M, Zahariadis G, Gubbay JB. Acute myocardial infarction after laboratory-confirmed influenza infection. *N Engl J Med* 2018;**378**:345–353.
- Vardeny O, Solomon SD. Influenza vaccination: a one-shot deal to reduce cardiovascular events. *Eur Heart J* 2017;**38**:334–337.
- Madjid M, Connolly AT, Nabutovsky Y, Safavi-Naeini P, Razavi M, Miller CC. Effect of high influenza activity on risk of ventricular arrhythmias requiring therapy in patients with implantable cardiac defibrillators and cardiac resynchronization therapy defibrillators. *Am J Cardiol* 2019;**124**:44–50.
- Cui S, Chen S, Li X, Liu S, Wang F. Prevalence of venous thromboembolism in patients with severe novel coronavirus pneumonia. *J Thromb Haemost* 2020;doi: 10.1111/jth.14830.
- Singh K, Mayo P. Critical care echocardiography and outcomes in the critically ill. *Curr Opin Crit Care* 2018;**24**:316–321.
- Bethge A, Penciu O, Baksh S, Parve S, Lobraico J, Keller AM. Appropriateness versus value: echocardiography in primary care. *Clin Cardiol* 2017;**40**:1212–1217.


23. Skulstad H, Cosyns B, Popescu BA, Galderisi M, Salvo GD, Donal E, Petersen S, Gimelli A, Haugaa KH, Muraru D, Almeida AG, Schulz-Menger J, Dweck MR, Pontone G, Sade LE, Gerber B, Maurovich-Horvat P, Bharucha T, Cameli M, Magne J, Westwood M, Maurer G, Edvardsen T. COVID-19 pandemic and cardiac imaging: EACVI recommendations on precautions, indications, prioritization, and protection for patients and healthcare personnel. *Eur Heart J Cardiovasc Imaging* 2020;**21**:592–598.
24. Linschoten M, Asselbergs FW on behalf of CAPACITY-COVID collaborative consortium. CAPACITY-COVID: a European registry to determine the role of cardiovascular disease in the COVID-19 pandemic. *Eur Heart J* 2020;**41**: 1795–796.
25. Dong E, Du H, Gardner L. An interactive web-based dashboard to track COVID-19 in real time. *Lancet Infect Dis* 2020;**20**:533–534.

IMAGE FOCUS

doi:10.1093/ehjci/jeaa067

Online publish-ahead-of-print 25 April 2020

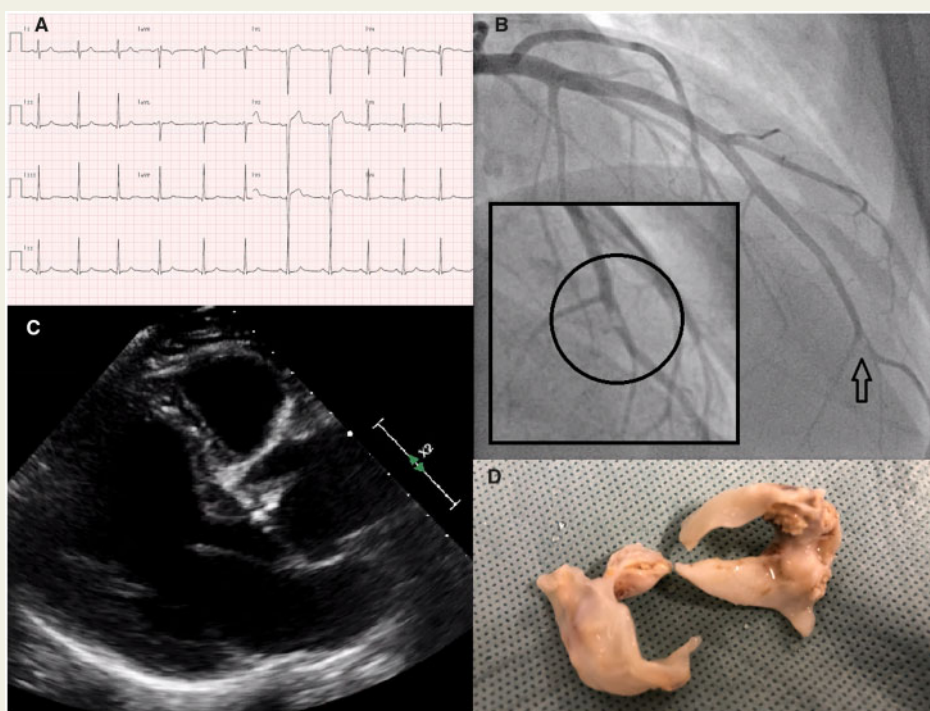
A young man with a ST-elevation myocardial infarction

Jesse R. Kimman ¹* Wouter J. van Leeuwen², and Felix Zijlstra¹

¹Department of Cardiology, Erasmus Medical Center, Doctor Molewaterplein 40, 3015 GD Rotterdam, The Netherlands; and ²Department of Cardiothoracic Surgery, Erasmus Medical Center, Doctor Molewaterplein 40, 3015 GD Rotterdam, The Netherlands

* Corresponding author. Tel: +31 107034280. E-mail: j.kimman@erasmusmc.nl

A 34-year-old man was seen at the emergency department with acute retrosternal chest pain. His medical history reported an asymptomatic bicuspid aortic valve. The electrocardiogram revealed signs of left ventricular hypertrophy and convex ST-segment elevations in leads V1–V4 without clear reciprocal depressions (Panel A). The patient underwent a coronary angiography which showed non-atherosclerotic coronary arteries with a small calcic embolus in the distal left anterior descending artery (arrow in Panel B; circled in zoomed-in image). Because the pain was disappeared spontaneously and the ST segments were normalized, no intervention was performed. The invasive mean gradient of the aortic valve was 49 mmHg. Laboratory tests



revealed a rise and fall of cardiac enzymes with a maximum detected creatine kinase myocardial band level of 219 µg/L. Transthoracic echocardiogram showed an extensively calcified aortic valve with severe aortic stenosis, a dilated ascending aorta (maximum diameter 46 mm) and akinesia of the left ventricular apex (Panel C). The patient underwent an urgent surgical mechanical aortic valve and Bentall aortic arc replacement (Panel D). He recovered well and was discharged 6 days later. In conclusion, we report a rare case of a patient presenting with an anterior ST-elevation myocardial infarction as a first symptom of a severe aortic stenosis.

© The Author(s) 2020. Published by Oxford University Press on behalf of the European Society of Cardiology.

This is an Open Access article distributed under the terms of the Creative Commons Attribution Non-Commercial License (<http://creativecommons.org/licenses/by-nc/4.0/>), which permits non-commercial re-use, distribution, and reproduction in any medium, provided the original work is properly cited. For commercial re-use, please contact journals.permissions@oup.com