

---

# Multidisciplinary management of an adult skeletal Class III patient with generalized aggressive periodontitis and canine-premolar transposition

Sinem İnce-Bingöl,\* Mediha Nur Nişancı-Yılmaz† and Burçak Kaya\*

Department of Orthodontics, Faculty of Dentistry, Baskent University, Ankara, Turkey\* Department of Periodontology, Faculty of Dentistry, Baskent University, Ankara, Turkey†

This case report presents orthodontic camouflage treatment and the correction of transposed canine-first premolar teeth in a patient who presented with a skeletal Class III and familial periodontal problem. A 28-year-old female patient who was diagnosed with generalised aggressive periodontitis was treated by scaling and root planing plus the adjunctive use of systemic antibiotics and surgical therapy prior to referral to the orthodontic department. After the progression of the disease was controlled, orthodontic treatment was commenced to correct the dental transposition by using a modified Nance-TPA appliance and sectional arch mechanics. A non-extraction orthodontic camouflage treatment was planned to eliminate the anterior crossbite and to establish a proper occlusion by closing the multiple diastemata. Treatment outcomes remained stable in the 2-year follow-up period. Severe orthodontic-periodontal problems can be successfully treated by oral hygiene motivation, an interdisciplinary approach, and the selection of appropriate biomechanics.

(Aust Orthod J 2021; 37: 165 - 175. DOI: 10.21307/aoj-2021.022)

Received for publication: February, 2021

Accepted: August, 2021

Sinem İnce-Bingöl: hsinemince@gmail.com; Mediha Nur Nişancı-Yılmaz: mnur\_nisanci@hotmail.com; Burçak Kaya: burcak\_kaya@hotmail.com

## Introduction

A prime objective of orthodontic treatment is the maintenance and preservation of periodontal health. The biological process of bone apposition and resorption caused by orthodontic tooth movement, if accompanied by periodontal inflammation, can have unfavourable effects on the healing of periodontal tissues.<sup>1</sup> Orthodontic treatment can be challenging when the tissues supporting the teeth are affected or lost due to periodontal disease.

Tooth transposition is defined as the positional interchange of two adjacent teeth.<sup>2</sup> The transposition between a canine and first premolar has been reported as the most common type of tooth transposition in the maxillary arch.<sup>2</sup>

Aggressive periodontitis is an inflammatory disease characterized by a rapid and severe breakdown of

periodontal attachment and alveolar bone that is inconsistent with the amount of microbial deposits. The condition mostly affects healthy young people and shows a familial predisposition indicating a genetic influence.<sup>3,4</sup> The generalized form of aggressive periodontitis (GAgP) is most often diagnosed under the age of 30. It is characterised by severe destruction of the periodontal supporting tissues of at least three permanent teeth as well as the incisors and first molars and may lead to the loss of teeth in early life.<sup>3,5</sup>

The present case report describes the successful mutual outcomes of orthodontic and periodontal treatments that remained stable during the 2-year follow-up period in a patient who had generalised horizontal bone loss, a skeletal Class III relationship, an anterior crossbite, flaring of the lower incisors, multiple diastemata caused by a traumatic occlusion, and transposition of the upper right canine and first premolar.

### **Diagnosis and aetiology**

A 28-year-old female patient presented to Başkent University Faculty of Dentistry in 2016 and was referred to the periodontology and orthodontic departments with the chief complaint of gaps between the teeth. The patient did not smoke, had no systemic disease, and was not taking medication, but had a family history of periodontal disease.

Before orthodontic treatment, the patient underwent a comprehensive clinical periodontal examination including an assessment of probing depth, clinical attachment level, bleeding on probing and plaque index. Full-mouth periodontal charting showed that probing depths ranged from 2 to 8 mm with the presence of bleeding on probing and plaque accumulation noted in more than 50% of the sites (Figure 1). Generalised horizontal radiographic bone loss extending to the mid-third of the roots at some sites was observed on panoramic radiography. A furcation involvement was present on the buccal aspect of the mandibular right first molar. Based on the radiographic and periodontal examinations and according to the American Academy of Periodontology criteria, the diagnosis was generalised aggressive periodontitis.<sup>3</sup>

The clinical orthodontic examination revealed a straight profile, a retrusive upper lip, a reduced display of the upper incisors accompanied by an increased display of the lower incisors (Figure 2). Generalised gingival recession, multiple diastemata caused by a traumatic occlusion, flaring of the lower incisors, transposition of canine and first premolar teeth in the maxillary right side, a midline deviation and an anterior crossbite were observed following an intraoral examination (Figure 2). The patient had an Angle Class I molar relationship on both sides, a Class III

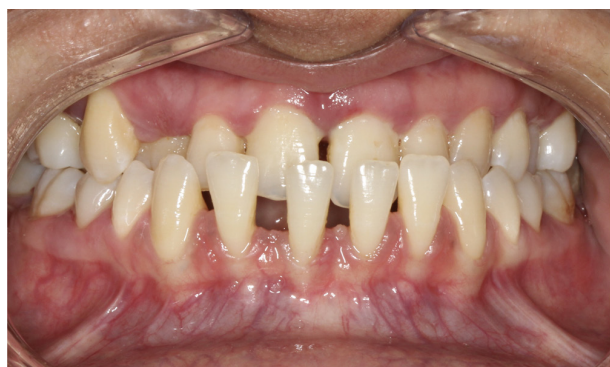

Figure 1. Intraoral photograph taken during the periodontal examination.

canine relationship on the right side and a Class I canine relationship on the left side. An arch length discrepancy of +1.7 mm for the maxilla and +9.4 mm for the mandible was measured which indicated the multiple diastemata. A 1.4 mm Bolton excess was detected in the mandibular anterior teeth.

The panoramic radiograph revealed the generalised horizontal bone loss and the transposition of the upper canine and first premolar on the right side (Figure 3). The cephalometric analysis showed a skeletal Class III relationship (ANB:  $-3.3^\circ$ ; Wits:  $-4.3$  mm) due to mandibular prognathia (SNB:  $84.4^\circ$ ). A low mandibular plane angle skeletal pattern (SN-GoGn:  $21.5^\circ$ ), normal inclination of the upper incisors (U1-PP:  $111.8^\circ$ ) and proclination of the lower incisors (IMPA:  $99.1^\circ$ ) were noted. A soft tissue analysis revealed a retrusive upper lip (Ulip to E plane:  $-7.2$  mm) and a slightly protrusive lower lip (Llip to E plane:  $-1.7$  mm). The patient had a reverse overjet ( $-4.8$  mm) and a moderately increased overbite (3.9 mm) (Table I).

### **Treatment objectives**

The main treatment goals were: (1) to control the periodontal disease and to maintain healthy periodontal tissues throughout orthodontic treatment; (2) to improve the smile aesthetics; (3) to establish a stable occlusion by correcting the anterior crossbite; (4) to correct the transposition of the upper right teeth; (5) to align the teeth; (6) to close the multiple diastemata, (7) to create an ideal overjet and overbite, (8) to obtain a proper incisor relationship with ideal incisor inclinations; and (9) to correct the midlines.

### **Treatment alternatives**

Tooth extraction was not considered in the treatment plan since the patient had multiple diastemata, a skeletal Class III relationship, an anterior crossbite and a straight profile with a retruded upper lip. Therefore, orthodontic camouflage treatment was planned to mask the underlying skeletal problem.

Two non-extraction treatment alternatives were identified upon presenting the treatment objectives. The first option was to keep the transposed order of the teeth by maintaining the first premolar in the canine region. The second alternative was to correct the transposition by moving the canine and first premolar teeth to their correct arch positions.

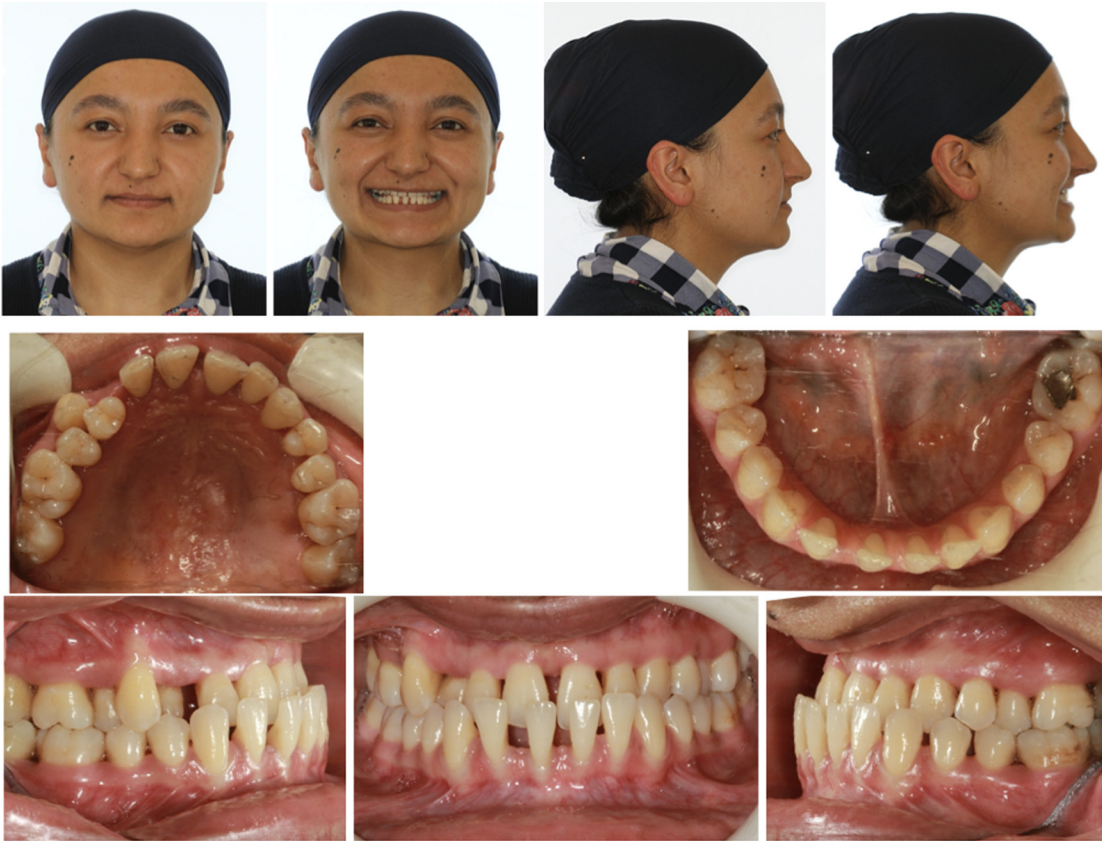

Figure 2. Pretreatment extraoral and intraoral photographs.

The first treatment alternative had the advantage of a less complex treatment need with a shorter treatment time, whereas the disadvantages were occlusal adjustments and prosthetic restorations at the end of orthodontic treatment. The patient did not want prosthetic restorations and therefore, the second alternative was selected.

### ***Treatment progress***

Oral hygiene instruction and periodontal scaling were performed. Root planing sessions were scheduled before placement of the orthodontic appliances. The patient was prescribed combined systemic antibiotic therapy (500 mg amoxicillin and 500 mg metronidazole three times a day for a week) and a chlorhexidine mouth rinse (0.12% twice a day). Full-mouth root planing was performed using an ultrasonic device and hand scaling under local anesthesia within the first week. The patient was re-examined after 6 weeks at which time the periodontal clinical parameters, oral hygiene performance and motivation were re-evaluated. Scaling and root planing was

redirected at tooth sites with residual pockets and bleeding on probing. This was followed 3 months later, by soft tissue flap surgery in the left maxillary quadrant to eliminate residual periodontal pockets. Subsequent to the surgical management, recall visits were scheduled at 3 monthly intervals. Supra- and subgingival mechanical debridements were performed, as necessary and throughout the following 6 months, probing depths and bleeding on probing were reduced, the patient considered motivated, and the oral hygiene level acceptable. The patient was then enrolled in a regular supportive maintenance program to monitor the disease and was referred to the orthodontic department.

A modified Nance-TPA appliance with palatal hooks was placed to commence orthodontic treatment and later sectional arch mechanics were used for correction of the transposition. Derotation and palatal movement of the transposed maxillary premolar were achieved by using an elastic chain linked between the palatal cusp of the tooth and the palatal hooks. Pre-adjusted edgewise appliances with an MBT prescription (0.018 × 0.025-inch) (American Orthodontics,

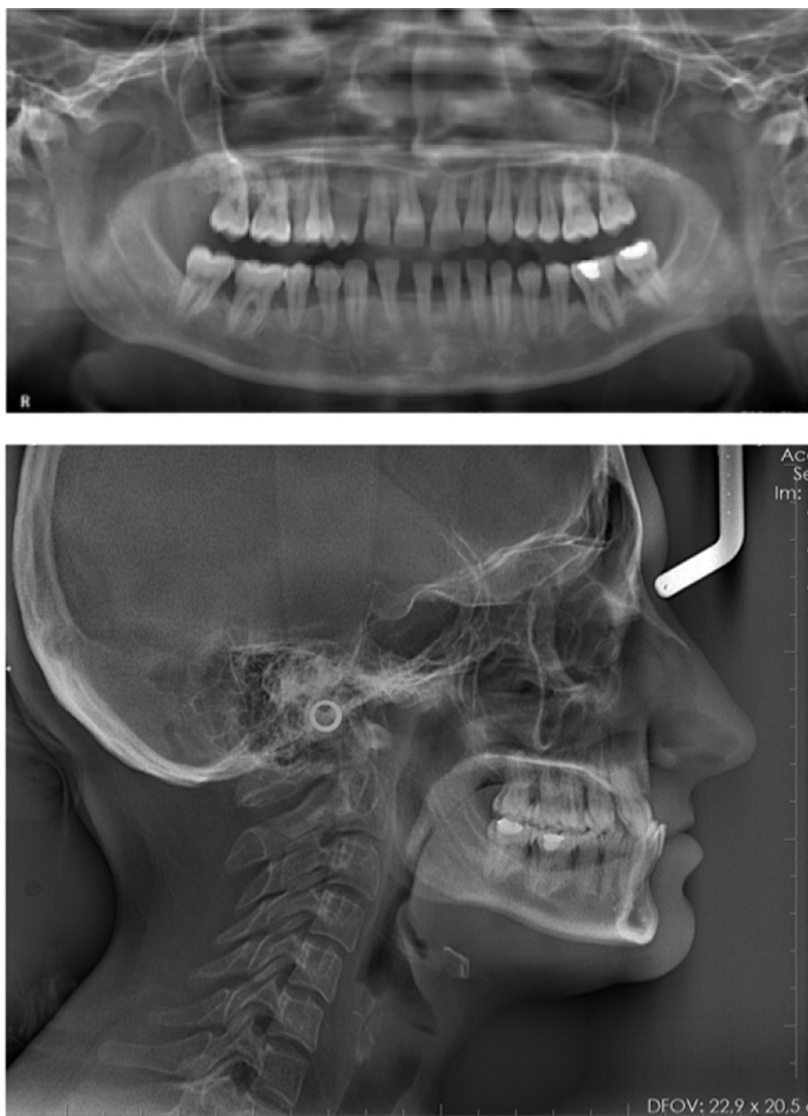


Figure 3. Pretreatment panoramic X-ray and lateral cephalogram.

Table I. Cephalometric measurements at the pretreatment, posttreatment and follow-up with norm values.

Measurements	Norm	Pretreatment	Posttreatment	2-year follow-up
SNA (°)	80° ± 2°	81.1°	81.3°	81.4°
SNB (°)	78° ± 2°	84.4	82.3°	82.2°
ANB (°)	2° ± 2°	-3.3°	-1°	-0.8°
SN-GoGn (°)	32° ± 6°	21.5°	22.7°	22.8°
Facial Angle (°)	88° ± 6°	95.4°	90.2°	90.2°
U1-PP (°)	112° ± 6°	111.8°	114.7°	114.5°
IMPA (°)	90° ± 3°	99.1°	88.7°	88.8°
Overjet (mm)	2.5 mm	-4.8 mm	2.6 mm	2.7 mm
Overbite (mm)	2.5 mm	3.9 mm	2.9 mm	3 mm
U lip-E plane (mm)	-4 mm	-7.2 mm	-5.9 mm	-5.7 mm
L lip-E plane (mm)	-2 mm	-1.7 mm	-4.7 mm	-4.7 mm

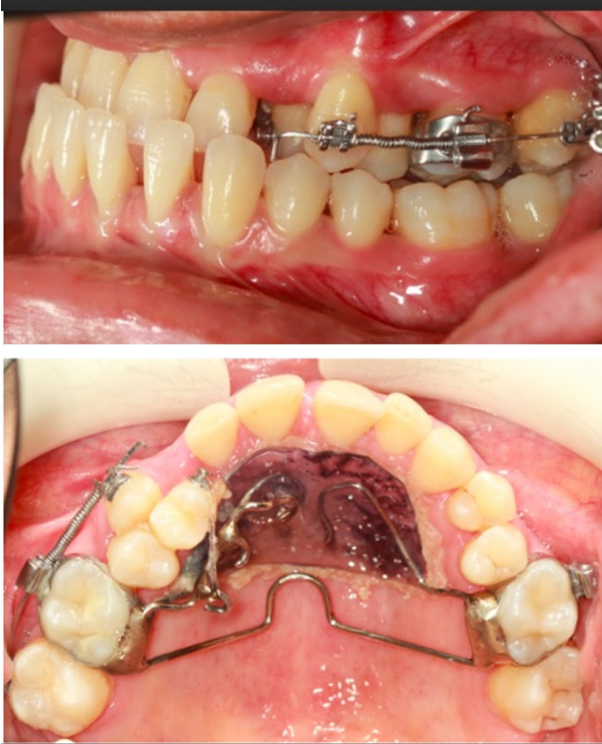

Figure 4. Correction of the transposition using a modified Nance-TPA appliance and sectional arch mechanics.

Sheboygan, WI, USA) were bonded for the placement of sectional mechanics in the posterior maxillary arch. The transposed canine was moved mesially on a  $0.016 \times 0.022$  SS archwire by a push coil spring placed between the first molar and canine (Figure 4). After the transposition was corrected, all of the teeth in the maxillary and mandibular arches were bonded. To assist in obtaining a positive overjet, bite opening was achieved by occlusal attachments which were bonded to the posterior teeth. A mini-screw (Tomas, Dentaaurum, Ispringen, Germany),  $2.3 \times 8$  mm in size placed between the lower left canine and first premolar was used for anchorage control during the mesialisation of the left lower posterior teeth for the correction of the midline deviation (Figure 5).

## Results

An aesthetic smile was obtained by providing an increased display of upper incisors. A decrease in lower lip prominence and chin projection improved the soft tissue profile. The anterior crossbite, transposition of the canine and first premolar, and the traumatic occlusion were eliminated. A stable occlusion with an ideal overjet and overbite was achieved by closing

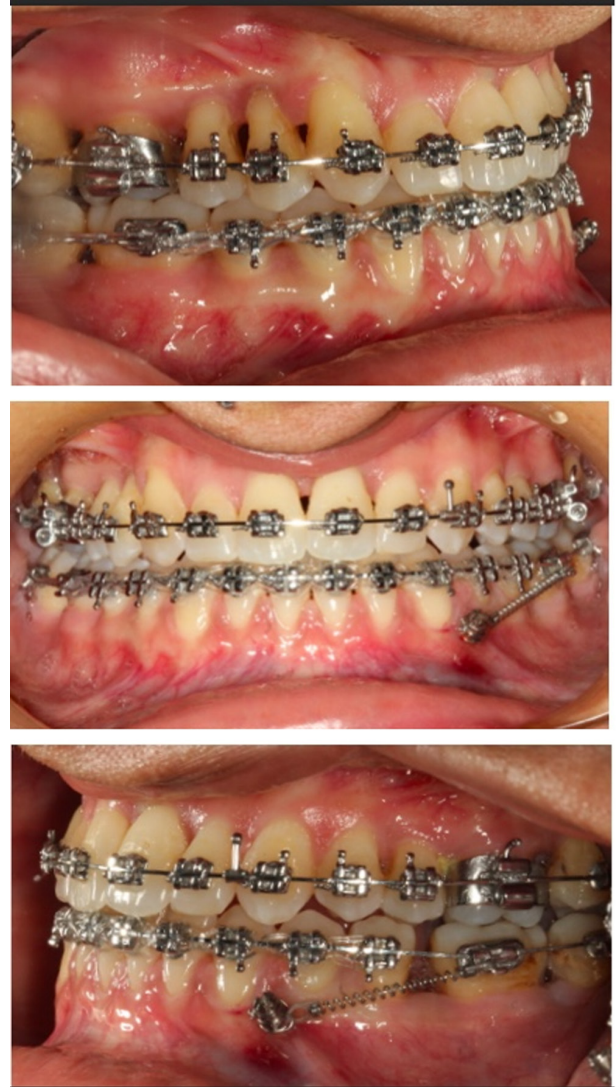

Figure 5. Correction of the midline deviation by mesializing the left posterior teeth using mini-screw anchorage.

the multiple diastemata. Class I canine and molar relationships were obtained (Figure 6). Total treatment time was 42 months. The patient was constantly under maintenance during the orthodontic phase to prevent an exacerbation of the periodontal disease. Special care was taken to avoid applying heavy orthodontic forces during treatment.

The sagittal maxillomandibular relationship improved (ANB  $-1^\circ$ ; Wits  $-0.9$  mm), mandibular angle increased (SN-GoGn  $22.7^\circ$ ), the upper incisors proclined (U1-PP  $114.7^\circ$ ) and the lower incisors retroclined (IMPA  $88.7^\circ$ ) according to the posttreatment cephalometric analysis (Table 1). Root parallelism without signs of root resorption was achieved and no additional bone resorption affecting the survival of the dentition was

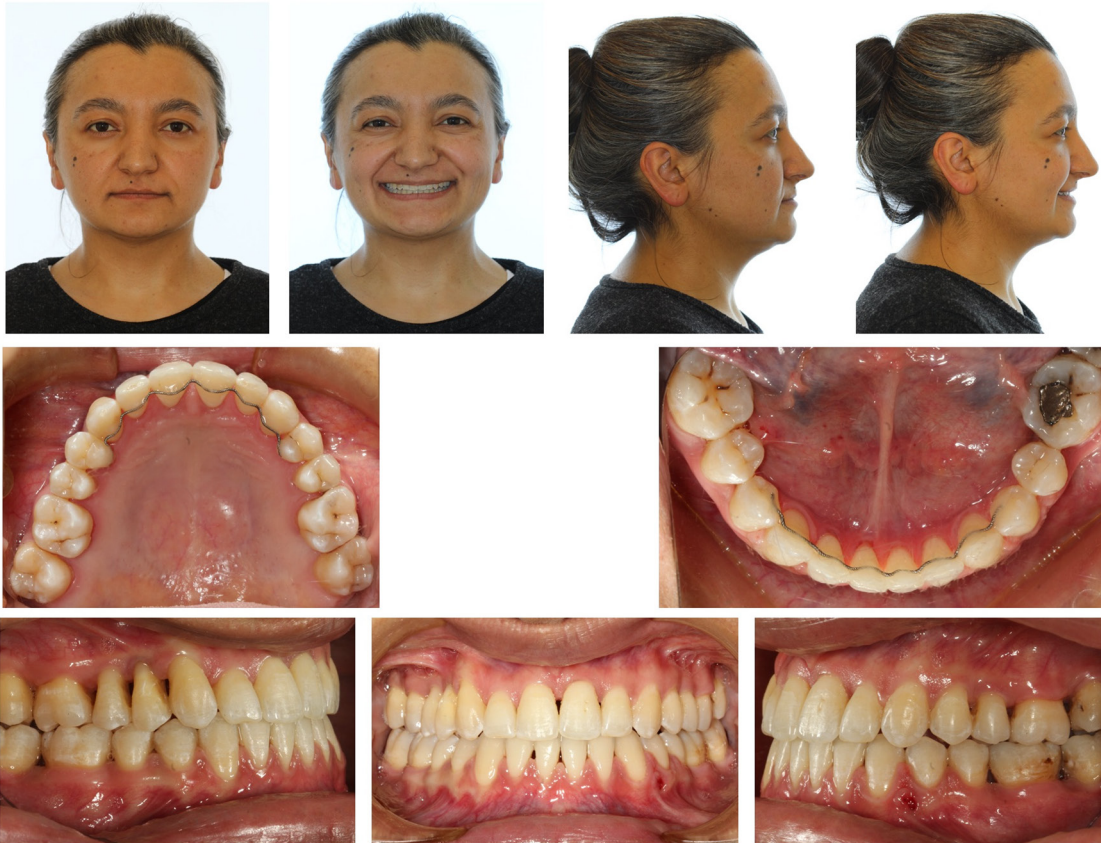

Figure 6. Posttreatment extraoral and intraoral photographs.

noted (Figure 7). The cephalometric superimposition indicated posterior mandibular rotation, proclination of the upper incisors, retroclination of the lower incisors, retraction of the lower lip and a downward displacement of the chin (Figure 8). Fixed retainers combined with vacuum-formed retainers were used in the upper and lower arches during the retention period. Stable results were maintained throughout the 2-year follow-up (Figures 9 and 10). No clinical signs indicating a recurrence of the periodontal disease were detected. Oral hygiene instructions were repeated at each visit.

## Discussion

Orthodontic treatment can be a challenge in patients who present with severe periodontal disease and so a multidisciplinary treatment plan is invariably required. The severity of periodontal attachment loss may be increased by tooth movement following the application of an orthodontic force.<sup>6</sup> Stable periodontal health and a high level of oral hygiene are essential for successful orthodontic treatment.<sup>7</sup>

Aggressive periodontitis is a complex multifactorial disease in which interactions between microbiological, immunological, genetic, and environmental factors play a role in the onset, prevalence and severity of the disease.<sup>8</sup> The initial treatment phase of the disease starts with non-surgical mechanical debridement of the biofilm and calculus.<sup>9</sup> Researchers have reported that using systemic antibiotics as adjuncts to scaling and root planing (SRP) showed clinically positive outcomes compared to SRP alone in patients with advanced periodontal diseases.<sup>10,11</sup> In particular, the combined use of metronidazole and amoxicillin has been advocated due to the wide spectrum of activity and the synergistic effectiveness against periodontal pathogens which are closely associated with GAgP.<sup>12–14</sup> The patient should be informed about her/his current periodontal status before all clinical treatment. Additionally, the importance of a high oral hygiene level and compliance during active and supportive periodontal therapy should be acknowledged.<sup>14</sup>

An improvement was observed in the periodontal clinical parameters of this patient after the start of active treatment. No additional bone destruction,

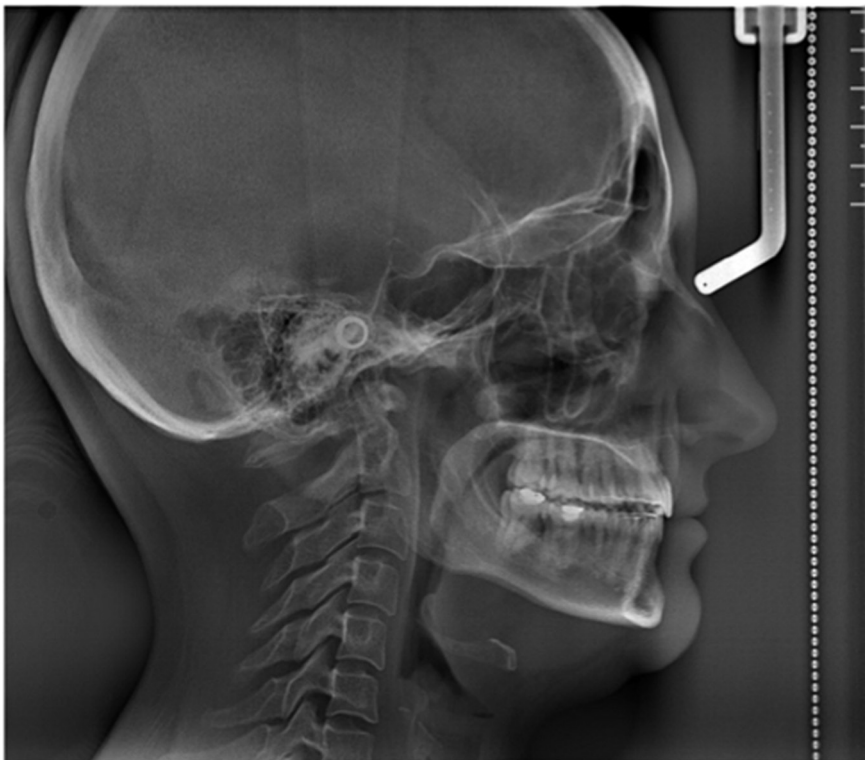
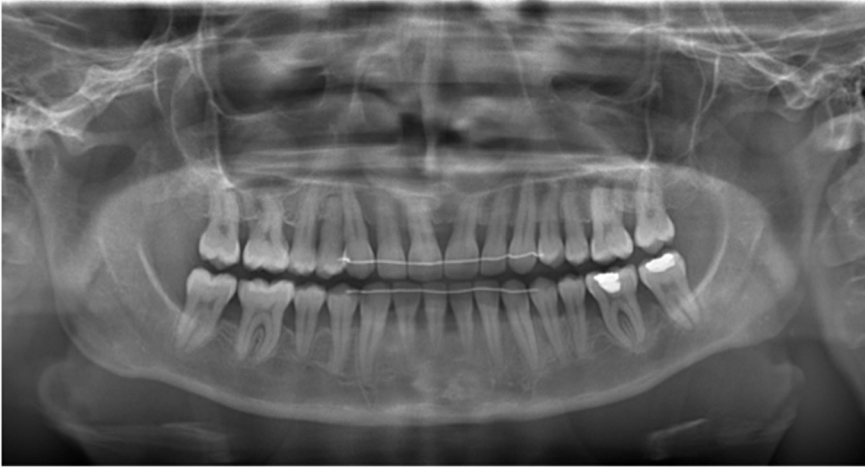
Figure 7. Posttreatment panoramic X-ray and lateral cephalogram.

which would result in poor prognosis of the teeth, was detected during the orthodontic phase. These findings are consistent with previous studies showing improvement in periodontal condition after orthodontic tooth movement.<sup>15,16</sup> Normalised tooth and dental arch interrelationships are associated with good level of oral hygiene, since malocclusion and crowding may hinder effective plaque control.<sup>17,18</sup> However, signs of gingival inflammation, an increased plaque index and probing depths are often observed following the placement of orthodontic appliances.<sup>19,20</sup> Nevertheless, additional

loss of periodontal attachment and bone in patients with periodontitis maybe prevented by strict biofilm control and professional prophylaxis.<sup>21</sup>

The transposition between a canine and the first premolar teeth warrants that treatment alternatives with or without extraction be fully considered and discussed.<sup>22,23</sup> The extraction of either all first premolars or the transposed premolar might be valid options. In a non-extraction approach, the teeth may either be kept in the transposed position or aligned in the correct order. In the present case, extraction,

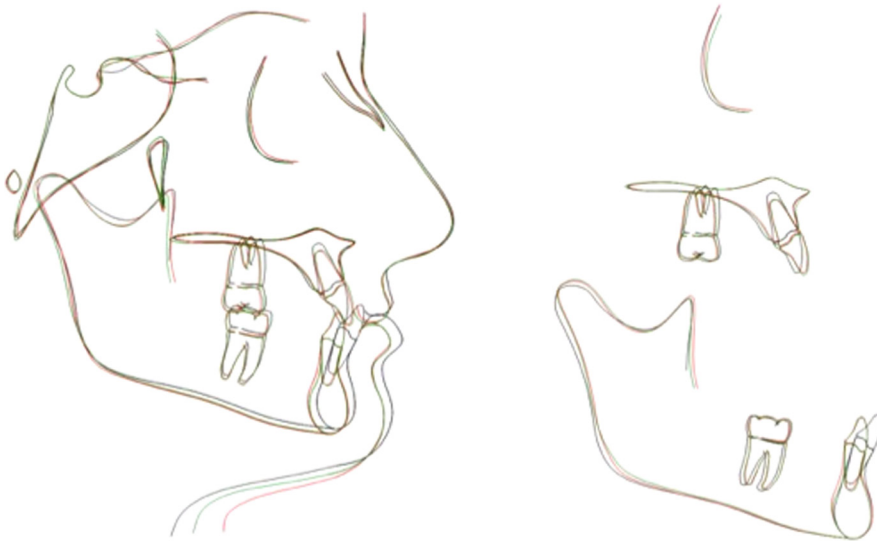


Figure 8. Superimposition of the lateral cephalograms taken at the beginning of treatment (black lines), end of treatment (red lines), and 2-year follow-up (green lines).

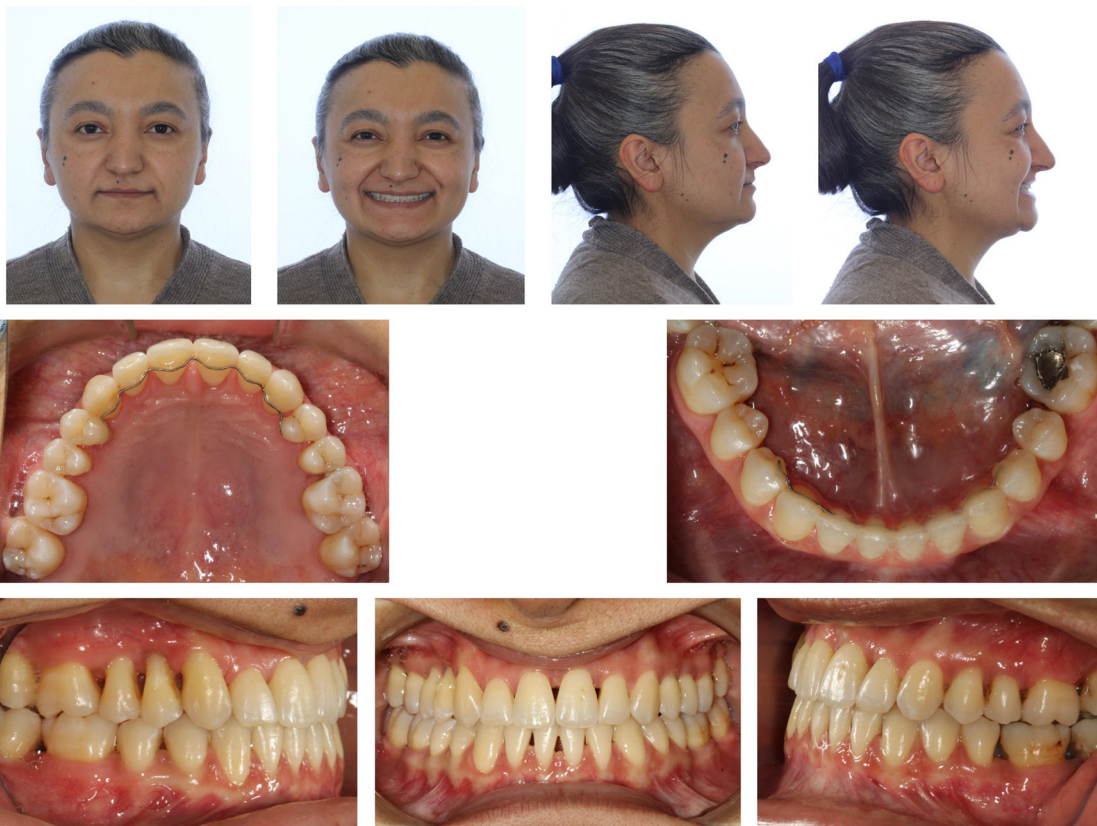

Figure 9. Extraoral and intraoral photographs at 2-year follow-up.

especially from the maxillary dental arch, was avoided in a consideration of the skeletal Class III tendency, the anterior crossbite, and the flat profile involving a retruded upper lip.

The correction of a transposition provides clinical advantages by placing the canine tooth in its correct position, to provide canine guidance, obtain arch symmetry, attain aesthetic support for the nasolabial



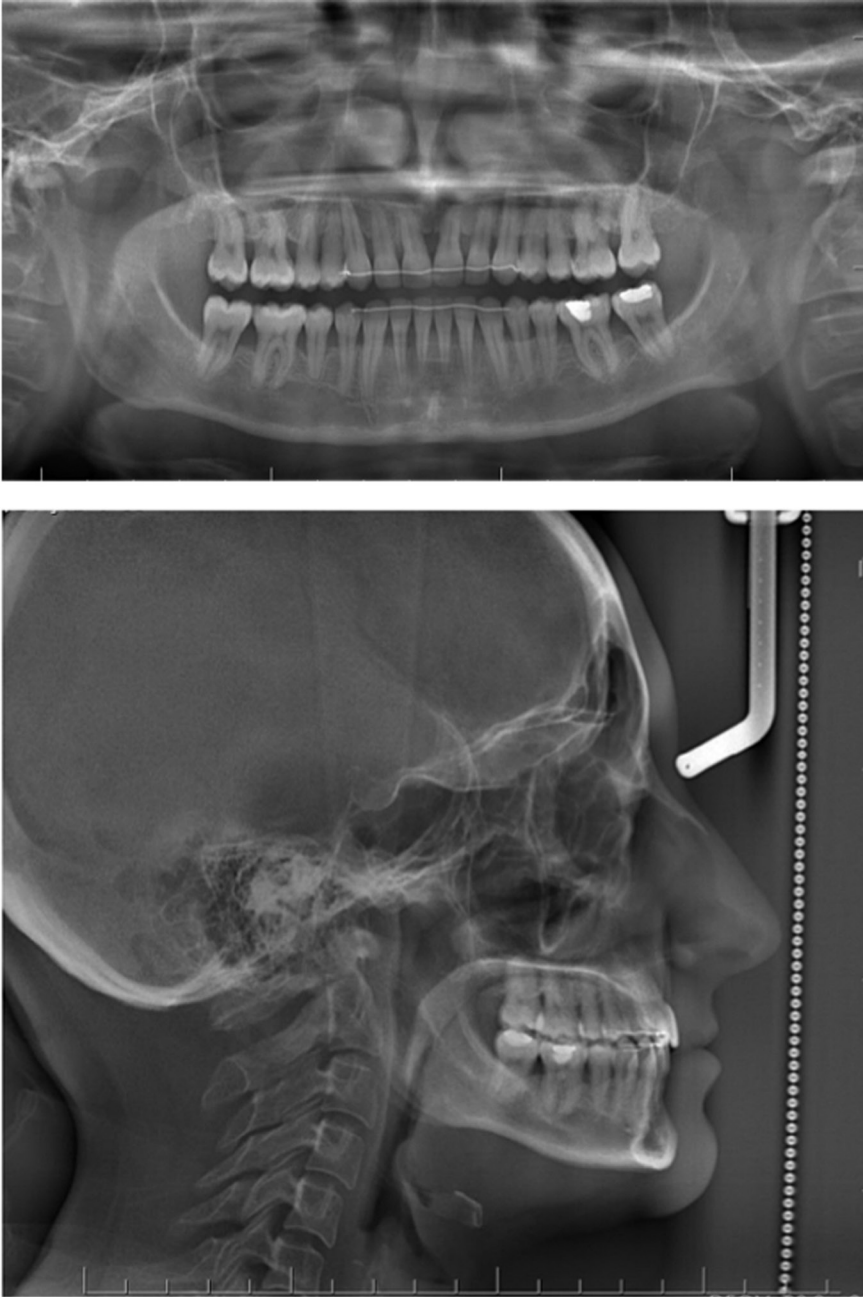


Figure 10. Panoramic X-ray and lateral cephalogram at 2-year follow-up.

fold. However, root resorption and gingival recession increase the likelihood of periodontal deterioration.<sup>24</sup> However, no significant root resorption was observed in the presented patient at the end of the treatment and during the 2-year follow-up period.

Orthodontic treatment can be destructive to the tissues if conducted during active periodontal disease. Nevertheless, Carvalho et al.<sup>15</sup> stated that orthodontic treatment does not cause periodontal attachment loss even in patients with aggressive periodontitis. No

additional bone loss during or after the orthodontic treatment of the present patient was observed which is likely attributed to the comprehensive periodontal treatment, the maintenance of appropriate oral hygiene, regular maintenance, and the utilisation of light orthodontic forces.

Orthodontic treatment time has been found to take longer in patients with advanced periodontal disease compared with healthy patients.<sup>15</sup> In the treatment of the present case, the correction of the transposed

teeth, the camouflage treatment of the skeletal Class III relationship, the elimination of the anterior crossbite and the extensive attachment loss were factors that increased the complexity of the treatment. It is important to consider that the centre of resistance of a tooth moves apically in patients with periodontal attachment loss. The teeth then have an increased tendency to experience uncontrolled movements.<sup>25</sup> In addition, the remodelling of periodontal tissues which is essential for orthodontic tooth movement takes longer in patients with periodontal problems compared with healthy patients.<sup>26</sup> Therefore, the interval between orthodontic force activation visits should be extended in these patients.

## Conclusion

The management of severe orthodontic-periodontal problems can be successfully achieved by oral health motivation, an interdisciplinary approach and the selection of appropriate biomechanics. Severe malocclusions maybe treated by allowing the periodontal tissues to remodel after comprehensive periodontal treatment and by closely monitoring their status to avoid an exacerbation of periodontal disease.

## Corresponding author

Sinem İnce-Bingöl  
Department of Orthodontics  
Faculty of Dentistry  
Baskent University, 1. Cad No: 107, 06490  
Bahcelievler-Ankara, Turkey  
E-mail: hsinemince@gmail.com

## Conflict of Interest

The authors received no financial support for the research and/or authorship of this article. The authors declared no conflict of interest with respect to the authorship and/or publication of this article.

## References

- Zhang J, Zhang AM, Zhang ZM, Jia JL, Sui XX, Yu LR. Efficacy of combined orthodontic-periodontic treatment for patients with periodontitis and its effect on inflammatory cytokines: a comparative study. *Am J Orthod Dentofac Orthop* 2017;152:494–500.
- Peck S, Peck L. Classification of maxillary tooth transpositions. *Am J Orthod Dentofac Orthop* 1995;107:505–17.
- Armitage GC. Development of a classification system for periodontal diseases and conditions. *Ann Periodontol* 1999;4:1–6.
- Nibali L, Donos N, Brett PM, Parkar M, Ellinas T, Llorente M. A familial analysis of aggressive periodontitis – clinical and genetic findings. *J Periodontol Res* 2008;43:627–34.
- Kinane DF, Stathopoulou PG, Papapanou PN. Periodontal diseases. *Nat Rev Dis Primers* 2017;3:1–14.
- Thilander B. Infrabony pockets and reduced alveolar bone height in relation to orthodontic therapy. *Semin Orthod* 1996;2:55–61.
- Cardaropoli D, Gaveglia L. The influence of orthodontic movement on periodontal tissues level. *Semin Orthod* 2007;13:234–45.
- Stabholz A, Soskolne WA, Shapira L. Genetic and environmental risk factors for chronic periodontitis and aggressive periodontitis. *Periodontol* 2000 2010;53:138–53.
- Cobb CM. Non-surgical pocket therapy: mechanical. *Ann Periodontol* 1996;1:443–90.
- Herrera D, Sanz M, Jepsen S, Needleman I, Roldán S. A systematic review on the effect of systemic antimicrobials as an adjunct to scaling and root planing in periodontitis patients. *J Clin Periodontol* 2002;29(Suppl. 3):136–59.
- Haffajee AD, Socransky SS, Gunsolley JC. Systemic anti-infective periodontal therapy. A systematic review. *Ann Periodontol* 2003;8:115–81.
- Carvalho RPM, Mesquita JS, Bonomo A, Elsas PX, Colombo APV. Relationship of neutrophil phagocytosis and oxidative burst with the subgingival microbiota of generalized aggressive periodontitis. *Oral Microbiol Immunol* 2009;24:124–32.
- Guerrero A, Griffiths GS, Nibali L, Suvan J, Moles DR, Laurell L. Adjunctive benefits of systemic amoxicillin and metronidazole in non-surgical treatment of generalized aggressive periodontitis: a randomized placebo-controlled clinical trial. *J Clin Periodontol* 2005;32:1096–107.
- Xajigeorgiou C, Sakellari D, Slini T, Baka A, Konstantinidis A. Clinical and microbiological effects of different antimicrobials on generalized aggressive periodontitis. *J Clin Periodontol* 2006;33:254–64.
- Carvalho CV, Saraiva L, Bauer FPF, Kimura RY, Souto MLS, Bernardo CC. Orthodontic treatment in patients with aggressive periodontitis. *Am J Orthod Dentofac Orthop* 2018;153:550–7.
- Khorsand A, Paknejad M, Yaghoobee S, Ghahroudi AAR, Bashizadefakhar H, Khatami M. Periodontal parameters following orthodontic treatment in patients with aggressive periodontitis: a before-after clinical study. *Dent Res J (Isfahan)* 2013;10:744–51.
- Griffiths GS, Addy M. Effects of malalignment of teeth in the anterior segments on plaque accumulation. *J Clin Periodontol* 1981;8:481–90.
- Alexander AG, Tipnis AK. The effect of irregularity of teeth and the degree of overbite and overjet on the gingival health. A study of 400 subjects. *Br Dent J* 1970;128:539–44.
- Karkhanечи M, Chow D, Sipkin J, Sherman D, Boylan RJ, Norman RG. Periodontal status of adult patients treated with fixed buccal appliances and removable aligners over one year of active orthodontic therapy. *Angle Orthod* 2013;83:146–51.
- Ristic M, Svabic MV, Sasic M, Zelic O. Clinical and microbiological effects of fixed orthodontic appliances on periodontal tissues in adolescents. *Orthod Craniofac Res* 2007;10:187–95.
- Castellanos-Cosano L, Machuca-Portillo G, Mendoza-Mendoza A, Iglesias-Linares A, Soto-Pineda L, Solano-Reina E. Integrated periodontal, orthodontic, and prosthodontic treatment in a case of severe generalized aggressive periodontitis. *Quintessence Int* 2013;44:481–5.
- Nishimura K, Nakao K, Aoki T, Fuyamada M, Saito K, Goto S. Orthodontic correction of a transposed maxillary canine and first premolar in the permanent dentition. *Am J Orthod Dentofac Orthop* 2012;142:524–33.

23. Hwang S, Kim I, Jang W, Choi YJ, Chung CJ, Kim KH. A 15-year follow up of an orthodontic treatment including a lower incisor extraction and keeping the maxillary canine-premolar transposition. *Angle Orthod* 2019;89:812–26.
24. Lorente C, Lorente P, Perez-Vela M, Esquinas C, Lorente T. Orthodontic management of a complete and an incomplete maxillary canine-first premolar transposition. *Angle Orthod* 2020;90:457–66.
25. Gkantidis N, Christou P, Topouzelis N. The orthodontic-periodontic interrelationship in integrated treatment challenges: a systematic review. *J Oral Rehabil* 2010;37:377–90.
26. Boyd RL, Leggott PJ, Quinn RS, Eakle WS, Chambers D. Periodontal implications of orthodontic treatment in adults with reduced or normal periodontal tissues versus those of adolescents. *Am J Orthod Dentofac Orthop* 1989;96:191–8.