

# The effect of third molars on maxillary molar distalisation using a miniscrew-supported 3D<sup>®</sup> maxillary bimetric distalising arch

Nilüfer İrem Tunçer and Ayça Arman-Özçırpıcı

Faculty of Dentistry, Department of Orthodontics, Başkent University, Ankara, Turkey

*Objectives:* The aim of the present study was to investigate the effect of third molars on the efficiency and biomechanics of a novel miniscrew-supported 3D<sup>®</sup> Maxillary Bimetric Distalising Arch (3D-MBDA).

*Methods:* Twenty-three patients, whose third molars were either extracted at the beginning of treatment (Group 1,  $n=11$ ) or retained (Group 2,  $n=12$ ), were included in the study. Lateral cephalometric films and dental casts, taken at the beginning (T0) and at the end of upper molar distalisation (T1), were analysed to study the differences between groups.

*Results:* Crown distalisation of the first molars was similar between the groups; however, root distalisation, both at the trifurcation and apex levels, intrusion at the mesiobuccal cusp tip, and the distalisation rate were significantly higher in Group 1. The resultant tipping of the first molars in both groups was mesially-directed, unlike the usual distal tipping. The second molars distalised more, displaced less vestibularly and rotated mesiobuccally in Group 1, whereas they demonstrated a significantly higher vestibular displacement and distobuccal rotation in Group 2. The mean distalisation time was significantly shorter in Group 1 when compared to Group 2. The miniscrew success rate was 95.5% for Group 1 and 91.7% for Group 2.

*Conclusion:* The miniscrew-supported 3D-MBDA was found to have greater effects on root distalisation and the final inclination of the molars. The third molars were associated with limited root movement, unfavourable displacement of the second molars, as well as a slower distalisation rate. Therefore, the extraction of third molars prior to distalisation is recommended, especially when the miniscrew-supported 3D-MBDA is the appliance choice.

(Aust Orthod J 2022; 38: 319 - 328. DOI: 10.2478/aoj-2022-033)

Received for publication: May, 2022

Accepted: September 2022.

Nilüfer İrem Tunçer: iremtuncher@gmail.com; Ayça Arman-Özçırpıcı: ayca@baskent.edu.tr

## Introduction

Maxillary molar distalisation has proven to be an effective treatment approach in the correction of a Class II malocclusion. There is a great variety of appliances that may be employed, from cervical head-gear to skeletonised intraoral distalisers, aiming for an efficient and rapid distalisation sequence with a minimal risk of relapse and side-effects.<sup>1-4</sup> Cervical head-gear clinically generates a substantial amount of distalising force with very few side-effects; however, it is aesthetically challenging and relies on patient

compliance.<sup>5,6</sup> Intraoral distalisers have the advantage of high aesthetic acceptability, but the conventional devices fail to meet the anchorage demand and produce unwanted tooth movement.<sup>2,7</sup> For almost two decades, temporary skeletal anchorage devices (TSADs) have served to overcome the shortcomings of conventional intraoral distalisers. TSADs may be inserted into the palate, buccal interradicular areas or the infrazygomatic crest. TSAD-supported palatal distalisers have the advantage of being distant to tooth roots and sited in an adequate quantity and quality of bone with sufficient keratinised soft

tissue.<sup>8,9</sup> However, there are disadvantages regarding applied force vectors and the complex placement and removal procedures.<sup>10</sup> Buccal distalisers supported by interradicular TSADs can usually be placed during the same session when the TSADs are inserted, have a de-rotating effect on the mesially-drifted molars, and are easy to place. However, interradicular TSADs have a higher risk of root injury and provide a limited range of tooth movement.<sup>11,12</sup> Lastly, the infrazygomatic TSADs do not interfere with tooth movement but inserted miniplates require surgical placement and removal, thereby increasing postoperative discomfort and treatment costs.

A 3D<sup>®</sup> Maxillary Bimetric Distalising Arch (3D-MBDA) was introduced in the late 1970s by Wilson.<sup>13,14</sup> The appliance is applied from the buccal aspect and consists of a bi-dimensional arch with distal omega loops and hooks for elastic use. The distal ends of the arch are inserted into the head-gear tubes of the first molar bands and compressed open coil-springs, placed between the omega-loops and head-gear tubes, generate the distalising force. The anterior part of the arch is tied to the maxillary incisors for stability. The system is patient-compliant but requires the use of Class II elastics in order to convey the distalising force onto the molars. Furthermore, the system is useful in correcting the rotation of mesially-drifted molars via the applied buccal forces.<sup>13-17</sup> The shortcoming of the appliance is unwanted mandibular molar mesialisation and mandibular incisor proclination as a result of Class II elastic use.<sup>15,18-21</sup> In order to overcome the side-effects and eliminate the dependency on Class II elastics, the present study used a modified version of the conventional 3D-MBDA by integrating TSADs into the system.

The benefits of extracting the third molars prior to maxillary molar distalisation remains a controversial issue. Kinzinger et al.<sup>22</sup> strongly recommended third molar extraction at the beginning of treatment to limit the distal tipping of the first molars. A recent study, conducted on adolescents, demonstrated that the eruption pattern of the third molars in the short-term changed from downward-forward to upward-backward after maxillary molar distalisation using a modified C-palatal plate. It was concluded that it may still be possible to carry out distalisation without third molar germectomy.<sup>23</sup> However, De-la-Rosa-Gay et al.<sup>24</sup> determined that the chance of successful eruption of the third molars decreased as the tooth's

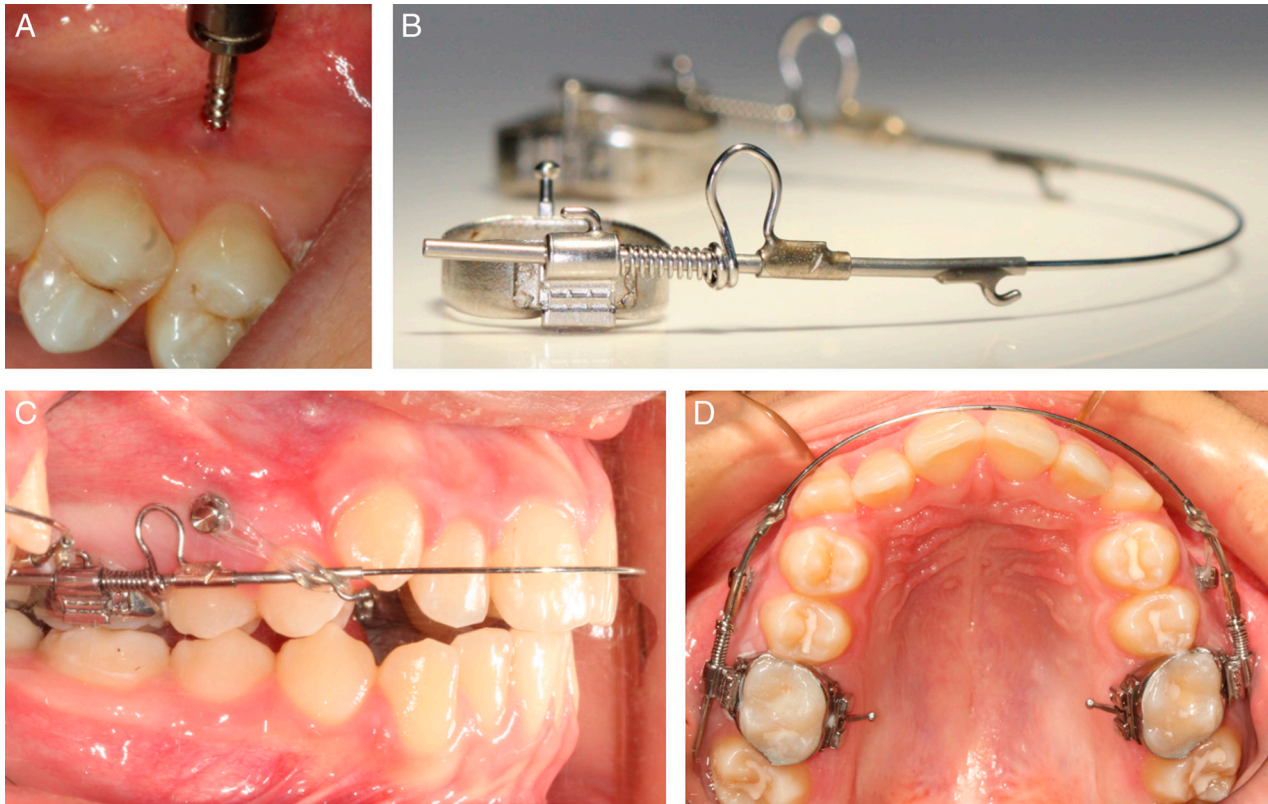
developmental stage increased with age. The rationale behind prior extraction of the third molars was to maximise the efficiency of the distalisation, and minimise relapse by creating an environment in which molars may be bodily distalised, because distally-tipped molars have been shown to upright after the distalisation forces have been discontinued which leads to a loss of achieved distal movement.<sup>25-29</sup>

As the effect of third molars on maxillary molar distalisation in adult patients seeking orthodontic treatment is seldom studied, it remains unclear whether the extraction of the third molars prior to distalisation provides a significant advantage. Therefore, the aim of the present study was to investigate the impact of the third molars on the efficiency and biomechanics of a novel miniscrew-supported 3D-MBDA, and to determine whether it is necessary to extract these teeth at the beginning of treatment. It is considered that this will be the first study to document the dental and skeletal effects of a miniscrew-supported version of 3D-MBDA in a relatively large group of patients.

## Subjects and methods

The present study was approved by the Institutional Review Board of Başkent University (Project no: D-KA 21/27), and was conducted according to the Declaration of Helsinki in protecting the interests and rights of research participants. The inclusion criteria were; (1) at least half-cusp bilateral Class II molar relationship originating from the maxillary dental arch, (2) patients who were about to complete or have completed skeletal growth (above MP<sub>3U</sub> according to hand-and-wrist films,<sup>30</sup> and stage 5 according to the cervical vertebral maturation method<sup>31</sup>), (3) fully-erupted maxillary second molars in good occlusion, (4) no posterior crowding, and (5) no previous orthodontic treatment history. Records of 23 patients (19 females, 4 males) meeting the inclusion criteria were included in the study and were treated by the same investigator (N.İ.T.).

After explaining the treatment protocol to the patients, and to the parents if the patient was a minor, all were advised to have their third molars extracted before treatment, regardless of the eruption status (position, angulation and rotation). The patients and/or parents made the final decision and therefore provided consent, so that bias would not be



**Figure 1.** (A) Miniscrew insertion between first and second premolars (note proximity of the miniscrew to the second premolar root). (B) 3D<sup>®</sup> Maxillary Bimetric Distalizing Arch, 5-mm open Elgiloy coil-springs placed distal to the omega-loops, and molar bands with gingivally-placed headgear tubes (0.045-inch). (C) Activation of the open coil-springs with elastomeric chains. (D) Intraoral positioning of the 3D<sup>®</sup> Maxillary Bimetric Distalizing Arch from occlusal view.

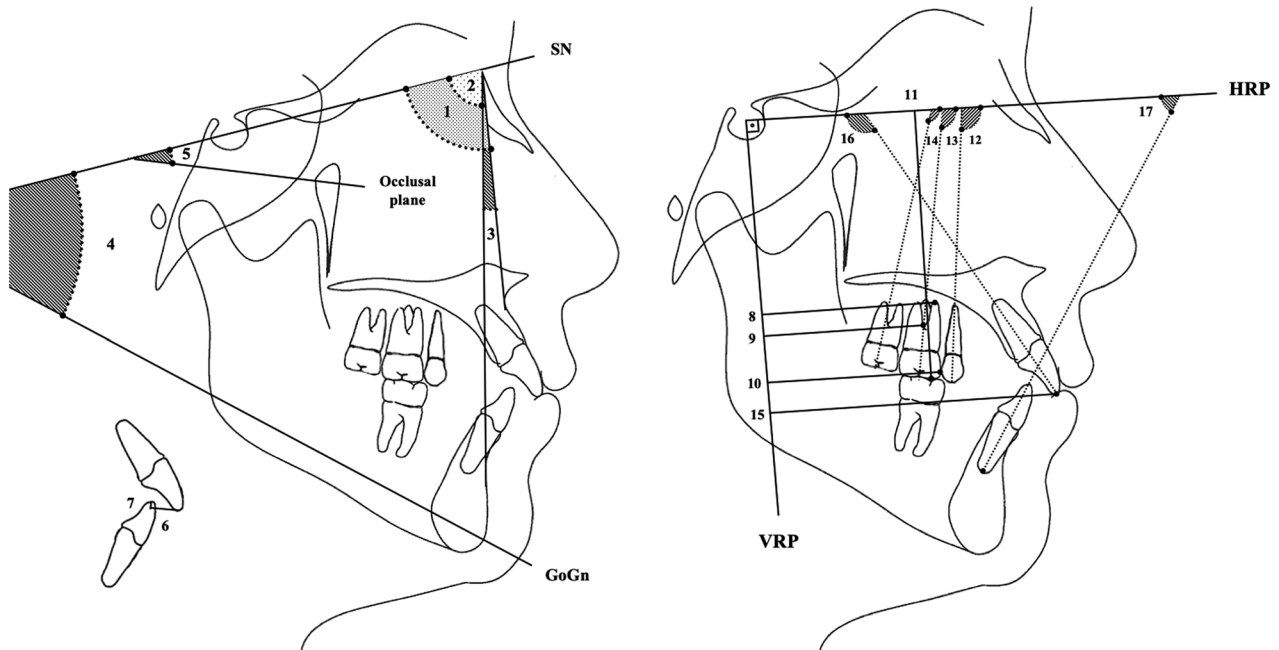
introduced to the research. Those patients who agreed to have the third molars extracted at the beginning of distalisation constituted Group 1 ( $n=11$ ), whereas those who refused extractions constituted Group 2 ( $n=12$ ).

Two miniscrews (ACR series, BioMaterials Korea, Seoul, Republic of Korea), of 1.5 mm diameter and 8 mm length, were placed perpendicular to the alveolar surface between the first and second premolar roots under local infiltration anesthesia. After cementing molar bands (Truform, RMO<sup>®</sup>, Colorado, USA) with gingivally-placed headgear tubes (0.045-inch) on the maxillary first molars, the appropriate size of 3D-MBDA (number 1-7, RMO<sup>®</sup>, Colorado, USA) was selected and 5 mm open Elgiloy coil-springs (RMO<sup>®</sup>, Colorado, USA) were placed distal to the omega loops. The free ends of the distalizing arch were inserted through the headgear tubes of the molar bands. Open coil-springs were activated (approximately 250 gm per side) using elastomeric

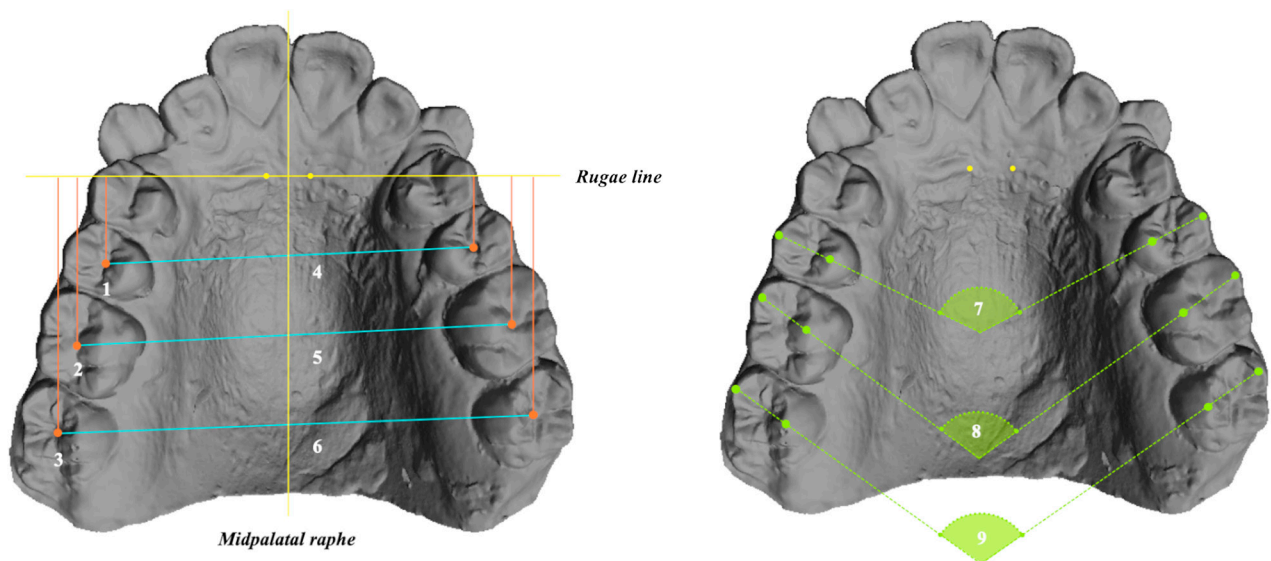
chains placed between the miniscrews and the hooks on the distalizing arch (approximately 150 gm per side) (Fig. 1). This modified tying system avoided the need to place brackets on the maxillary incisors and also the use of Class II elastics.

The distalisation mechanics were commenced after a minimum of two months of healing in Group 1, and soon after commencement of treatment in Group 2. Review appointments were arranged every 4 weeks to renew the elastomeric chains.

Start and end points of the observation period were set at the beginning of treatment (T0) and at the end of distalisation when a Class I molar relationship was achieved (T1). A total of 17 cephalometric (Fig. 2) and 9 dental cast (Fig. 3) variables were measured by the same investigator. Cephalometric films were traced and measured using Dolphin Imaging software (Patterson Dental, California, USA). The dental casts were scanned with an optical dental



**Figure 2.** Reference planes and cephalometric variables used in the study. *Reference planes:* SN (Sella–Nasion) plane; Occlusal plane, passing through mesiobuccal cusp tip of maxillary first molar and incisal edge of maxillary central incisor; GoGn (Gonion–Gnathion) plane; Horizontal reference plane (HRP), horizontal plane angulated 7° clockwise to the SN plane at Sella; Vertical reference plane (VRP), perpendicular plane to the HRP passing through Sella. *Cephalometric variables:* 1, SNA; 2, SNB; 3, ANB; 4, GoGn.SN; 5, Occ plane.SN; 6, Overjet; 7, Overbite; 8, U6root-VRP (perpendicular distance between mesiobuccal root apex of maxillary first molar and VRP); 9, U6trifurc.-VRP (perpendicular distance between trifurcation point of maxillary first molar roots and VRP); 10, U6M-VRP (perpendicular distance between mesial contact point of maxillary first molar crown and VRP); 11, U6 MB-HRP (perpendicular distance between mesiobuccal cusp tip of maxillary first molar and HRP); 12, U5.HRP; 13, U6.HRP; 14, U7.HRP; 15, U1i-VRP; 16, U1.HRP; 17, L1.HRP.



**Figure 3.** Reference planes and variables used in model analysis. *Reference planes:* Midpalatal raphe, the depression of the midpalatal suture; Rugae line, a perpendicular line to the midpalatal raphe passing through the same rugal points identifiable on both (T0&T1) dental casts. *Dental cast variables:* 1, U5-rugae line (distance between the central fossa of the second premolar and rugae line); 2, U6-rugae line (distance between the central fossa of the first molar and rugae line); 3, U7-rugae line (distance between the central fossa of the second molar and rugae line); 4, U5-U5 (inter-second premolar width); 5, U6-U6 (inter-first molar width); 6, U7-U7 (inter-second molar width); 7, U5.U5 (angle formed between the mesiodistal axes of the second premolars); 8, U6.U6 (angle formed between the mesiodistal axes of the first molars); 9, U7.U7 (angle formed between the mesiodistal axes of the second molars).

**Table I.** Demographic characteristics of patients in the treatment groups.

	Group 1 (Third molars extracted) (n=11)		Group 2 (Third molars present) (n=12)		<i>p</i>
	Mean (min-max) or <i>n</i>	SD	Mean (min-max) or <i>n</i>	SD	
Age (years)	15.7	2.8	15.7	1.7	0.567
	(13.4-21.2)		(13.7-18.9)		
Sex					
Female	9		10		0.876
Male	2		2		
Anteroposterior discrepancy					
1/4-cusp	0		0		0.789
1/2-cusp	6		7		
3/4-cusp	2		3		
full-cusp	3		2		

SD, standard deviation.

scanner (Neway + Dental Scanner, Open Tech 3D, Brescia, Italy) and analysed using MeshLab software (CNR, Rome, Italy). The amount of distalisation assessed on dental casts (U5/U6/U7-rugae line) was measured for the right and left sides, and mean values were taken for data analysis.

### Statistical analysis

Statistical analyses were performed using the SPSS software package (SPSS for Windows 22.0, SPSS Inc, Illinois, USA). The Shapiro–Wilk test was applied to test the normality of distribution. The Mann-Whitney U and Wilcoxon signed rank tests were used to compare differences between and within groups, respectively. The Chi-square test was used to examine the relationship between categorical variables. The level of significance was set at  $p < 0.05$ .

Two weeks after the initial data assessment, five randomly chosen patients from each group were re-assessed by the same investigator (N.I.T.) to test intra-examiner reliability.

### Results

Intraclass correlation coefficients, to assess the reliability of measurements, ranged between 0.923

and 0.999. A post-hoc power analysis conducted by using the differential of U6.HRP (°) between T0 and T1 produced a power of 86.5%.

The demographic characteristics of the groups at the beginning of distalisation are provided in Table I. The mean ages, the distribution of genders and anteroposterior discrepancies were found to be similar between the groups. Baseline characteristics were also similar, except for the U7-rugae line, which was reduced in Group 1 ( $p=0.041$ ) (Table II).

The changes achieved following distalisation within and between the groups are summarised in Table II. An outstanding finding of the present study was the mesially-directed tipping pattern of the molars, unlike the usual distal tipping, which was significantly greater in Group 1 (Fig. 4).

The amount of distalisation of the first molar crowns (U6M-VRP) was similar between the groups, yet the amount of root distalisation at the trifurcation and apex levels was significantly greater in Group 1. The mesiobuccal cusp tips of the first molars (U6MB-HRP) intruded significantly more in Group 1 and, as a result, posterior rotation of the occlusal plane (Occ Plane.SN) was more pronounced in this group (Fig. 4, Table II).

The mean distalisation time for Group 1 ( $12.3 \pm 1$  months) was significantly shorter than for Group

**Table II.** Comparison of cephalometric and model measurements at the beginning of distalization (T0) and changes achieved with distalization (T1-T0).

	Group 1 (Third molars extracted)				Group 2 (Third molars present)				
	T0		Changes		T0		Changes		
	Mean ± SD	Mean ± SD	p		Mean ± SD	Mean ± SD	p		
						Comparison at T0 p		Comparison of changes p	
<b>Skeletal</b>									
SNA (°)	80.7 ± 2.6	-1.1 ± 2.3	0.214		81.8 ± 2.9	-1.3 ± 2.8	0.292	0.391	0.066
SNB (°)	74.9 ± 2.6	1.1 ± 1.5	0.396		75.8 ± 3.4	0.9 ± 1.5	0.721	0.369	0.437
ANB (°)	5.8 ± 1.9	-0.5 ± 1.6	0.678		6 ± 3	0.9 ± 1.5	0.357	0.806	0.413
GoGn . SN (°)	30.1 ± 4.1	-1.2 ± 1.5	0.678		33.3 ± 6.7	-0.8 ± 1.2	0.541	0.307	0.967
<b>Dental - Model</b>									
U5 - rugae line (mm)	6.1 ± 2.9	3.2 ± 2.1	0.008*		8.2 ± 2.7	3.6 ± 1.9	0.005*	0.142	0.514
U6 - rugae line (mm)	15.3 ± 3	4.5 ± 1.8	0.008*		17.3 ± 2.6	3.9 ± 1.7	0.005*	0.102	0.191
U7 - rugae line (mm)	25.7 ± 3.3	4.8 ± 1.9	0.008*		28.3 ± 2.5	3.6 ± 2.3	0.005*	0.041*	0.027*
U5 - U5 (mm)	43.1 ± 3.6	1.8 ± 2.1	0.008*		43.9 ± 4.3	2.1 ± 3.9	0.005*	0.288	0.514
U6 - U6 (mm)	41.8 ± 4.1	-0.2 ± 1.6	0.859		42.8 ± 2.7	0.6 ± 1.6	0.333	0.327	0.369
U7 - U7 (mm)	47.2 ± 3.1	1.9 ± 3.7	0.008*		48.6 ± 3.6	7.2 ± 4.9	0.005*	0.369	0.014*
U5 . U5 (°)	137.9 ± 11.4	10.5 ± 6	0.008*		135.8 ± 10.3	6.7 ± 6.9	0.032*	0.935	0.051
U6 . U6 (°)	119 ± 9.3	-2.5 ± 7.5	0.314		121.9 ± 10	-2.7 ± 5.1	0.169	0.462	0.838
U7 . U7 (°)	120 ± 6.4	3.7 ± 4.7	0.028*		119.6 ± 11.9	-6.2 ± 8.7	0.241	0.935	0.027*

Table II. (Continued).

	Group 1 (Third molars extracted)				Group 2 (Third molars present)			
	T0		Changes		T0		Changes	
	Mean ± SD	Mean ± SD	p		Mean ± SD	Mean ± SD	p	
Dental - Cephalometric								
U6M - VRP (mm)	41.2 ± 4.1	-3.9 ± 2.3	0.008*	39.3 ± 3	-3.4 ± 2.4	0.007*	0.414	0.178
U6rifurc. - VRP (mm)	37.6 ± 3.8	-4.5 ± 5.6	0.008*	36 ± 3.3	-3.5 ± 3.2	0.005*	0.514	0.022*
U6root - VRP (mm)	40.3 ± 3.7	-5.5 ± 4.3	0.008*	38.7 ± 3.7	-3.8 ± 5.4	0.005*	0.624	0.003*
U5 . HRP (°)	96.2 ± 3.6	7.6 ± 3.7	0.008*	96.8 ± 4.8	8.6 ± 3.1	0.005*	0.902	0.683
U6 . HRP (°)	98 ± 3.5	-7.7 ± 3.2	0.008*	100.9 ± 3.6	-3.9 ± 2.7	0.005*0.	0.102	0.001*
U7 . HRP (°)	108.4 ± 7.7	-4.1 ± 4.6	0.011*	113 ± 4.6	-1.1 ± 2.2	0.139	0.142	0.027*
U6 MB - HRP (mm)	64.2 ± 5.3	-1.9 ± 1.1	0.008*	59.9 ± 3.8	-1.1 ± 0.9	0.008*	0.079	0.005*
Occ Plane . SN (°)	18.3 ± 5	4.9 ± 3.7	0.008*	16.9 ± 4.2	2.2 ± 3.2	0.007*	0.462	0.001*
U1i - VRP (mm)	66.2 ± 7.8	-1.2 ± 1.6	0.008*	65.5 ± 4.6	-0.5 ± 2.7	0.038*	0.775	0.066
U1 . HRP (°)	108.9 ± 11	-2.1 ± 2.8	0.028*	108.5 ± 8.2	-3 ± 2.2	0.005*	0.568	0.221
L1 . HRP (°)	62.7 ± 5.8	0.9 ± 1.2	0.579	64.1 ± 4.3	0.7 ± 0.9	0.668	0.229	0.765
Overjet (mm)	5.8 ± 2.8	-1.4 ± 1.9	0.261	5.2 ± 1.9	-1.1 ± 1.9	0.553	0.624	0.178
Overbite (mm)	3.7 ± 1.7	-0.9 ± 1.2	0.859	3.2 ± 1.5	-1.5 ± 1.9	0.059	0.624	0.102

\*p &lt; 0.05; SD, standard deviation.

2 ( $15.3 \pm 1.9$  months) ( $p=0.003$ ). Furthermore, the distalisation rate was significantly higher in Group 1 ( $0.36 \pm 0.11$  mm/month) than in Group 2 ( $0.25 \pm 0.11$  mm/month) ( $p=0.034$ ) (Table II).

The second molar crowns distalised (U7-rugae line) significantly more while displacing significantly less towards the vestibule (U7-U7) in Group 1. The second molars rotated (U7.U7) mesiobuccally in Group 1, and mesiopalatally in Group 2 (Table II).

Both groups demonstrated significant retraction and retrusion of the maxillary incisors (U1.HRP and U1i-VRP), an increase in inter-second premolar (U5-U5) and inter-second molar widths (U7-U7), and a mesiobuccal rotation (U5.U5) and spontaneous distalisation of the second premolars (U5-rugae line). However, changes in skeletal parameters (ANB and GoGn.SN angles), mandibular incisor inclination (L1.HRP), overbite, overjet and inter-first molar width (U6-U6) were found to be insignificant (Table II).

The miniscrew success rate was 95.5% (1 failure out of 22) for Group 1 and 91.7% (2 failures out of 24) for Group 2.

## Discussion

The present study evaluated the effects of third molars on maxillary molar distalisation using miniscrew-supported 3D-MBDA. This was also the first study to report the efficiency and dentoskeletal effects of this new distalisation system, plus describing significant mesial molar tipping, unlike the usual and expected distal tipping. The results showed that third molars contributed to four distinct effect differences in the biomechanics of distalisation using the miniscrew-supported 3D-MBDA; (1) the amount of tipping and distalisation at the trifurcation and root apex levels of the first molars, (2) the rate of distalisation, (3) the movement pattern of the second molars in the sagittal and transverse planes, and (4) the amount of intrusion at the mesiobuccal cusp tip of the first molars.

The amount of distalisation at the crown level was similar between the groups; however, it was significantly greater at the trifurcation and apex levels in Group 1, which resulted in more mesial tipping when compared to Group 2. These findings indicate that the third molars decrease the efficiency of molar distalisation possibly by limiting root movement. This is therefore considered a strong indicator for the prior extraction of these teeth, especially when miniscrew-supported 3D-MBDA is the appliance of choice. In line with the current findings, Kinzinger et al.<sup>22</sup> showed that molars could be distalised almost bodily after germectomy of the third molars, and strongly recommended their extraction before distalisation.

The second molars tipped more mesially with a mild amount of vestibular movement and mesiobuccal rotation when the third molars were extracted prior to distalisation. However, when the third molars were present during distalisation, the second molars moved even more towards the vestibule and rotated mesiopalatally which worsened the Class II discrepancy.<sup>14</sup> The vestibular displacement of the second molars, as if they were being “squeezed-out” of the dental arch, may be a mechanism which compensates for their inability to move and leads to an increased tendency towards a scissors bite and a subsequent unstable occlusion.

The intrusion of the mesiobuccal cusp tip of the first molars was another controversial, yet desired effect of the miniscrew-supported 3D-MBDA which was more pronounced when third molars were extracted. As can be inferred from GoGn.SN and ANB angles,

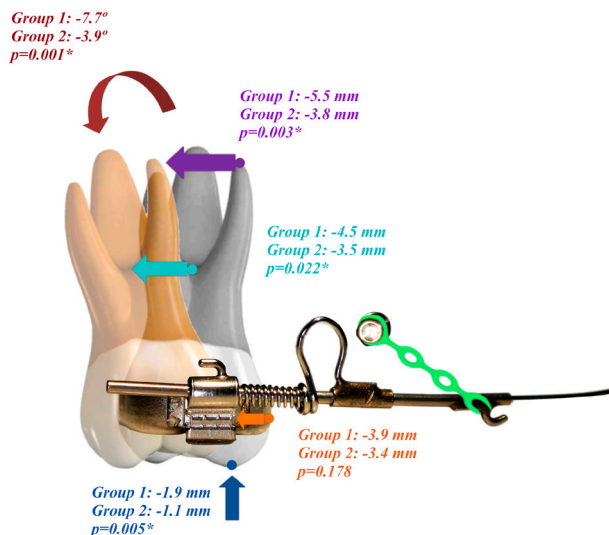


Figure 4. Comparison of first molar movements between groups. Colored arrows represent the following; red, U6.HRP (amount and direction of tipping); purple, U6root-VRP (amount of root distalization at apex level); turquoise, U6trifurc.-VRP (amount of root distalization at trifurcation level); orange, U6M-VRP (amount of crown distalization at mesial contact point); blue, U6MB-HRP (amount of intrusion at mesiobuccal cusp tip).



the distalisation of the maxillary dental arch was successfully carried out without increasing vertical dimensions.

The miniscrew-supported 3D-MBDA is a recently introduced distalisation system and, to the best of current knowledge, this is the first study to document its effects. The present results showed that maxillary molar roots distalised further than the crowns, which can be explained by the force vectors and moments acting on the first molars in such a way that the elastomeric chains, applied from the hooks to the miniscrews, pull the anterior part of the distalising arch upward, and the free ends of the arch placed in the headgear tubes, force the molar crowns to tip mesially. However, as a result of the continuous distalising forces exerted by the coil-springs, the crowns do not move forward, but the roots tip distally instead, followed by uprighting of the crowns. This shows that molar distalisation is a sequence of tipping and uprighting. When the present results are compared to those of previous distalisation studies using temporary anchorage devices, the amount of molar tipping was found to be greater than alternative buccally- ( $1.70^{\circ}$ – $3.99^{\circ}$ ) and palatally-supported ( $-1.20^{\circ}$ – $-11.24^{\circ}$ ) distalisation systems.<sup>32</sup> The amount of molar distalisation was greater than buccal distalisation using interradicular miniscrews (2.75 mm), and similar to that reported by buccal distalisation using infrazygomatic screws/plates (4.07 mm) and palatal distalisation (4.17 mm) procedures.<sup>32</sup> Based upon these findings, it may be concluded that the new system is capable of distalising the maxillary molars in similar amounts compared with other skeletally-anchored distalisation systems; however, with a more favourable tipping pattern.

During distalisation using the conventional 3D-MBDA, the arch is tied to the incisor brackets and Class II elastics are applied to convey the distalising force to the maxillary molars while stabilising the arch. Although this design has been proven to be effective in correcting a Class II molar relationship, it relies heavily on Class II elastic use which may be associated with two side-effects. Firstly, the maxillary incisors are at risk of further proclination if the patient does not comply with elastic use, and secondly, Class II correction is a result of 50% maxillary molar distalisation and 40% mandibular molar mesialisation.<sup>18–21</sup> The addition of two miniscrews to the conventional system avoided the need for anterior brackets and Class II elastics. It further increased

the efficiency of the system while eliminating side-effects but decreased the distalisation rate. The rate of distalisation using the conventional 3D-MBDA was reported to be 0.56 mm/month and 1.11 mm/month by Muse et al.<sup>18</sup> and Altug-Atac et al.<sup>21</sup> respectively. The distalisation rate identified in the present study was found to be lower, which may be explained by the consecutive tipping and uprighting sequence taking more time than rapid distal-tipping observed in most of the other distalisation systems. Furthermore, Class II correction was achieved by only maxillary molar distalisation, instead of a combination of maxillary molar distalisation and mandibular molar mesialisation.

Miniscrews which loosened and needed replacement during distalisation were inserted nearby at a more apical position and at a lesser insertion angle. At the end of the distalisation period, the miniscrews were placed between first and second molar roots, and used to reinforce molar anchorage.

### **Limitations**

Studies conducted with statistically appropriate sample sizes provide the most reliable results. Although the sample size of the present study was small, a retrospective power determination was 86.5%, showing that the acquired results did not undermine the internal nor external validity of the study. Furthermore, blinding of the data assessor was not possible as the third molars were visible on the radiographs; however, the operator performing the clinical steps was blinded.

### **Conclusion**

The third molars were associated with less distal movement of the first and second molar roots, more vestibular displacement of the second molar crowns, and a longer treatment time during maxillary molar distalisation using the miniscrew-supported 3D® Maxillary Bimetric Distalising Arch. Based on the present results, the extraction of the third molars at the beginning of distalisation seems beneficial with regard to the distalisation rate and biomechanics of this new-system.

### **Conflict of interest**

The authors declare that there is no conflict of interest.

## Corresponding Author

Nilüfer İrem Tunçer, PhD, DDS  
Faculty of Dentistry,  
Department of Orthodontics,  
Başkent University, Ankara, Turkey  
Email: iremtuncher@gmail.com

## References

- Sfondrini MF, Cacciafesta V, Sfondrini G. Upper molar distalization: a critical analysis. *Orthod Craniofac Res* 2002;5:114–26.
- Kinzinger GS, Eren M, Diedrich PR. Treatment effects of intraoral appliances with conventional anchorage designs for non-compliance maxillary molar distalization: a literature review. *Eur J Orthod* 2008;30:558–71.
- Antonarakis GS, Kiliaridis S. Maxillary molar distalization with noncompliance intramaxillary appliances in Class II malocclusion. A systematic review. *Angle Orthod* 2008;78:1133–40.
- Mohamed RN, Basha S, Al-Thomali Y. Maxillary molar distalization with miniscrew-supported appliances in Class II malocclusion: a systematic review. *Angle Orthod* 2018;88:494–502.
- Egolf RJ, BeGole EA, Upshaw HS. Factors associated with orthodontic patient compliance with intraoral elastic and headgear wear. *Am J Orthod Dentofacial Orthop* 1990;97:336–48.
- King GJ, Keeling SD, Hocevar RA, Wheeler TT. The timing of treatment for Class II malocclusions in children: a literature review. *Angle Orthod* 1990;60:87–97.
- Fontana M, Cozzani M, Caprioglio A. Soft tissue, skeletal and dentoalveolar changes following conventional anchorage molar distalization therapy in class II non-growing subjects: a multicentric retrospective study. *Prog Orthod* 2012;13:30–41.
- Gracco A, Lombardo L, Cozzani M, Siciliani G. Quantitative cone-beam computed tomography evaluation of palatal bone thickness for orthodontic miniscrew placement. *Am J Orthod Dentofacial Orthop* 2008;134:361–9.
- Arqub SA, Gandhi V, Mehta S, Palo L, Upadhyay M, Yadav S. Survival estimates and risk factors for failure of palatal and buccal mini-implants. *Angle Orthod* 2021;91:756–63.
- Cambiano AO, Janson G, Fuziy A, Garib DG, Lorenzoni DC. Changes consequent to maxillary molar distalization with the bone-anchored pendulum appliance. *J Orthod Sci* 2017;6:141–6.
- Yamada K, Kuroda S, Deguchi T, Takano-Yamamoto T, Yamashiro T. Distal movement of maxillary molars using miniscrew anchorage in the buccal interradiacular region. *Angle Orthod* 2009;79:78–84.
- Bechtold TE, Kim JW, Choi TH, Park YC, Lee KJ. Distalization pattern of the maxillary arch depending on the number of orthodontic miniscrews. *Angle Orthod* 2013;83:266–73.
- Wilson WL. Modular orthodontic systems. Part 1. *J Clin Orthod* 1978;12:259–67; 270–278.
- Wilson WL. Modular orthodontic systems. Part 2. *J Clin Orthod* 1978;12:358–75.
- Wilson WL, Wilson RC. New treatment dimensions with first phase sectional and progressive edgewise mechanics. *J Clin Orthod* 1980;14:607–27.
- Wilson WL, Wilson RC. Modular 3D appliances. Problem solving in edgewise, straight wire and light wire treatment. *J Clin Orthod* 1984;8:272–81.
- Wilson WL, Wilson RC. Multidirectional 3D functional Class 2 treatment. *J Clin Orthod* 1987;21:186–9.
- Muse DS, Fillman MJ, Emmerson WJ, Mitchell RD. Molar and incisor changes with Wilson rapid molar distalization. *Am J Orthod Dentofacial Orthop* 1993;104:556–65.
- Uçem TT, Yüksel S, Okay C, Gülşen A. Effects of a three-dimensional bimetric maxillary distalizing arch. *Eur J Orthod* 2000;22:293–8.
- Okay C, Gülşen A, Keykubat A, Ucem TT, Yüksel S. A comparison of the effects of 2 mandibular anchorage systems used with a 3-dimensional bimetric maxillary distalizing arch. *World J Orthod* 2006;7:125–33.
- Altug-Atac AT, Erdem D, Arat ZM. Three-dimensional bimetric maxillary distalization arches compared with a modified Begg intraoral distalization system. *Eur J Orthod* 2008;30:73–9.
- Kinzinger GS, Fritz UB, Sander FG, Diedrich PR. Efficiency of a pendulum appliance for molar distalization related to second and third molar eruption stage. *Am J Orthod Dentofacial Orthod* 2004;125:8–23.
- Lee YJ, Kook YA, Park JH, Park J, Bayome M, Vaid NR, et al. Short-term cone-beam computed tomography evaluation of maxillary third molar changes after total arch distalization in adolescents. *Am J Orthod Dentofacial Orthod* 2019;155:191–7.
- De-la-Rosa-Gay C, Valmaseda-Castellón E, Gay-Escoda C. Spontaneous third-molar eruption after second-molar extraction in orthodontic patients. *Am J Orthod Dentofacial Orthod* 2006;129:337–44.
- Gianelly AA. Distal movement of the maxillary molars. *Am J Orthod Dentofacial Orthop* 1998;114:66–72.
- Rocha CA, de Almeida RR, Henriques JFC, Flores-Mir C, de Almeida MR. Evaluation of long-term stability of mesiodistal axial inclinations of maxillary molars through panoramic radiographs in subjects treated with pendulum appliance. *Dental Press J Orthod* 2016;21:67–74.
- Chiu P, McNamara JA, Franchi L. A comparison of two intraoral distalization appliances: distal jet versus pendulum. *Am J Orthod Dentofacial Orthop* 2005;128:353–65.
- Angelier F, de Almeida RR, de Almeida MR, Fuziy C. Dentoalveolar and skeletal changes associated with the pendulum appliance followed by fixed orthodontic treatment. *Am J Orthod Dentofacial Orthop* 2006;129:520–7.
- Caprioglio A, Fontana M, Longoni E, Cozzani M. Long-term evaluation of the molar movements following Pendulum and fixed appliances. *Angle Orthod* 2013;83:447–54.
- Fishman LS. Radiographic evaluation of skeletal maturation. A clinically oriented method based on hand-wrist films. *Angle Orthod* 1982;52:88–112.
- Baccetti T, Franchi L, McNamara JA Jr. An improved version of the cervical vertebral maturation (CVM) method for the assessment of mandibular growth. *Angle Orthod* 2002;72:316–23.
- Bayome M, Park JH, Bay C, Kook YA. Distalization of maxillary molars using temporary skeletal anchorage devices: A systematic review and meta-analysis. *Orthod Craniofac Res* 2021;24:103–12.