



## EDİTÖRE MEKTUP / LETTER TO THE EDITOR

### Combination of mesh repair techniques for the primary form of acquired petit hernia

Edinilmiş petit fıtığı birincil tipinde yama onarım tekniklerinin kombinasyonu

Alper Parlakgümüş<sup>1</sup>, Ali Ezer<sup>1</sup>

<sup>1</sup>Başkent Üniversitesi Adana Turgut Noyan Araştırma ve Uygulama Hastanesi, Genel Cerrahi Kliniği, Adana, Turkey

*Cukurova Medical Journal 2018;43(2):516-517*

Dear Editor,

Lumbar hernias are rather uncommon, and around 300 primary cases have been reported<sup>1</sup>. The most common site for the occurrence of lumbar hernias is in the superior lumbar triangle (Grynfeltt) and less commonly in the inferior lumbar triangle<sup>2</sup>. The inferior lumbar triangle (Petit) is bounded medially by the latissimus dorsi muscle, laterally by the external abdominal oblique muscle, and inferiorly by the iliac crest. The floor of the inferior lumbar triangle is formed by the internal abdominal oblique muscle. Petit described a strangulated hernia emerging from this triangle and then named by him<sup>3</sup>.

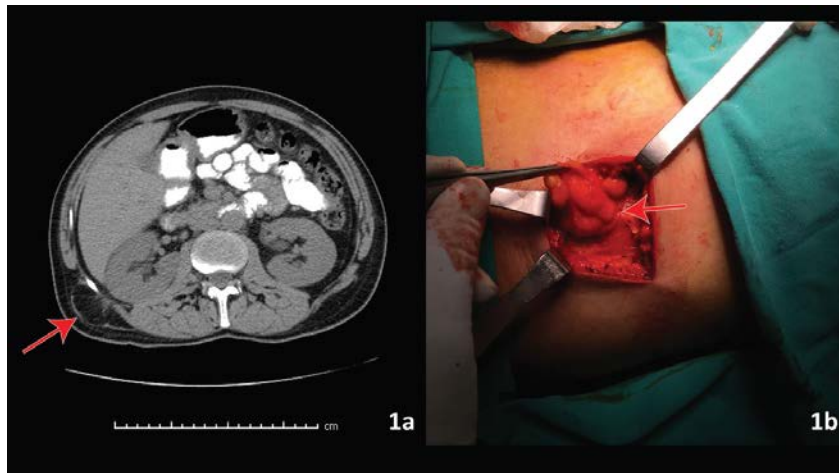
A 58-year-old male patient, known to have hypertension and epilepsy presented to our surgical polyclinic with a right sided flank swelling. There was no trauma in patient history. In the physical examination, swelling became more pronounced with coughing. A computed tomography (CT) scan of the lower chest and abdomen revealed a lumbar wall defect and a hernial sac (Figure 1a). He underwent repair on prone position. After dissection of muscle layers, hernia sac was found. The sac was excised and umbricated. The neck of hernia was 2 cm in diameter (Figure 1b). The defect was closed by Mesh-plug technic and a mesh was fixed with interrupted sutures covering the whole area between 12th rib and iliac crest. The other muscle layers were primarily closed. No drain was inserted in the subcutaneous tissue. The patient was discharged, with uneventful recovery in the second

post-operative day. There were no complications and recurrences in the first 6 month follow up.

Congenital lumbar hernia accounts for 20%, appears early in life, is rarely bilateral or associated with other congenital abnormalities while the acquired ones are subdivided into spontaneous or primary, and traumatic or secondary<sup>4</sup>. The primary form occurs in older age due to weakness in the abdominal muscles, while the secondary is caused by traumatic causes such as surgical incisions, flank or lumbar trauma, seat belt trauma, and retroperitoneal abscess or hematoma. Our case seems to be the primary form of acquired lumbar hernia.

Hernia defect size and the status of tissues around the defect determines the surgeons approach. Suturing the defect primarily with interrupted heavy non-absorbable sutures is one of the choices. For larger defects the use of tensor fascia lata rotational flaps or free fascial grafts are described. Actually, non-absorbable mesh is usually preferred for reconstruction: it can be placed as an onlay, inlay or underlay depending on the size of the defect, and it should cover the whole area between 12th rib and iliac crest. Laparoscopic repair can be either transabdominal or totally extraperitoneal with a plane between the transversalis muscle and peritoneum. Other possibilities include a mesh plug and a retroperitoneoscopic tension free mesh repair<sup>1</sup>. We used a combination of mesh plug with underlay mesh reconstruction for this type of rare case with no complications and recurrences in the first 6 month follow up.

Yazışma Adresi/Address for Correspondence: Dr. Alper Parlakgümüş, Başkent Üniversitesi Adana Turgut Noyan Araştırma ve Uygulama Hastanesi, Genel Cerrahi Kliniği, Adana, Turkey E-mail: aparlakgumus@yahoo.com  
Geliş tarihi/Received: 16.08.2017 Kabul tarihi/Accepted: 23.09.2017



**Figure 1a.** Abdominal CT findings showing herniated retroperitoneal fatty tissue from the defect of inferior lumbar triangle (red arrow) **1b.** Operative field of Petit hernia showing herniated retroperitoneal fatty tissue

## REFERENCES

1. Mismar A, Al-Ardah M, Albsoul N, Younes N. Underlay mesh repair for spontaneous lumbar hernia. *Int J Surg Case Rep.* 2013;4:534-6.
2. Wakhlu A, Wakhlu AK. Congenital lumbar hernia. *Pediatr Surg Int.* 2000;16:146-8.
3. Petit JL. *Traite Des Maladies Chirurgicales, et Des Operations Qui Leur Conviennent*, Vol. 2. Paris, TF Didot, 1774.
4. Swartz WT. Lumbar hernia. In: *Hernia*, 2<sup>nd</sup> edition (Eds LM LM, RE Condon):409-26. Philadelphia: Lippincott; 1978;409-26.