



Case Report

# Trocar site hernia on an 8-mm port following robotic-assisted hysterectomy

Gokhan Sami Kilic<sup>a</sup>, Tevfik Berk Bildaci<sup>b</sup>, Omer Lutfi Tapisiz<sup>a,\*</sup>, Ibrahim Alanbay<sup>c</sup>,  
Teresa Walsh<sup>a</sup>, Olga Swanson<sup>a</sup>

<sup>a</sup> Department of Obstetrics and Gynecology, University of Texas Medical Branch, Galveston, TX, USA

<sup>b</sup> Department of Obstetrics and Gynecology, Baskent University School of Medicine, Ankara, Turkey

<sup>c</sup> Gynecologic Oncology and Reproductive Medicine, University of Texas MD Anderson Cancer Center, Houston, TX, USA

Received July 31, 2012; accepted February 8, 2013

## Abstract

The increasing use of laparoscopy has resulted in added complications specific to the laparoscopic approach, such as trocar site hernia (TSH), which is an uncommon but well-recognized problem for both regular laparoscopic and robotic-assisted laparoscopic procedures. We describe an extremely rare case of TSH at an 8-mm port site occurring a relatively short time after surgery in a 53-year-old patient undergoing robotic-assisted laparoscopic hysterectomy for benign reasons. Additionally, this report attempts to explain the possible etiological factors relating to TSH following robotic-assisted surgery. According to our case report, a defect in the 8-mm port that may lead to hernia is one possible explanation, and closure of the 8-mm trocar sites' fascia may be a safer approach during robotic-assisted surgery. Additional reports are needed to accurately determine the frequency of occurrence and importance of this complication.

Copyright © 2013 Elsevier Taiwan LLC and the Chinese Medical Association. All rights reserved.

**Keywords:** complication; hernia; hysterectomy; robotic; trocar

## 1. Introduction

As the use of laparoscopy has expanded as a surgical option, this has resulted in added complications specific to the laparoscopic approach. One of these noted complications is trocar site hernia (TSH), a rare problem that can be encountered during both regular laparoscopic and robot-assisted laparoscopic procedures. TSH can be asymptomatic, but it occasionally presents with bowel obstruction, requiring emergency surgery.<sup>1</sup>

The incidence of an incisional hernia following an operative laparoscopic procedure increases with trocar size and is extremely unusual in ports less than 10 mm in diameter, ranging from 0% to 0.09%.<sup>2</sup> There are not enough data to establish the prevalence of TSH on robotic-assisted cases, which is an

emerging technology in the medical field. In the literature, we could find only two reports that involved TSH on an 8-mm port site following robotic-assisted surgery.<sup>3,4</sup> Here, we describe an extremely rare case of trocar site bowel herniation at an 8-mm port site, which occurred a relatively short time after a robotic-assisted laparoscopic total abdominal hysterectomy and bilateral salpingo-oophorectomy (RLTAH-BSO). Additionally, this report seeks to explain the possible etiological factors related to TSH following robotic-assisted surgery.

## 2. Case report

A 53-year-old G0P0 postmenopausal patient (body mass index, 30 kg/m<sup>2</sup>), with a history of endometrial ablation and lobular carcinoma *in situ* of the breast, for which she was still taking tamoxifen, presented with pelvic pain and a thickened endometrium with vaginal bleeding. Owing to a stenotic cervix, it was not possible to obtain an endometrial sampling. After discussing the risks, benefits, and alternatives, written consent was obtained from the patient for an examination under anesthesia

The authors declare that there are no conflicts of interest related to the subject matter or materials discussed in this article.

\* Corresponding author. Dr. Omer Lutfi Tapisiz, 1425, Cadde, Hayat Sebla Evleri, Number 74, Cukurambar, Ankara, Turkey.

E-mail address: [omertapisiz@yahoo.com.tr](mailto:omertapisiz@yahoo.com.tr) (O.L. Tapisiz).

and dilatation curetting, possible hysterectomy, and staging. Because attempts to dilate the cervix failed in the operating room, surgery continued with RLTAH-BSO as discussed previously with the patient. Following induction of general endotracheal anesthesia and after obtaining adequate pneumoperitoneum with a Veress needle, a 12-mm laparoscope with a trocar was placed under direct visualization with a bladeless trocar 4 cm over the umbilicus level on midline. Two 8-mm robotic ports on the left and right anterior axillary lines on the umbilicus level, and a 5-mm assistant port were then placed using laparoscopic visualization. An assistant arm was placed between the midline camera and the right robotic trocar port. After robot docking, an uncomplicated procedure was performed by the da Vinci Si Surgical System (Intuitive Surgical, Sunnydale, CA, USA), with an estimated blood loss of less than 50 mL. After undocking of the robot, the 12-mm port was removed under 5-mm laparoscopic visualization. The fascia of the 12-mm port was closed with 2–0 vicryl (Polyglactin 910, Synthetic Absorbable Suture, Ethicon, Inc., Somerville, NJ, USA) using a Carter-Thompson suture passer (Carter-Thompson, CloseSure System; CooperSurgical, Trumbull, CT, USA). A 5-mm scope was introduced from the laparoscopic 5-mm assistant arm. Both robotic trocars were removed from the abdomen under direct visualization. CO<sub>2</sub> was allowed to deflate from the abdomen, and the scope was removed at the end of the procedure along with the 5-mm assistant trocar. The fasciae of the 8-mm and 5-mm port sites were not closed. The skin incisions were closed with 2–0 Monocryl (Poliglecaprone 25, Ethicon, Inc., Somerville, NJ, USA). The patient was discharged in good health the following morning (postoperative Day 1) after tolerating a regular diet and passing gas.

The patient returned to the emergency room for reevaluation complaining of right lower quadrant pain and dark coffee-colored vomitus on postoperative Day 3. There was a moderately sized, tender nodule in the right lower quadrant (Fig. 1). On readmission, her vital signs were stable, and a complete blood count showed a leukocyte count of  $11.7 \times 10^3/\text{mL}$ . Computed tomography of the abdomen and pelvis with and without intravenous contrast demonstrated a small bowel obstruction due to a ventral herniation of the small bowel through a defect of the internal and external oblique fascia and peritoneum at the right anterior axillary 8-mm port site (Fig. 2). Laparoscopic bowel reduction and hernia repair were performed immediately. The fascia was closed with 2–0 vicryl (Polyglactin 910, Synthetic Absorbable Suture, Ethicon, Inc., Somerville, NJ, USA) using a Carter-Thompson suture passer (Carter-Thompson, CloseSure System; CooperSurgical, Trumbull, CT, USA). The bowel was seen as viable but bruised, and not dusky (Fig. 3). Following reduction, perfusion returned, and natural color resumed at the end of the case with evidence of peristalsis within the segment. The patient was discharged on postoperative Day 1 (4 days after the initial surgery) with good oral intake and a functional bowel.

### 3. Discussion

Although the noted incidence of hernia through port sites 10 mm and larger has increased to 1%, the occurrence of

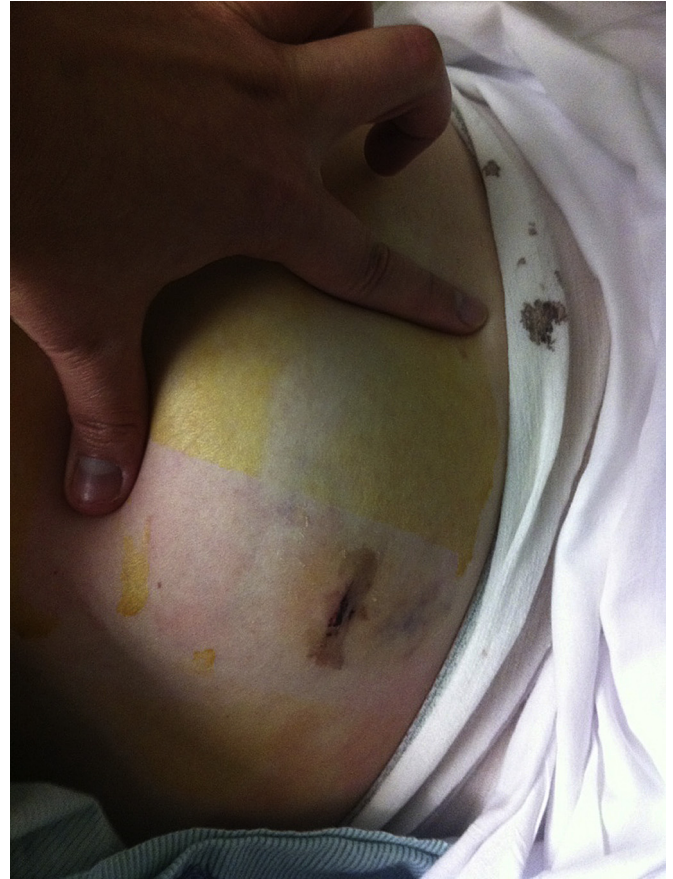


Fig. 1. Distended abdomen, tense/hard in right lower quadrant (RLQ) and with nodular mass noted on her initial physical examination.

hernia in smaller trocar sites, such as 5 mm and 8 mm, is difficult to estimate because it is rarely reported. One TSH review found that the incidence of bowel herniation through ports smaller than 10 mm is up to 0.09%.<sup>2</sup>

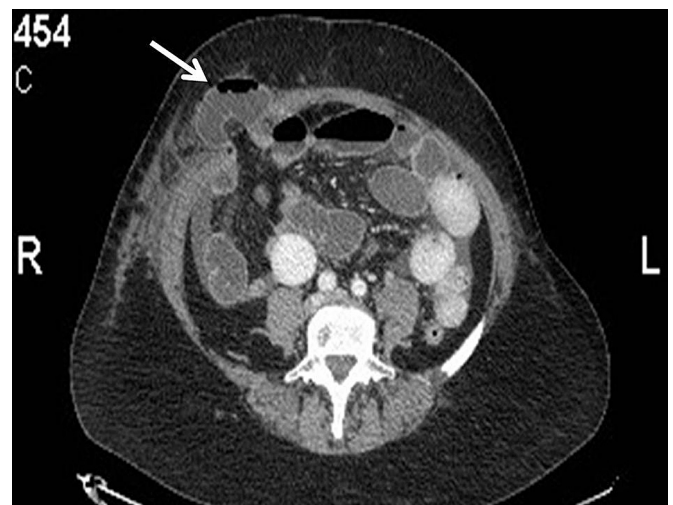


Fig. 2. CAT scan image of bowel hernia on 8-mm RLQ trocar site. Herniated bowel segment through peritoneum and internal and external fascia shown with white arrow. CAT = computer axial tomography; RLQ = right lower quadrant.

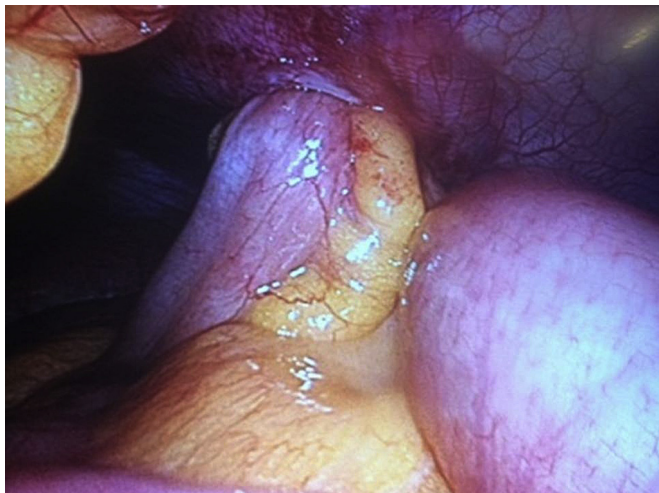

Fig. 3. Laparoscopic view of bowel herniation penetrating peritoneal layer at the time of correction surgery.

Owing to design differences, the 8-mm cannulas used during robotic surgery produce a more pronounced defect in the fascia than those used for traditional laparoscopy. Surgeons who regularly perform these minimally invasive procedures generally do not attempt to close the fascia of ports less than 10 mm, including the 8-mm robotic ports, because of the technical difficulties associated with closing smaller port fasciae.<sup>3</sup>

Multiple causes of fascial defects and herniation have been identified as laparoscopic techniques have evolved. Diameter and design of the trocar, direction of port insertion, use of drains, preexisting fascial defects, and some operation-associated or patient-related characteristics are risk factors for TSH.<sup>5</sup> Port-site incisions may be stretched during surgery because of extensive manipulation of the trocar, resulting in an incision larger than originally intended.<sup>6</sup> Nezhath et al<sup>2</sup> reported TSHs following excessive manipulation of 5-mm operative port sites during laparoscopic surgery. Our observation indicates that the robot itself and its mechanical design can impose excessive force on tissue, and this can be one of the reasons for TSH.

Data about TSH at 8-mm port sites are not clear enough to determine whether closure of the fascia is necessary. A PubMed literature search from 2002 until January 2012 using the terms “robot”, “hernia”, “trocar site” and “complications” found only two previously reported cases of TSH on 8-mm ports following robotic-assisted procedures. In a series of 100 patients who had undergone robotic-assisted laparoscopic prostatectomy performed by Spaliviero et al,<sup>4</sup> with closure of only one periumbilical defect that was enlarged for specimen

retrieval, they had one patient return with an 8-mm TSH. Seamon et al<sup>3</sup> reported a 67-year-old woman with a TSH on an 8-mm port and evisceration following an endometrial carcinoma staging operation. With increased surgical time for robotic-assisted procedures (as in surgery for malignant disorders), we think TSH is more likely to develop because of the increased force applied to the fascia during the longer surgical time, although TSH can also happen after a relatively short procedure as in our benign hysterectomy case. However, it would appear that our patient is the first case of 8-mm TSH reported following surgery for benign gynecological disorder.

Facilitating factors for robotic port hernia mainly fall into three possible etiologic factors. First, robotic trocars are designed for placement with sharp cutting technology instead of a laparoscopically rotating motion. Consequently, this leads to a bigger incision in the fascia. Second, robotic arms exert increased pressure and have a higher rotating capacity than the usual hand motion, which may also enlarge the fascial incision. Last, robotic arms are inserted more laterally than the usual laparoscopic trocar placement, especially in thin patients, to be compliant with the 10-cm rule (each trocar is recommended to be 10 cm away from other trocars to prevent robotic arm collision). This ultimately pushes the robotic trocar to be placed where the abdominal fascia becomes weaker.

Our preliminary data on robotic-assisted gynecological operations revealed that we had only one patient with TSH out of 125 patients (0.8%). Statistically, robotic 8-mm port hernia risk is minimal. Because the medical data are limited on this issue, we adapted the protocol that 8-mm port incisions are to be treated as defects of >10 mm, and closed in a similar manner. Further reports are needed to accurately determine the occurrence and the importance of this complication.

## References

- Swank HA, Mulder IM, la Chapelle CF, Reitsma JB, Lange JF, Bemelman WA. Systematic review of trocar-site hernia. *Br J Surg* 2012;**99**:315–23.
- Nezhath C, Nezhath F, Seidman DS, Nezhath C. Incisional hernias after operative laparoscopy. *J Laparoendosc Adv Surg Tech A* 1997;**7**:111–5.
- Seamon LG, Backes F, Resnick K, Cohn DE. Robotic trocar site small bowel evisceration after gynecologic cancer surgery. *Obstet Gynecol* 2008;**112**:462–4.
- Spaliviero M, Samara EN, Oguejiofor IK, DaVault RJ, Albrecht RM, Wong C. Trocar site spigelian-type hernia after robot-assisted laparoscopic prostatectomy. *Urology* 2009;**73**:1423–5.
- Hussain A, Mahmood H, Shuaib S, El-Hasani S. Prevention of trocar site incisional hernia following laparoscopic ventral hernia repair. *JLS* 2008;**12**:206–9. PMC3016175.
- Yamamoto M, Minikel L, Zaritsky E. Laparoscopic 5-mm trocar site herniation and literature review. *JLS* 2011;**15**:122–6. PMC3134687.