



# The value of serum mean platelet volume in testicular torsion

Tufan Cicek<sup>1</sup>, Turhan Togan<sup>2</sup>, Kaan Akbaba<sup>3</sup>,  
Huseyin Narci<sup>4</sup> and Cem Aygun<sup>3</sup>

## Abstract

**Objective:** To compare the serum mean platelet volume (MPV) in patients with testicular torsion and healthy control subjects.

**Methods:** This retrospective study compared clinical and demographic data from patients who underwent surgery for testicular torsion and healthy controls. Testicular torsion was diagnosed with a physical examination and Doppler ultrasonography. Age, leukocyte count, platelet count and MPV were recorded for all participants.

**Results:** A total of 50 patients with testicular torsion and 51 healthy control subjects were enrolled. There was no significant difference in age and platelet count between the two groups. Patients with testicular torsion had a significantly higher leukocyte count and MPV, compared with controls. According to receiver operating characteristic curve analysis performed for the prediction of testicular torsion, the best cut-off point for MPV was 7.7 fl (sensitivity 62%, specificity 96%), and the best cut-off point for leukocyte count was  $9.5 \times 10^9/l$  (sensitivity 58%, specificity 80%).

**Conclusions:** The MPV may be useful as an ancillary test for the diagnosis of testicular torsion. Further studies are needed in order to confirm these preliminary results.

## Keywords

Mean platelet volume, leukocyte, platelet, testicular torsion, diagnosis

Date received: 1 August 2014; accepted: 14 October 2014

<sup>1</sup>Department of Urology, Medical and Research Centre, Baskent University, Konya, Turkey

<sup>2</sup>Department of Infectious Diseases and Clinical Microbiology, Medical and Research Centre, Baskent University, Konya, Turkey

<sup>3</sup>Department of Urology, Faculty of Medicine, Baskent University, Ankara, Turkey

<sup>4</sup>Department of Emergency Medicine, Medical and Research Centre, Baskent University, Konya, Turkey

## Corresponding author:

Dr Tufan Cicek, Department of Urology, Medical and Research Centre, Baskent University, Hocacihan Mah. Saray Cad. No:1, 42082, Selcuklu, Konya, Turkey.  
Email: tufan\_cicek@yahoo.com



## Introduction

Testicular torsion is a clinical condition that is characterized by reduced testicular blood flow as a result of twisting of the spermatic cord around its own axis. Twisting of the spermatic cord is followed by testicular venous occlusion, congestion, and, ultimately, arterial ischaemia and testicular infarction.<sup>1</sup> Testicular torsion is more common in males aged <25 years;<sup>1</sup> affected patients typically present with testicular tenderness and pain. Testicular torsion should be differentiated from other conditions that feature acute scrotal pain including epididymo-orchitis and appendicitis.<sup>2</sup> Differentiation can be achieved by imaging modalities such as scrotal Doppler ultrasonography and scintigraphy. The use of laboratory parameters (e.g. leukocyte count, erythrocyte sedimentation rate, and alkaline phosphatase, creatine kinase and C-reactive protein measurement) has been investigated in the diagnosis of testicular torsion and acute scrotum.<sup>3</sup>

Mean platelet volume (MPV) is a marker of platelet activation.<sup>4</sup> Although routinely analysed along with other indices of the complete blood count (CBC), the MPV is often overlooked by clinicians. Research has suggested the usefulness of MPV in the diagnostic processes of various inflammatory and/or vascular disorders.<sup>4,5</sup> This current retrospective study aimed to investigate whether the MPV value, and the leukocyte and platelet counts, could be used for diagnosing testicular torsion.

## Patients and methods

### *Patient population*

This study retrospectively reviewed the medical records of patients with acute scrotal pain, who presented to the Department of Urology and the Department of Emergency Medicine, Medical and Research Centre, Baskent University, Konya, Turkey and the Department of Urology, Faculty of Medicine,

Baskent University, Ankara, Turkey, between February 2005 and December 2013. Patients diagnosed with testicular torsion underwent orchiectomy and/or surgical detorsion and bilateral testicular fixation. Exclusion criteria included manual detorsion followed by surgery on an elective basis at a later date, myeloproliferative disorders, leukaemia, and Bernard–Soulier Syndrome. A control group included healthy male volunteers selected from individuals who attended the Department of Infectious Diseases and Clinical Microbiology, Medical and Research Centre, Baskent University, Konya, Turkey for an outpatient appointment. The control subjects had no epididymo-orchitis, testicular trauma, testicular tumour, previous scrotal surgery, or abnormal renal or hepatic function tests. Demographic features and findings of a preoperative CBC (which included leukocyte count, platelet count, and MPV) were recorded for all participants. Age, leukocyte count, platelet count, and MPV were compared between the two groups.

Consent was not required from the Ethics Committee of Baskent University, Ankara, Turkey because of the retrospective nature of this study. Written informed consent was routinely obtained from each surgical patient. Verbal informed consent was obtained from all subjects in the control group.

### *Laboratory measurements*

Peripheral venous blood samples (3 ml) were collected into tubes containing 5.4 mg ethylenediaminetetra-acetic acid, and a rapid laboratory analysis was applied to each sample. An electronic cell counter (CELL-DYN<sup>®</sup> 3700; Abbott Laboratories, Abbott Park, IL, USA) was used to measure the CBC. At Baskent University, the expected MPV range was 7.0–12.0 fl, the expected leukocyte count was  $4.5\text{--}11.0 \times 10^9/\text{l}$  and the expected platelet count was  $150\text{--}400 \times 10^9/\text{l}$ .

**Table 1.** Clinical and demographic characteristics of patients with testicular torsion ( $n = 50$ ) compared with a group of healthy control subjects ( $n = 51$ ).

Characteristic	Testicular torsion group, $n = 50$	Control group $n = 51$	Statistical significance <sup>a</sup>
Age, years	$17.8 \pm 8.7$	$18.2 \pm 9.5$	NS
Leukocyte count, $\times 10^9/l$	$11.2 \pm 6.2$	$7.9 \pm 2.2$	$P = 0.005$
Mean platelet volume, fl	$8.3 \pm 1.2$	$7.1 \pm 0.8$	$P < 0.001$
Platelet count, $\times 10^9/l$	$275.9 \pm 81.7$	$295.2 \pm 76.8$	NS

Data presented as mean  $\pm$  SD.

<sup>a</sup>Student's  $t$ -test was used for continuous variables. Leukocyte and platelet counts and mean platelet volume were not normally distributed and thus were compared with the nonparametric Mann–Whitney  $U$ -test across the study groups. NS, no significant between-group differences ( $P \geq 0.05$ ).

### Statistical analyses

All statistical analyses were performed using the SPSS<sup>®</sup> statistical package, version 19.0 (SPSS Inc., Chicago, IL, USA) for Windows<sup>®</sup>. Data were expressed as mean  $\pm$  SD. Student's  $t$ -test was used for continuous variables. The leukocyte and platelet counts and the MPV were not normally distributed and thus were compared with the nonparametric Mann–Whitney  $U$ -test across the two study groups. The correlation between the MPV and the other variables was analysed using Spearman's rank correlation coefficient. A  $P$ -value  $< 0.05$  was considered statistically significant. Receiver operating characteristic (ROC) curve analysis was used to determine the relationship between testicular torsion and MPV and leukocyte count.

### Results

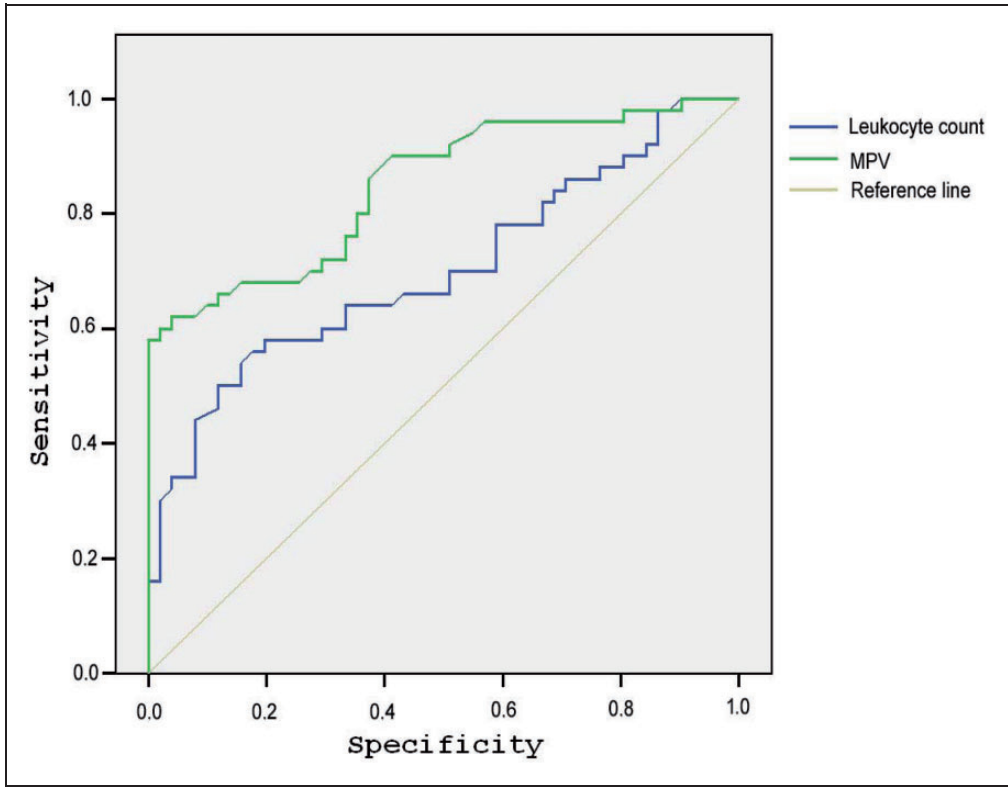
This study retrospectively reviewed the medical records of 350 male participants. A total of 53 patients were diagnosed with testicular torsion. Three patients underwent manual detorsion and under went elective surgery at a later date, so were excluded from the study. Fifty patients underwent orchiectomy and/or surgical detorsion and bilateral testicular fixation for testis torsion (testicular torsion group). Fifty-one healthy volunteers

formed the control group. Clinical and demographic characteristics of study participants are presented Table 1. The mean leukocyte count was significantly higher in the testicular torsion group compared with the control group ( $P = 0.005$ ). The mean MPV was significantly higher in the testicular torsion group compared with the control group ( $P < 0.001$ ). There were no significant differences in mean age and platelet counts between the two groups.

According to the ROC curve analysis performed for the prediction of testicular torsion, the best cut-off point for the leukocyte count was  $9.5 \times 10^9/l$  (sensitivity 58%, specificity 80%, area under curve [AUC]: 0.7) (Figure 1). The same analysis showed that the best cut-off point for MPV was 7.7 fl (sensitivity 62%, specificity 96%, AUC: 0.8) (Figure 1). MPV was significantly correlated with leukocyte count ( $P = 0.0001$ ), but not with platelet count (Table 2).

### Discussion

Measuring the CBC is a frequently used, rapid and inexpensive way of providing valuable information with regard to the diagnosis and follow-up of various disorders. Urologists frequently use CBC for determining inflammatory pathologies and for undertaking routine preoperative



**Figure 1.** Receiver operating characteristic curve of mean platelet volume level (MPV) and leukocyte count.

**Table 2.** Spearman’s rank correlation coefficient analysis of the correlation between mean platelet volume (MPV), leukocyte count and platelet count in patients with testicular torsion ( $n = 50$ ).

Characteristics	Correlation coefficient, $r$	Statistical significance
Leukocyte count – MPV	0.4563	$P = 0.0001$
Leukocyte count – platelet count	0.0018	NS
MPV – platelet count	-0.0719	NS

NS, not significant ( $P \geq 0.05$ ).

assessments of patients scheduled for surgery. Along with providing leukocyte, neutrophil and platelet counts, haemoglobin concentration and haematocrit levels, the CBC also includes some parameters that are often overlooked, such as MPV and red cell

distribution width. In common urological practice, leukocyte count is frequently used for assessing complicated urinary tract infections.<sup>6,7</sup> Leukocytes are immune-system cells that are involved in protecting the body against infectious disease and

foreign invaders.<sup>8</sup> The leukocyte count has also been reported to be increased in testicular torsion.<sup>9</sup> An increased leukocyte count as a result of torsion in the cremasteric muscle tissue surrounding testicular tissue has been reported in Wistar rats; this increase worsened hypoxia, reduced micro-perfusion and lowered the number of functional capillary vessels.<sup>10</sup> The current study similarly observed that the leukocyte count was significantly higher in patients with testicular torsion when compared with the control group.

Mean platelet volume is a parameter that provides information about the functional status of platelets. Assessing platelet volume and structure is helpful in diagnosing various blood disorders such as idiopathic thrombocytopenic purpura and myeloproliferative diseases.<sup>11,12</sup> Larger platelets are both metabolically and enzymatically more active than other platelets and have a greater thrombotic potential due to their contents (i.e. thromboxane A<sub>2</sub>, P-selectin, and glycoprotein IIb/IIIa).<sup>13</sup> Elevated MPV values often indicate accelerated and increased production of young platelets (i.e. megakaryocytes), with a resulting disproportionate increase in the number of large hypercoagulable platelets.<sup>14</sup> Activated platelets also release antibacterial peptides.<sup>15</sup> According to some evidence, however, certain pathogens may have become able to exploit activated platelets and thus to establish or propagate infection by binding to platelet surfaces.<sup>16</sup> In addition, studies have reported some changes in MPV values in certain noninfectious inflammatory processes, possibly suggesting a role for MPV in reflecting the activity of certain inflammatory disorders.<sup>17-19</sup>

There is only one study in the published literature that specifically sought to investigate the relationship between testicular torsion and platelet count, clotting factors, and platelet activating factors.<sup>20</sup> This experimental study reported that platelet

activation had a role in testicular ischaemia because ischaemia-related damage was reduced by the administration of antiplatelet activating factor.<sup>20</sup> To our knowledge, no previous study has examined the MPV in testicular torsion. However, the MPV has been reported to increase in urological vascular pathologies such as varicocele and erectile dysfunction.<sup>21,22</sup> Furthermore, an increase in the MPV has also been observed in conditions like patent foramen ovale, myocardial infarction, and cerebral infarction.<sup>23-25</sup> Therefore, increased MPV values have been considered a vascular risk factor. This current study found no significant difference between the two study groups with respect to platelet count and there was no correlation between MPV and platelet count. In contrast, the MPV was significantly higher in patients with testicular torsion compared with the control group.

Testicular torsion is characterized by the twisting of the spermatic cord around itself, leading to intratesticular venous congestion and interstitial oedema. This situation causes compression in the testicular micro-circulatory system (venous-arteriolar) and alteration of the vascular diameter.<sup>26,27</sup> Studies have shown that testicular venous congestion causes formation of vascular microthrombi that induce the intrinsic coagulation pathway.<sup>27,28</sup> Furthermore, hypoxia has been shown to increase the formation of microthrombi and production of endothelin-1.<sup>29,30</sup> Endothelin-1 is a vasoconstricting factor that acts via endothelin-A receptors.<sup>30</sup> The use of a selective endothelin-A antagonist during the reperfusion period improved the micro-circulatory inflammatory reactions and caused an earlier return of pulsatile blood flow in rats.<sup>30</sup> These published findings suggest that the MPV is elevated in testicular torsion because this condition causes vascular pathology.<sup>26-28</sup>

Erythrocyte sedimentation rate and C-reactive protein, which are acute-phase

markers, have been shown to be elevated during the clinical examination leading to a diagnosis of testicular torsion.<sup>3,31</sup> The MPV was shown to be significantly higher in patients with acute pancreatitis compared with control subjects,<sup>32</sup> but a significantly lower MPV was detected in paediatric patients with acute appendicitis.<sup>33</sup> This current study found a positive correlation between the MPV and leukocyte count, and the MPV had a greater specificity than the leukocyte count for diagnosing testicular torsion. These current findings suggest that the MPV may have been elevated as an acute-phase reactant. The sensitivity of the MPV to diagnose testicular torsion was low (62%) in the present study. To our knowledge, no previous study has examined MPV values in testicular torsion, so it is not possible to compare the present findings with those of other studies.

This current study had a number of limitations. First, it had a retrospective design. Secondly, it only had a small sample size. Thirdly, the control group consisted of healthy men without epididymo-orchitis, but the patient population included a low number of patients of similar age with epididymo-orchitis who underwent a complete blood count and scrotal Doppler ultrasonography. For these reasons, it is difficult to conclude how beneficial it might be to use the MPV as a parameter when excluding inflammatory and noninflammatory causes of testicular torsion. Further research in larger patients groups is required.

In conclusion, although it had a low sensitivity, the MPV may be a useful ancillary marker for diagnosing testicular torsion. Without further published reports on the role of testicular MPV values in relation to specific testicular inflammatory pathologies, the MPV might be helpful but not critical in the diagnosis of testicular torsion. The causes of the MPV elevation in

testicular torsion should be more fully investigated in future studies.

### Declaration of conflicting interest

The authors declare that there are no conflicts of interest.

### Funding

This research received no specific grant from any funding agency in the public, commercial, or not-for-profit sectors.

### References

1. Ringdahl E and Teague L. Testicular torsion. *Am Fam Physician* 2006; 74: 1739–1743.
2. Günther P and Rübber I. The acute scrotum in childhood and adolescence. *Dtsch Arztebl Int* 2012; 109: 449–457.
3. Meštrović J, Biočić M, Pogorelić Z, et al. Differentiation of inflammatory from non-inflammatory causes of acute scrotum using relatively simple laboratory tests: prospective study. *J Pediatr Urol* 2013; 9: 313–317.
4. Gunluoglu G, Yazar EE, Veske SN, et al. Mean platelet volume as an inflammation marker in active pulmonary tuberculosis. *Multidiscip Respir Med* 2014; 9: 11.
5. Bath PM, Missouriis CG, Buckenham T, et al. Increased platelet volume and platelet mass in patients with atherosclerotic renal artery stenosis. *Clin Sci (Lond)* 1994; 87: 253–257.
6. Ayazi P, Mahyar A, Daneshi MM, et al. Diagnostic Accuracy of the Quantitative C-Reactive Protein, Erythrocyte Sedimentation Rate and White Blood Cell Count in Urinary Tract Infections among Infants and Children. *Malays J Med Sci* 2013; 20: 40–46.
7. Chiang MC, Chen HW, Fu RH, et al. Clinical features of testicular torsion and epididymo-orchitis in infants younger than 3 months. *J Pediatr Surg* 2007; 42: 1574–1577.
8. Donaldson TA. Immune responses to infection. *Crit Care Nurs Clin North Am* 2007; 19: 1–8.

9. Yang C Jr, Song B, Liu X, et al. Acute scrotum in children: an 18-year retrospective study. *Pediatr Emerg Care* 2011; 27: 270–274.
10. Boybeyi Ö, Yazici I, Ünlü G, et al. Intravital microscopic evaluation of cremasteric microcirculation in testicular torsion evaluation. *J Pediatr Urol* 2013; 9: 940–944.
11. Ntaios G, Papadopoulos A, Chatzinikolaou A, et al. Increased values of mean platelet volume and platelet size deviation width may provide a safe positive diagnosis of idiopathic thrombocytopenic purpura. *Acta Haematol* 2008; 119: 173–177.
12. Zhang KJ, Lu QY, Li P, et al. Significance of platelet parameters and lactate dehydrogenase level in differential diagnosis for thrombocytosis. *Zhongguo Shi Yan Xue Ye Xue Za Zhi* 2010; 18: 972–975. in Chinese, English Abstract.
13. Kamath S, Blann AD and Lip GY. Platelet activation: assessment and quantification. *Eur Heart J* 2001; 22: 1561–1571.
14. Slavka G, Perkmann T, Haslacher H, et al. Mean platelet volume may represent a predictive parameter for overall vascular mortality and ischemic heart disease. *Arterioscler Thromb Vasc Biol* 2011; 31: 1215–1218.
15. Shannon O. Platelets interact with bacterial pathogens. *Thromb Haemost* 2009; 102: 613–614.
16. Yeaman MR. Bacterial-platelet interactions: virulence meets host defense. *Future Microbiol* 2010; 5: 471–506.
17. Kisacik B, Tufan A, Kalyoncu U, et al. Mean platelet volume (MPV) as an inflammatory marker in ankylosing spondylitis and rheumatoid arthritis. *Joint Bone Spine* 2008; 75: 291–294.
18. Yazici S, Yazici M, Erer B, et al. The platelet indices in patients with rheumatoid arthritis: mean platelet volume reflects disease activity. *Platelets* 2010; 21: 122–125.
19. Kapsoritakis AN, Koukourakis MI, Sfiridaki A, et al. Mean platelet volume: a useful marker of inflammatory bowel disease activity. *Am J Gastroenterol* 2001; 96: 776–781.
20. Palmer JS, Cromie WJ, Plzak LF, et al. A platelet activating factor antagonist attenuates the effects of testicular ischemia. *J Urol* 1997; 158: 1186–1190.
21. Bozkurt Y, Soylemez H, Sancaktutar AA, et al. Relationship between mean platelet volume and varicocele: a preliminary study. *Urology* 2012; 79: 1048–1051.
22. Ciftci H, Yeni E, Demir M, et al. Can the mean platelet volume be a risk factor for vasculogenic erectile dysfunction? *World J Mens Health* 2013; 31: 215–219.
23. Demir B, Caglar IM, Ungan I, et al. Mean platelet volume is elevated in patients with patent foramen ovale. *Arch Med Sci* 2013; 9: 1055–1061.
24. Kiliçli-Camur N, Demirtunç R, Konuralp C, et al. Could mean platelet volume be predictive marker for acute myocardial infarction? *Med Sci Monit* 2005; 11: 387–392.
25. Li B, Liu X, Cao ZG, et al. Elevated mean platelet volume is associated with silent cerebral infarction. *Intern Med J* 2014; 44: 653–657.
26. Bajory Z, Szabó A, Deák G, et al. Orthogonal polarization spectral imaging: a novel tool for examination of microcirculatory changes in the testis. *J Androl* 2012; 33: 499–504.
27. Rattansingh A, Adamson B and Cosgrove D. Bidirectional flow within the intratesticular arteries caused by microvenous thrombosis secondary to testicular torsion. *J Ultrasound Med* 2009; 28: 817–821.
28. Chakraborty J, Sinha Hikim AP and Jhunjhunwala JS. Stagnation of blood in the microvasculature of the affected and contralateral testes of men with short-term torsion of the spermatic cord. *J Androl* 1985; 6: 291–299.
29. Wakafeld TW, Myers DD and Henke PK. Mechanism of venous thrombosis and resolution. *Arterioscler Thromb Vasc Biol* 2008; 28: 387–391.
30. Bajory Z, Varga R, Janovszky Á, et al. Microcirculatory effects of selective endothelin-A receptor antagonism in testicular torsion. *J Urol* 2014; 192: 1871–1877.
31. Asgari SA, Mokhtari G, Falahatkar S, et al. Diagnostic accuracy of C-reactive protein and erythrocyte sedimentation rate in

- patients with acute scrotum. *Urol J* 2006; 3: 104–108.
32. Akbal E, Demirci S, Koçak E, et al. Alterations of platelet function and coagulation parameters during acute pancreatitis. *Blood Coagul Fibrinolysis* 2013; 24: 243–246.
33. Uyanik B, Kavalci C, Arslan ED, et al. Role of mean platelet volume in diagnosis of childhood acute appendicitis. *Emerg Med Int*. DOI: 10.1155/2012/823095.