

Sinonasal inverted papilloma: Recurrence, surgical management, and mini review

Mehmet Emrah Ceylan¹ , Abdullah Dalgıç² , Aynur Aliyeva² , Deniz Tuna Edizer² , Levent Olgun³ 

¹Department of ENT, Isparta Davraz Yasam Hospital, Isparta, Turkey

²Department of ENT, Health Sciences University, İzmir Bozyaka Education Research Hospital, İzmir, Turkey

³ENT Clinic of Otorhinolaryngology, Başkent University Hospital, İzmir, Turkey

Cite this article as: Ceylan ME, Dalgıç A, Aliyeva A, Edizer DT, Olgun L. Sinonasal inverted papilloma: Recurrence, surgical management, and mini review. B-ENT 2021; 17(2): 81-5.

ABSTRACT

Objective: Sinonasal inverted papilloma (SIP) has a high rate of recurrence and a potential to be transformed into a malignant disease, hence surgery is the treatment of choice. In this study, we aimed to identify the preoperative features of patients diagnosed with SIP and discuss treatment options, recurrence rates, and postoperative clinical outcomes.

Methods: Twenty-six patients who were diagnosed with SIP between 2010 and 2014 in a training and research hospital were included in the study. Their charts were reviewed retrospectively. The complaints at admission, findings of anterior rhinoscopy, nasal endoscopy, and radiological examinations were recorded along with histopathological features. Different surgical treatment modalities and recurrence rates were analyzed regarding tumor characteristics and postoperative outcome.

Results: The average postoperative follow-up was 32.1 ± 20 months. According to Krouse classification, 15 (57.7%) patients were staged as T3, eight (30.8%) were T2, and three (11.5%) were T1. Endoscopic sinus surgery was performed in 21 patients. Medial maxillectomy via lateral rhinotomy (classical technique) was performed in five patients. Two patients (7.7%) who had endoscopic surgery had a recurrence of SIP; however, the rate was not statistically significant when compared with that of patients who underwent the classical technique. Histopathological examination revealed chronic rhinosinusitis with nasal polyposis (19.2%), squamous metaplasia (3.8%), and squamous cell carcinoma (7.7%) concurrent with SIP.

Conclusion: Endoscopic surgery should be the first choice for the treatment of SIP. It may be combined with classical methods in some patients with advanced stage disease, especially when the tumor spreads to areas that are difficult to reach. Following surgical intervention, the patients should be followed carefully to identify recurrence or malignant transformation as early as possible.

Keywords: Recurrence, paranasal sinuses, papilloma, inverted, malignancy

Introduction

Sinonasal inverted papilloma (SIP) is a benign tumor originating from the schneiderian mucosa that is characterized by a reverse invagination into the stroma. The incidence of SIP, which is more common among males and peaks in the fifth decade (1), is 0.2–1.5/100,000. SIP requires close follow-up and retreatment when patients have recurrence and potential for malignant transformation. Patients generally admitted with nasal obstruction, epistaxis or rhinorrhea and may have a unilateral mass or nasal polyp upon physical examination.

SIP is treated surgically, and a classical surgical method for the treatment of SIP includes medial maxillectomy via midfacial degloving or lateral rhinotomy. These methods have been widely used as a gold standard; however, the last two decades

have seen a growing preference for the endoscopic technique. Post-surgical follow-up is of great importance for the early detection of recurrence or malignant transformation. In this retrospective study, we aimed to evaluate and analyze the demographic characteristics, surgical techniques, histopathological findings and recurrence rates of patients with SIP.

Methods

Medical records of patients with inverted papilloma who underwent surgery because of sinonasal disease between the years 2010 and 2015 at the Health Sciences University İzmir Bozyaka Education Research Hospital ENT Department were retrospectively reviewed. As this study was a retrospective study, ethics committee approval and informed consent were not obtained, and it was conducted in accordance with the Helsinki Declaration.

Corresponding Author: Mehmet Emrah Ceylan, mrhcyln@gmail.com

Received: November 19, 2020 **Accepted:** May 25, 2021

Available online at www.b-ent.be



CC BY 4.0: Copyright@Author(s), "Content of this journal is licensed under a Creative Commons Attribution 4.0 International License."

Twenty-nine patients with SIP were detected at the initial evaluation. Three patients who underwent revision surgery and

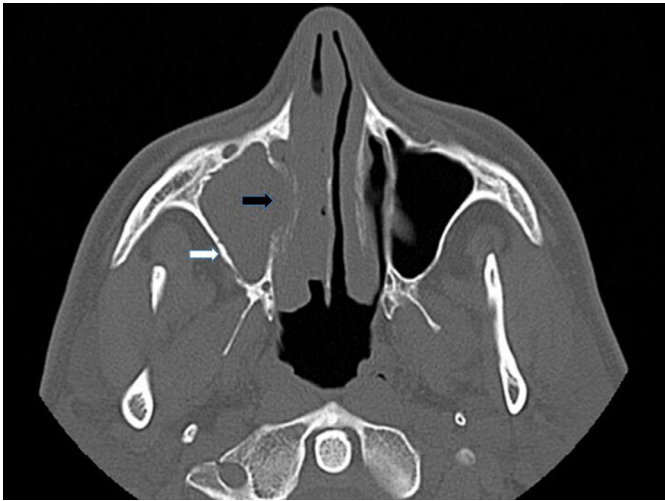

Figure 1. Axial computed tomography section
White arrow: Osteitis at the lateral wall of maxillary sinus; black arrow: Tumor spread through the nasal cavity

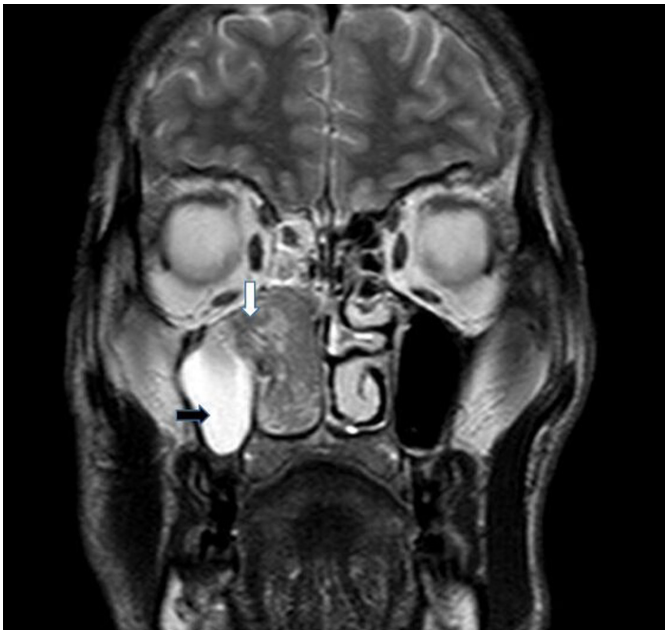

Figure 2. T2 weighted axial magnetic resonance imaging section
White arrow: Convoluted cerebriform pattern; black arrow: Opacity owing to stenosis and inflammation

Main Points:

- Although the diagnosis of otosclerosis is based on a good medical history, physical examination, and audiological findings, the diagnosis can be difficult in some patients.
- Endoscopic pedicle-oriented surgery has a low complication rate and morbidity. It should be the first choice technique, but on rare occasions may be combined with classical methods when the tumor spreads to difficult to reach areas.
- Recurrence of sinonasal inverted papilloma can be detected even years after treatment of the initial disease, and the management of SIP absolutely requires long-term follow-up.

were previously operated upon at another center were excluded from the study. Finally, twenty-six patients who had primary surgery for SIP were included in the study. The descriptive information including patients' complaints and the results of anterior rhinoscopy, nasal endoscopy, and radiological analyses (Figures 1 and 2) were recorded. Histopathological examination was performed on all the surgical specimens. In addition, molecular examination was performed in some patients. The success rate of surgical techniques was analyzed according to stages of Krouse classification system (2). Success criteria was accepted as recurrence rate of surgical technique.

Surgical techniques

In this study, the decision on the type of surgery varied depending on the surgeon's own experience and skill. There were two main surgery options in this study; medial maxillectomy via lateral rhinotomy and conservative endoscopic surgery. Medial maxillectomy via lateral rhinotomy provides en-bloc resection of tumor with at least 1 cm margin of surgical healthy tissue. During endoscopic surgery, the aim is to find the origin by reducing the mass, followed by drilling with a diamond burr (Figure 3). Sinusotomies and ethmoidectomy are also performed if necessary.

Statistical analysis

Statistical analysis was performed with Fisher's exact test using Statistical Package for the Social Sciences, version 15.0 (IBM Corp., NY, USA).

Results

Twenty-six patients (25 men and one woman) were included in the study. The average age of the patients was 54.53 ± 11.23 (range 21–76) years. The average postoperative follow-up was 32.1 ± 20 months. The most common complaint was nasal obstruction (92.3%), and one patient was admitted with epistaxis (7.7%). Thirteen (50%) patients had the disease on the right side, seven (26.9%) on the left, and six (23.1%) had bilateral disease. Twenty of the patients were smokers for 7 to 35 years.

Preoperative biopsy revealed that 25 patients had SIP and one had nasal polyposis. Surgical intervention was performed in accordance to the disease side mentioned above. According to the Krouse classification, 15 (57.7%) patients were staged T3,

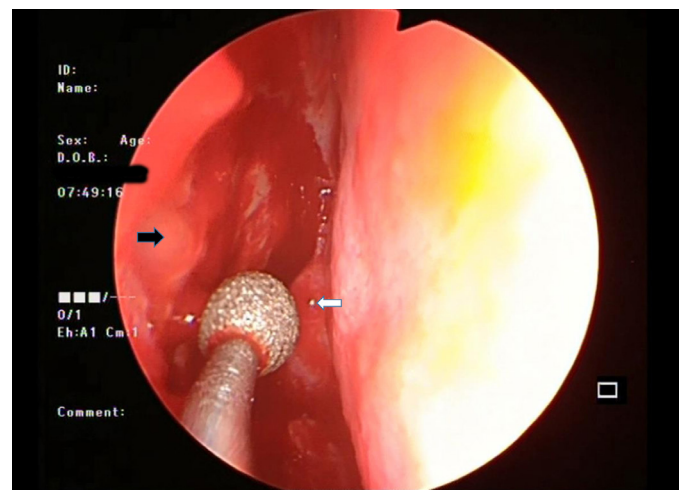


Figure 3. Endoscopic view of the operation site after excision
Black arrow: Burred operation site; White arrow: Right middle turbinate

Table 1. Applied surgical method, Krouse stages, and recurrence rates

| Surgical Approach | T1 Recurrence/n | T2 Recurrence/n | T3 Recurrence/n | T4 Recurrence/n | Total Recurrence/n |
|-------------------|-----------------|-----------------|-----------------|-----------------|--------------------|
| Endoscopic | 0/3 | 0/8 | 2/8 (25%) | - | 2/19 (10%) |
| Endoscopic + CL | - | - | 0/2 | - | 0/2 |
| Lateral rhinotomy | - | - | 0/5 | - | 0/5 |
| Total | 0/3 | 0/8 | 2/15 (13%) | - | 2/26 (7%) |

CL: Caldwell-Luc

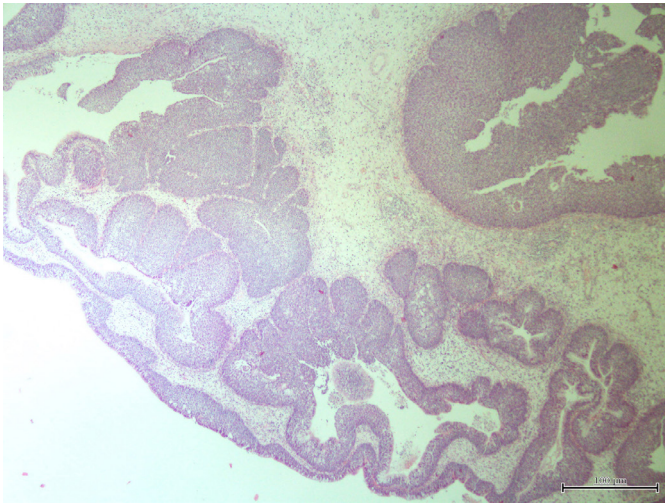


Figure 4. Histopathologic specimen of inverted papilloma (hematoxylin-eosin, 40 x)
Papilloma foci lined with squamous and/or respiratory epithelium in the form of islands in an inverted pattern with invagination to the underlying stroma.

eight (30.8%) T2, and three (11.5%) T1. Medial maxillectomy via lateral rhinotomy was performed in five patients with unilateral disease and endoscopic surgery in 19 (Table 1). During endoscopic surgery, the Caldwell-Luc procedure had to be combined in two patients. Four patients underwent septoplasty to obtain adequate visibility.

Overall complication rate in the early postoperative period was 26.9% (7/26). In the lateral rhinotomy group, transient epiphora on operation side was seen in two patients, paresthesia and hypoesthesia of the cheek and upper lip two, and one patient had both complaints. In the combined Caldwell-Luc and endoscopic surgery group, hypoesthesia at gingival sulcus on operation side was seen in one patient. In the endoscopic surgery group, epistaxis was seen in only one patient. Major complications like cerebrospinal fluid leakage, meningitis, or anosmia were not seen after any surgical intervention.

The overall recurrence rate was 7.6% (2 of 26 patients). There was no recurrence in patients with Krouse stage 1 and 2 (Table 1). Among the patients with Krouse stage 3, recurrence was not seen in the lateral rhinotomy and the combined Caldwell-Luc and endoscopic surgery groups. Although recurrence was seen in two patients with Krouse stage 3 after endoscopic surgery, it was not statistically significant when compared with the lateral rhinotomy group ($P = .487$).

Histopathological examination revealed inverted invagination of schneiderian mucosa in all the patients (Figure 4). Concurrently,

five (19.2%) patients had bilateral nasal polyposis and chronic rhinosinusitis, one (3.8%) had squamous metaplasia, and two (7.7%) had concurrent squamous cell carcinoma. Moreover, five (19.2%) patients had cellular atypia. Among the 26 patients, only 10 were tested for HPV positivity Ki-67 and p53 levels by immunohistochemistry and in-situ hybridization methods. Among these, four had only Ki-67 positivity, four had concurrent Ki-67 and p53 positivity, and two had only HPV positivity.

Discussion

Endoscopic surgery of SIP has been the preferred treatment modality for the last 20 years. Endoscopic technique provides an excellent vision, good cosmetic outcomes, and reduced morbidity. However, the preference for type of surgery show variances because more experienced surgeons prefer the classical technique in open surgery, whereas young surgeons tend to perform endoscopic surgery. In this study, the comparison of success rates of endoscopic and classical techniques was performed with long-term follow-up.

Success criteria of the surgical treatment of SIP is recurrence. Busquets J M et al. (3) reported in a meta-analysis in 2006 that the recurrence rate of the endoscopic method and nonendoscopic method was 12% and 20%, respectively, and stated that endoscopic resection as a favorable treatment option for most cases of SIP. However, in the same year, Peng P et al. (4), in their meta-analysis, reported that the recurrence rate was 15.5% with lateral rhinotomy and 19.6% with the endoscopic method. Furthermore, the recurrence rate was 2.1% in a small number of patients who underwent mid-facial degloving in their own series. In another meta-analysis in 2017, Kim J S et al. (5) mentioned that endoscopic approach reduced the risk of SIP recurrence by 45% for Krouse stage 1 disease; however, an endoscopic approach raised the risk of recurrence by 92% in Krouse stage 4 disease. Another meta-analyses in 2018 by Goudakos J K et al. (6) stated that endoscopic approach is the first choice of surgeons, regardless of the stage of the tumor. Finally in 2019, a meta-analysis which included a total of 96 papers and 4,134 patients with SIP stated that external approaches are no longer the "gold standard" for surgical management of SIP (7). In this study, we confirmed that endoscopic surgery has successful outcomes in patients with Krouse stage 1 and 2 disease, and there was no statistically significant difference between the surgery methods regarding recurrence rate in patients with Krouse stage 3 disease.

Classical surgical methods allow en-bloc and extensive resection of the tumor. Extensive resection in SIP surgery has been suggested owing to its potential for malignant transformation

and high recurrence rates (4). Kim W S et al. (8) proposed that endoscopic medial maxillectomy surgery should be performed in Krouse stages 1 and 2 and that medial maxillectomy via mid-facial degloving should be used in stages 3 and 4. Ungari C et al. (9) suggested that endoscopic methods should only be used in limited tumors (those that are located medially in the sagittal line that cuts the orbital median wall).

It might be wrong to consider the choice of surgical technique or Krouse staging solely when assessing risk of recurrence. In endoscopic surgery especially, during preoperative surgery planning for each patient, the origin of tumor should be determined with radiological examination. Preoperative computed tomography revealed that osteitis was 95% successful in depicting the origin of the tumor (Figure 1) (10). During the magnetic resonance examination, the physician should mark the typical "convoluted cerebriform pattern," which is caused by inflammatory changes as well as the parallel line caused by high and low density in T2 and post contrast T1 series (Figure 2). This typical change may indicate the place of tumor origination (11). Endoscopic pedicle-oriented surgery has been proposed as a method to reduce morbidity and recurrence (12). To reduce the risk of recurrence, diamond burs are used in the area where tumor origin is suspected. The endoscopic view of the patient, in which we used diamond burr after excision of the mass located in front of the maxillary line, is shown in Figure 3.

We believe that the endoscopic pedicle-oriented surgery should be performed as the first choice technique; however, on rare occasions, it should be ensured that the tumor is completely resurfaced with a combination of classical methods such as Caldwell-Luc, or more aggressively, the osteoplastic flap technique. Choosing the appropriate surgical technique to reach the origin of the tumor will reduce the risk of recurrence. Surgeons who prefer endoscopic surgery should be able to master advanced techniques such as Draf procedures and perform it when necessary. It should be taken into consideration that endoscopic medial maxillectomy is also an option to reduce morbidity than classical methods in experienced hands.

In this study, one of the recurrences was in the frontal recess and the other in the lateral wall of the maxilla. Recurrence in the frontal recess was detected two months after surgery. Recurrence in the lateral wall of the maxilla was detected 24 months after surgery. It was thought that inadequate surgery was performed in the patient with early recurrence. The detection of recurrence in the late period suggests that long-term follow-up of patients should definitely be done. Therefore, the endoscopic pedicle-oriented surgery should be the technique of choice and may be combined with classical methods, especially when the tumor spreads to difficult areas to reach, such as frontal sinus or lateral wall of the maxilla.

The association between Krouse staging and recurrence has been investigated. Lisan Q et al. (13) has shown in their meta-analyses that SIP classified as Krouse stage T3 presented a 51% higher likelihood of recurrence than T2 tumors. Tumors may be also highly recurrent if they are located at the anterior, lateral, and inferior wall of the maxillary sinus, in the frontal recess, or lateral to the frontal sinus (14). In addition, SIP can be manifested from more than one site, and multicentric tumors carry a higher risk of recurrence.

The association between SIP recurrence and smoking, viral infections, and chronic inflammation has been widely studied. Although nasal polyps and chronic sinusitis are thought to be risk factors for recurrence; these pathologies are, in general, thought to be more likely associated with SIP and their delayed diagnosis (14). Smoking has not been defined to be a risk factor in the etiology of SIP; however, several studies have reported that it may be a risk factor in its recurrence (15-19). However, in this study, there were 20 patients with a history of cigarette smoking, and none of these patients had recurrence. Two patients with recurrence in this study had no history of smoking.

SIP associated HPV positivity varies between 0% and 79%, and it has been reported that HPV plays a role in the pathogenesis of SIP, but has no role in its etiology and recurrence (20). Katori H et al. (21) have reported that HPV infection is the first step in a complex process, which can be detected early in the malignant transformation of SIP. Von Buchwald et al. (22) have reported that the rate of concurrent carcinoma was 7.1%, and the rate of carcinoma detected in postoperative controls was 3.6%. Similarly, in this study, concurrent squamous cell carcinoma was observed at in two (7.7%) patients.

It has been suggested that SIP recurrence is associated with increased levels of Ki-67, decreased expression of basal cell keratin 14, and high serum concentrations of squamous cell carcinoma antigen (23-25). In this study, both the patients with recurrent SIP had an increase in Ki-67 levels. Although the association of molecular markers such as P53, Ki-67, and HPV infection with malignant transformation has been the subject of many investigations, their role in etiology has not been fully elucidated (26). Ding R et al. (27) stated that the patients infected with HPV types 16, 11/16, 18, and 16/18 were associated with an increased risk of malignant SIP.

Overall complication rate in the early postoperative period was 26.9% (7/26). Lateral rhinotomy was performed in five of these patients. In the lateral rhinotomy group, there were two patients with transient epiphora on the side of operation, two patients who complained about paresthesia and hypoesthesia of the cheek and upper lip, and one patient who had both complaints. In the combined Caldwell-Luc and endoscopic surgery group, there was one patient who had hypoesthesia at the gingival sulcus on the operation side. In the endoscopic surgery group, epistaxis was seen in only one patient. For the management of complications, in patients with transient epiphora, topical steroid and saline irrigation of the nasolacrimal duct were performed for one month. Paresthesia and hypoesthesia of the cheek and upper lip and hypoesthesia of gingival sulcus did not resolve on long-term follow-up. The patient who had epistaxis in the early period was managed with anterior nasal tamponade easily; none of the other patients had any major postoperative complications such as cerebrospinal fluid leakage, meningitis, or anosmia.

We must emphasize the limitations of our study. This was a retrospective study with a small sample size. In this study, there was heterogeneity in the surgical approach methods owing to surgeon preferences. The advantages and minimal morbidity of endoscopic surgery for SIP have shifted the treatment trend in this direction. SIP management is a long-running process involving many factors. When evaluating the risk

of recurrence in SIP, besides Krouse staging and the preferred surgical method, histopathological and immunohistochemical examination should also be taken into account. However, prospective, randomized controlled trial with large clinical series are needed in the future.

In conclusion, owing to the high risk of recurrence and the possibility of transformation into malignancy, the management of SIP requires precise pedicle-oriented endoscopic intervention and long-term follow-up. Although pedicle-oriented endoscopic surgery is adequate for T1, T2, and T3 Krouse stage disease; when necessary, endoscopic surgical methods combined with classical methods may also be performed.

Ethics Committee Approval: Ethics Committee Approval is not necessary due to the retrospective nature of this study.

Informed Consent: Informed consent is not necessary due to the retrospective nature of this study.

Peer-review: Externally peer-reviewed.

Author Contributions: Supervision – M.E.C., A.D., L.O.; Design – M.E.C., A.D., D.T.E., L.O.; Resources – M.E.C., A.D., A.A.; Materials – M.E.C., A.D., D.T.E., L.O.; Data Collection and/or Processing – M.E.C., A.A.; Analysis and/or Interpretation – M.E.C., A.A., D.T.E., L.O.; Literature Search – M.E.C., A.A.; Writing Manuscript – M.E.C., A.D.; Critical Review – A.D., D.T.E., L.O.

Conflict of Interest: The authors have no conflict of interest to declare.

Financial Disclosure: The authors declared that this study has received no financial support.

Acknowledgement: Thanks to Hasan Cem Irkilata for his valuable language and technical editing.

References

- Barnes L, Tse LLY, Hunt J Schneiderian papillomas. In: Barnes L, Eveson JW, Reichart P, Sidransky D, editors. World Health Organization classification of tumours. Pathology and genetics of head and neck tumours. Lyon: IARC; 2005. p.28-32.
- Krouse JH. Development of a staging system for inverted papilloma. *Laryngoscope* 2000; 110: 965-8. [\[Crossref\]](#)
- Busquets JM, Hwang PH. Endoscopic resection of sinonasal inverted papilloma: a meta-analysis. *Otolaryngol Head Neck Surg* 2006; 134: 476-82. [\[Crossref\]](#)
- Peng P, Har-El G. Management of inverted papillomas of the nose and paranasal sinuses. *Am J Otolaryngol* 2006; 27: 233-7. [\[Crossref\]](#)
- Kim JS, Kwon SH. Recurrence of sinonasal inverted papilloma following surgical approach: A meta-analysis. *Laryngoscope* 2017; 127: 52-8. [\[Crossref\]](#)
- Goudakos JK, Blioskas S, Nikolaou A, Vlachtsis K, Karkos P, Markou KD. Endoscopic resection of sinonasal inverted papilloma: systematic review and meta-analysis. *Am J Rhinol Allergy*. 2018; 32: 167-74. [\[Crossref\]](#)
- Peng R, Thamboo A, Choby G, Ma Y, Zhou B, Hwang PH. Outcomes of sinonasal inverted papilloma resection by surgical approach: an updated systematic review and meta-analysis. *Int Forum Allergy Rhinol*. 2019; 9: 573-81. [\[Crossref\]](#)
- Kim WS, Hyun DW, Kim CH, Yoon JH. Treatment outcomes of sinonasal inverted papillomas according to surgical approaches. *Acta Otolaryngol* 2010; 130: 493-7. [\[Crossref\]](#)
- Ungari C, Riccardi E, Reale G., et al. Management and treatment of sinonasal inverted papilloma. *Ann Stomatol (Roma)* 2016; 6: 87-90. [\[Crossref\]](#)
- Bhalla RK, Wright ED. Predicting the site of attachment of sinonasal inverted papilloma. *Rhinology* 2009; 47: 345-8. [\[Crossref\]](#)
- Imura J, Otori N, Ojiri H, Moriyama H. Preoperative magnetic resonance imaging for localization of the origin of maxillary sinus inverted papillomas. *Auris Nasus Larynx* 2009; 36: 416-21. [\[Crossref\]](#)
- Landsberg R, Cavel O, Segev Y, Khafif A, Fliss DM. Attachment-oriented endoscopic surgical strategy for sinonasal inverted papilloma. *Am J Rhinol* 2008; 22:629-34. [\[Crossref\]](#)
- Lisan Q, Moya-Plana A, Bonfils P. Association of krouse classification for sinonasal inverted papilloma with recurrence: a systematic review and meta-analysis. *JAMA Otolaryngol Head Neck Surg*. 2017; 143: 1104-10. [\[Crossref\]](#)
- Xiao-Ting W, Peng L, Xiu-Qing W. et al. Factors affecting recurrence of sinonasal inverted papilloma. *Eur Arch Otorhinolaryngol* 2013; 270: 1349-53. [\[Crossref\]](#)
- Hong SL, Kim BH, Lee JH, Cho KS, Roh HJ. Smoking and malignancy in sinonasal inverted papilloma. *Laryngoscope* 2013; 123: 1087-91. [\[Crossref\]](#)
- Moon IJ, Lee DY, Suh MW. et al. Cigarette smoking increases risk of recurrence for sinonasal inverted papilloma. *Am J Rhinol Allergy* 2010; 24: 325-9. [\[Crossref\]](#)
- Roh HJ, Mun SJ, Cho KS, Hong SL. Smoking, not human papilloma virus infection, is a risk factor for recurrence of sinonasal inverted papilloma. *Am J Rhinol Allergy* 2016; 30: 79-82. [\[Crossref\]](#)
- d'Errico A, Zajacova J, Cacciatore A. et al. Occupational risk factors for sinonasal inverted papilloma: a case-control study. *Occup Environ Med* 2013; 70: 703-8. [\[Crossref\]](#)
- Deitmer T, Wiener C. Is there an occupational etiology of inverted papilloma of the nose and sinuses? *Acta Otolaryngol* 1996; 116: 762-5. [\[Crossref\]](#)
- Giotakis E, Gomatos IP, Alevizos L. et al. Apoptotic and proliferative status in HPV (+) and HPV (-) inverted papilloma patients. Correlation with local recurrence and clinicopathological variables. *Pathol Res Pract* 2012; 208 :338-43. [\[Crossref\]](#)
- Katori H, Nozawa A, Tsukuda M. Markers of malignant transformation of sinonasal inverted papilloma. *Eur J Surg Oncol* 2005; 31: 905-11. [\[Crossref\]](#)
- von Buchwald C, Bradley PJ. Risks of malignancy in inverted papilloma of the nose and paranasal sinuses. *Curr Opin Otolaryngol Head Neck Surg* 2007; 15: 95-8. [\[Crossref\]](#)
- Gunia S, Liebe D, Koch S. Loss of basal cell keratin 14 reflects increased risk of recurrence in surgically resected sinonasal inverted papilloma. *J Clin Pathol* 2008; 61: 707-12. [\[Crossref\]](#)
- Yasumatsu R, Nakashima T, Masuda M., et al. Clinical value of serum squamous cell carcinoma antigen in the management of sinonasal inverted papilloma. *Head Neck* 2005; 27: 44-8. [\[Crossref\]](#)
- Suzuki M, Deng Z, Hasegawa M, Uehara T, Kiyuna A, Maeda H. Squamous cell carcinoma antigen production in nasal inverted papilloma. *Am J Rhinol Allergy* 2012; 26: 365-70. [\[Crossref\]](#)
- Wang, M, Noel J. E. Etiology of sinonasal inverted papilloma: a narrative review. *World Journal of Otorhinolaryngology-Head and Neck Surgery* 2016; 3: 54-8. [\[Crossref\]](#)
- Ding R, Sun Q, Wang Y. Association Between Human Papilloma Virus Infection and Malignant Sinonasal Inverted Papilloma. *Laryngoscope*. 2020; 10: 1002. [\[Crossref\]](#)