

# The structural heart disease interventional imager rationale, skills and training: a position paper of the European Association of Cardiovascular Imaging

Eustachio Agricola<sup>1</sup>, Francesco Ancona<sup>2</sup>, Eric Brochet<sup>3</sup>, Erwan Donal<sup>4</sup>, Marc Dweck<sup>5</sup>, Francesco Faletta<sup>6</sup>, Patrizio Lancellotti<sup>7,8</sup>, Hani Mahmoud-Elsayed<sup>9</sup>, Nina Ajmone Marsan<sup>10</sup>, Pal Maurovich-Hovart<sup>11</sup>, Mark Monaghan<sup>12</sup>, José Ribeiro<sup>13</sup>, Leyla Elif Sade<sup>14</sup>, Martin Swaans<sup>15</sup>, Ralph Stephan Von Bardeleben<sup>16</sup>, Nina Wunderlich<sup>17</sup>, Jose-Luis Zamorano<sup>18</sup>, Bogdan A. Popescu<sup>19</sup>, Bernard Cosyns<sup>20</sup>, and Thor Edvardsen<sup>21,22</sup>

**Reviewers: This document was reviewed by members of the 2018-2020 EACVI Scientific Documents Committee: Philippe Bertrand, Victoria Delgado, Bernard Gerber and Ivan Stankovic**

<sup>1</sup>Cardiovascular Imaging Unit, San Raffaele Hospital, IRCCS, Vita-Salute San Raffaele University, Milan, Italy; <sup>2</sup>Cardiovascular Imaging Unit, San Raffaele Hospital, Milan, Italy; <sup>3</sup>Cardiology Department, Hôpital BICHAT Paris, France; <sup>4</sup>Cardiologie, CHU de RENNES, LTSI UMR1099, INSERM, Université de Rennes-1, Rennes, France; <sup>5</sup>Centre for Cardiovascular Science, University of Edinburgh, Edinburgh, UK; <sup>6</sup>Director of cardiac imaging service, . Cardiocentro Ticino Switzerland; <sup>7</sup>Department of Cardiology, CHU Sart Tilman, University of Liège Hospital, GIGA Cardiovascular Sciences, Liège, Belgium; <sup>8</sup>Gruppo Villa Maria Care and Research, Maria Cecilia Hospital, Cotignola, and Anthea Hospital, Bari, Italy; <sup>9</sup>Consultant Cardiologist, Director of Echocardiography Lab, Al-Nas Hospital, Cairo, Egypt; <sup>10</sup>Department of Cardiology, Leiden University Medical Center, The Netherlands; <sup>11</sup>Medical Imaging Centre, Semmelweis University, Budapest, Hungary; <sup>12</sup>Director of Non-Invasive Cardiology, King's College Hospital, London, UK; <sup>13</sup>Thorax and Circulation Unit Director, Gaia Hospital Center, Oporto, Portugal; <sup>14</sup>University of Baskent, Department of Cardiology, Ankara, Turkey; <sup>15</sup>Department of Cardiology, St. Antonius Hospital, Nieuwegein, The Netherlands; <sup>16</sup>Dep. of Cardiology I, Heart Valve Center, Universitätsmedizin Mainz, Mainz, Germany; <sup>17</sup>Cardiovascular Center Darmstadt, Darmstadt, Germany; <sup>18</sup>University Hospital Ramon y Cajal, Madrid, Spain; <sup>19</sup>Department of Cardiology, University of Medicine and Pharmacy 'Carol Davila' - Eurocolab, Emergency Institute for Cardiovascular Diseases 'Prof. Dr. C. C. Iliescu', Bucharest, Romania; <sup>20</sup>Cardiology Department, Centrum voor Hart en Vaatziekten (CHVZ), Universitair ziekenhuis Brussel, Brussels, Belgium; <sup>21</sup>Dept of Cardiology, Oslo University Hospital, Pb 4950 Nydalen, 0424, Oslo, Norway; and <sup>22</sup>Faculty of Medicine, University of Oslo, Oslo, Norway

Received 5 January 2021; ; editorial decision 6 January 2021; online publish-ahead-of-print 10 February 2021

Percutaneous therapeutic options for an increasing variety of structural heart diseases (SHD) have grown dramatically. Within this context of continuous expansion of devices and procedures, there has been increased demand for physicians with specific knowledge, skills, and advanced training in multimodality cardiac imaging. As a consequence, a new subspecialty of 'Interventional Imaging' for SHD interventions and a new dedicated professional figure, the 'Interventional Imager' with specific competencies has emerged. The interventional imager is an integral part of the heart team and plays a central role in decision-making throughout the patient pathway, including the appropriateness and feasibility of a procedure, pre-procedural planning, intra-procedural guidance, and post-procedural follow-up. However, inherent challenges exist to develop a training programme for SHD imaging that differs from traditional cardiovascular imaging pathways. The purpose of this document is to provide the standard requirements for the training in SHD imaging, as well as a starting point for an official certification process for SHD interventional imager.

## Keywords

Interventional imaging • Structural heart disease • Percutaneous treatment of structural heart disease

## Introduction

Catheter-based treatments of an increasing variety and complexity of structural heart diseases (SHD) have grown dramatically. This expansion has been possible thanks to the developments of new percutaneous devices and the improvement of their performance, but also due to increasing innovation and progress in imaging techniques that help guide these procedures. This huge progress has produced three main effects: (i) a different framework to approach patients with SHD through a multi-disciplinary heart team including members with different expertise and knowledge in order to improve patient care; (ii) the development of a new subspecialty within cardiology and anaesthesiology, so-called 'Interventional Imaging' and consequentially a new dedicated professional figure, the 'SHD Interventional Imager', with specific skills and competences<sup>1</sup>; (iii) the research and development of new imaging tools devoted to this purpose.

The SHD interventional imager has become an integral part and the cornerstone of the heart team by playing a central role in clinical decision-making regarding the appropriateness and feasibility of the procedures as well as in the pre-procedural planning, intra-procedural guidance, and post-procedural follow-up. The SHD interventional imager is therefore crucial during the entire patient pathway and he/she must hold specific cognitive and technical skills encompassing detailed knowledge of the relevant anatomy, SHD, different therapeutic options and available devices, the technical requirements and sequence of the procedures and advanced imaging techniques. Although echocardiography remains the first imaging approach in all paths of care (from decision-making to follow-up), other imaging techniques are also frequently required and provide essential information to guide optimal care.

In this era of continuous expansion of devices and procedures, despite an increased demand for physicians with specific technical skills and advanced imaging competencies in this subject, there are no standardized training programmes and/or requirements for SHD interventional imagers so far.<sup>2</sup> Thus, there is a clear and unmet need for defining and formalizing training programmes and requirements in SHD interventional imaging. Furthermore, an official certification process in this imaging subspecialty will be needed to ensure physicians have the necessary competencies to effectively and safely image patients undergoing in SHD interventions.

The aim of this document is to provide insights into the rationale, requirements, and path for acquiring these competencies and the subsequent certification necessary to succeed in this emerging subspecialty.

## SHD interventional imager

The SHD interventional imager is an imaging expert with specific knowledge and technical skills in all aspects of SHD: clinical, therapeutic, and multimodality imaging. He/she is an integral part of the heart team with specific tasks in overall path of care (*Figure 1*).

There are a number of peculiar competencies of SHD interventional imager (*Table 1*): (i) detailed knowledge of the wide spectrum of SHD, clinical presentation, the natural history, the pathophysiological mechanisms underlying these diseases, and the variability within each disease process to use the best diagnostic and therapeutic options for each individual lesion; (2) the evidence-based

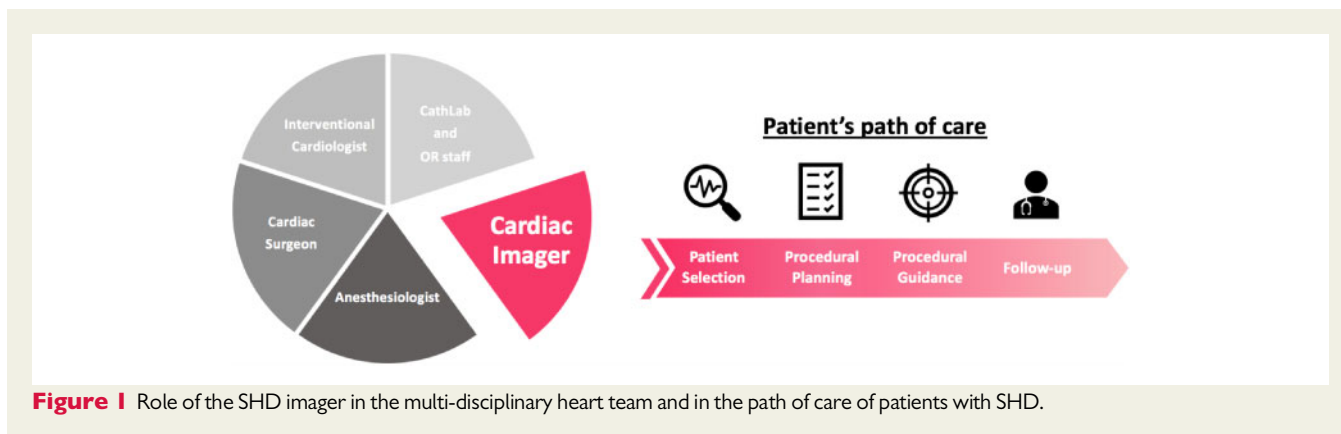
management of SHD; (iii) in-depth, up to date knowledge on the available SHD devices and procedures; (iv) the ability to apply and interpret multimodality imaging. A single imaging modality is often insufficient and cannot provide all the necessary information and different imaging modalities are therefore often complementary. For instance, each procedure consists of different steps and usually, each step needs to be monitored with the most appropriate imaging tool. Thus, the imager has to be able to use interchangeably the most appropriate imaging modality/tool and to merge information derived from different imaging modalities.

The cross-cutting role of imaging in the care pathway of SHD underscores the worth of the SHD interventional imager.<sup>3</sup> He/she participates in appropriate patient selection, helping to assessing the indication and feasibility of a given procedure via the interactive presentation of data derived from different imaging modalities to the heart team. The pre-operative imaging results must be considered alongside historical clinical scans to adjudicate the presence or absence of disease progression and help justify the need for percutaneous or surgical interventions. After establishing candidacy for a structural intervention, multiple imaging modalities are often required for pre-procedural planning of interventions providing a roadmap of anatomy, identifying potential procedural challenges, guiding device selection, and predicting potential complications.<sup>4</sup> SHD interventional imager is an integral part of the procedural team. The know-how for dynamically integrating multimodal imaging results with haemodynamic interpretation is fundamental for procedural success and represents the basis of intra-procedural guidance.<sup>5</sup> During procedure, the SHD interventional imager must provide information about the intracardiac target and status of the therapeutic manoeuvre as well as haemodynamic data to the interventionalist and anaesthesiologist, thereby facilitating optimal conduct of the procedure and haemodynamic management.<sup>5</sup> Establishing common procedural terminology among team members is crucial for the accurate communication needed to achieve this goal. Peri-procedurally and during follow-up, the SHD interventional imager must be able to perform a comprehensive evaluation of the implanted device, assessing its deployment and function and to identify potential complications both as they are occurring during the procedure as well as after mid-/long-term follow-up. Similarly, an adequate evaluation of any residual defect, left ventricular (LV)/right ventricular (RV) remodelling and/or improvement of LV/RV function, and the possible mechanisms underlying disease recurrence during follow-up must be accounted.

The SHD interventional imager can be subject to high levels of radiation exposure in structural cases due to their proximity to the X-ray source.<sup>6,7</sup> Thus, a number of simple measures, such as the use of a protective lead coat, portable lead shielding, radiation reducing (disposable) gloves, and distancing from the X-ray source, must be taken to minimize exposure and the associated risks.<sup>7,8</sup> In addition, the SHD imager should be comprehensively monitored for radiation doses during procedures and a record of cumulative dose maintained.

## Core competences in SHD interventional imaging

The required expertise for SHD imaging is considerably different from traditional cardiovascular imaging and necessitates dedicated



**Figure 1** Role of the SHD imager in the multi-disciplinary heart team and in the path of care of patients with SHD.

training and exposure in multimodality imaging for structural heart interventions.

The core competencies encompass both clinical and technical aspects during the patient care pathway in SHD (Table 2).

## General clinical and technical competencies

A trainee in SHD interventional imaging should have theoretical knowledge of SHD as well-being able to independently perform and/or interpret imaging acquisition and analysis.

In addition to this basic understanding, an advanced knowledge of SHD (valvular and non-valvular) is required for appropriate patient and device selection. The SHD imager should be familiar in advanced quantification of native valvular heart disease, structural defects, and prosthetic valve dysfunction.

A deep familiarity with cardiac anatomy and in particular interventional-oriented anatomy with multimodality imaging is relevant for pre-procedural planning and intra-procedural monitoring.

The SHD interventional imager should be able to perform and interpret comprehensive transthoracic (TTE) and transoesophageal echocardiography (TOE) scans. This should encompass the proper use of 3D imaging including dataset acquisition, online reconstruction, offline post-processing and quantification for pre-procedural planning, intra-procedural monitoring, and post-procedural evaluation. The SHD imager should be able to interpret and re-process computed tomography (CT)/cardiac magnetic resonance (CMR) imaging within dedicated planning software and to understand the particular strengths and weaknesses of these modalities.<sup>9</sup> Integration of the imaging information provided by the different imaging modalities is essential for optimizing patient selection, pre-procedural planning, and the choice of the most appropriate device and/or approach for a specific patient's anatomy (Figure 2). CT in particular allows the identification of appropriate vascular access routes and anatomical variants, and by using dedicated software can evaluate complex anatomical relationships and derive the best fluoroscopic planes for visualizing the native valves and prostheses during the procedure. In addition, it provides valuable information regarding relevant extracardiac pathologies and incidental findings. CMR is of outmost usefulness for pre-procedural evaluation and patient selection in some settings (i.e. patients with dubious severity of mitral regurgitation or patients with congenital heart disease and pulmonary regurgitation,

patients with contraindication to CT) and for follow-up (particularly in patients with congenital heart disease).

## Intra-procedural competencies

In-depth knowledge of device design, their performance as well as the procedural steps for implantation are critical components of the SHD interventional imager's job and important for procedural success. Depending on the procedure, different types of device and catheters are used and each component of them has specific echocardiographic and fluoroscopic features that should be easily recognized by the SHD interventional imager.

A pre-procedural briefing with the team is very useful and should always be carried out to plan a well-defined procedural strategy. Indeed, the SHD interventional imager must establish and share the goal of the procedure for a given patient with the other team members. The expectations (best possible result vs. acceptable result) for the individual patient should be based on their clinical conditions (healthy vs. frail, comorbidities), age (young vs. older, life expectancy), anatomy (easy vs. complex) and technical difficulty (easy vs. challenging).<sup>1</sup>

Real-time imaging monitoring relies mainly on fluoroscopy, with or without the use of iodinate contrast material (angiography), echocardiography, and fusion imaging. The ability to apply multi-modality thinking to integrate and combine clinical information and imaging findings (fluoroscopy and echocardiography) implies a trained skill that imagers can develop over time and through specific education.<sup>10</sup>

Fluoroscopy offers features well-suited to image-guided interventional procedures, including continuous real-time imaging, high temporal resolution, and wide fields of view, as well as optimal visualization of wires, catheters, devices, and calcified structures.<sup>11</sup> The SHD interventional imager has to know: (i) the fluoroscopic anatomy of the heart, which is essential for procedural monitoring and complementary to echocardiographic anatomy; (ii) the orientation: echocardiography and fluoroscopy often do not have the same anatomical direction; (iii) the optimal fluoroscopic views for guiding each procedural step; and (iv) terminology: the usually utilized terms are inappropriate from an anatomical point of view. A common terminology is key bearing in mind that the majority of interventionists do not receive formal training in imaging; and likewise imagers are not usually familiar with fluoroscopic images.

**Table 1** Domain of competencies for SHD imager**Knowledge**

- Pathophysiology, clinical presentation, natural history
- Structural and functional variability within disease process
- Evidence-based treatment options
- Knowledge and continuous updating in current and new devices
- Knowledge and continuous updating in technical aspects of procedures
- Knowledge about potential complications

**Skills**

Appropriate use, technical performance, manipulations, data analysis and interpretation pre-, intra-, and post-procedure of imaging data relevant to specific SHD

- TTE
- TOE
- CT
- CMR
- Fluoroscopy/angiography
- ICE
- Fusion imaging

**Attitudes**

- Integration of imaging-based data and patient condition
- Up to date patient selection for specific procedures
- Guiding the procedure
- Communication with the team, cooperative interaction
- Case-based regular team meetings
- Minimizing procedural complications
- Identification of and coping with complications
- Use of proper instrumentation
- Protection from radiation exposure
- Maximizing patient protection

**Assessment tools**

- Record of clinical experience (logbooks)
- Direct Observation of Practical Skills (DOPS)
- Participation in imaging review meetings and MultiDisciplinary Teams (MDTs)
- Achievement of certifications

CMR, cardiac magnetic resonance imaging; CT, computed tomography; ICE, intracardiac echocardiography; TOE, transoesophageal echocardiography; TTE, trans-thoracic echocardiography.

The SHD interventional imager should be experienced in all echocardiographic modalities [i.e. 2D, 3D, intracardiac echocardiography (ICE)] and be able to use the most appropriate and available echocardiographic tools (i.e. simultaneous biplane, colour-Doppler, multiplanar reconstruction, etc.) in each procedural step for guiding and highlighting particular procedural aspects. Moreover, SHD interventional imager must be able to show the anatomic structures and the device components relevant for the interventionist in the most effective way through the most successful views and perspectives using different echocardiographic modalities. In the setting of percutaneous interventions, artefacts caused by the metallic structures of catheters

**Table 2** Core competences in structural cardiac imaging

General clinical and technical competencies:

- Skill to perform and interpret comprehensive 2D/3D TTE and TOE
- Skill to use 3D imaging including dataset acquisition, online and off-line reconstruction and quantification
- Advanced quantitation of native valvular heart disease, structural defects, and prosthetic dysfunction
- Interventional-oriented cardiac anatomy
- Data analysis and interpretation of CT
- Basic knowledge and appropriate use of CMR

Intra-procedural competencies:

- Establish the goal of the procedure
- Knowledge of device design, performance, and its fluoroscopic and echocardiographic features
- Knowledge of the procedural steps
- In-depth knowledge of all echocardiographic modalities and skill to appropriately use them in each procedural step
- Skill to show the anatomic structures and device in the most effective way by 2D/3D TTE and TOE
- Knowledge of the echocardiographic artefacts and their meaning
- Knowledge of fluoroscopic anatomy, views, orientation, and terminology
- Skill to integrate and combine information from multiple imaging modalities
- Basic knowledge and use of ICE
- Evaluation and interpretation of procedural results
- Interpretation of the haemodynamic parameters
- Rapid recognition of the complications and familiarity with the potential therapeutic options
- Terminology and communication skill

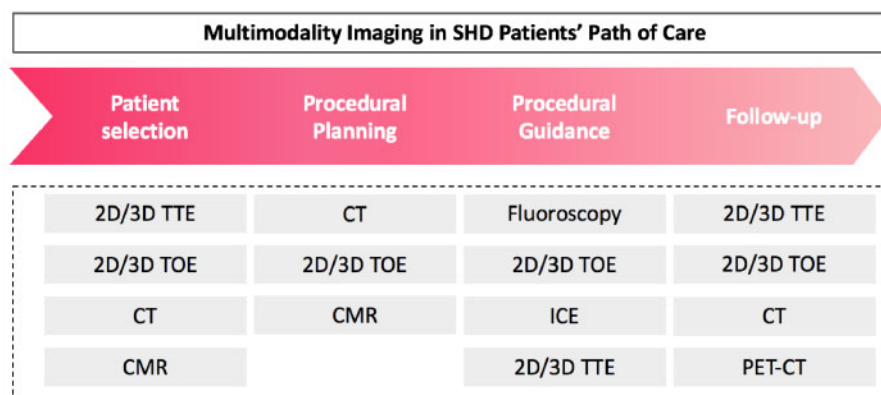
Clinical and technical competencies for post-procedural follow-up:

- Knowledge of device performance and potential dysfunctions
- Knowledge of causes of potential relapse of the defects
- Knowledge and recognition of late complications
- Appropriate use of imaging modalities (TTE, TOE, CT)

and devices are particularly common. The metallic portions of catheters may cause blooming, railroad-shaped, reverberations and shadowing artefacts, which may alter images of catheters and cover (or hide) surrounding structures.<sup>12</sup> Knowing how to recognize these artefacts is of utmost importance to avoid misinterpretation of 2D/3D images.

ICE has already been shown to be helpful in a variety of catheter-based procedures in addition to or, at times, as an alternative to TOE imaging.<sup>13–15</sup> Currently, there is poor experience in the use of ICE in SHD procedures. Therefore, standards for ICE use, competencies, and training requirements are needed.

The procedural results must be interpreted according to the goal of the procedure and device performance and integrating echocardiographic and haemodynamic parameters as well as device function, appearance, and position. Although invasive haemodynamic



**Figure 2** Example of the application of multimodality imaging and different echo tools in all stages of path of care of patients with SHD. An example of transcatheter mitral valve replacement is reported.

monitoring has become less common in the era of advanced cardiac imaging, the comprehension and interpretation of haemodynamic data should be part of core competences of both the interventionalist and SHD interventional imager.<sup>9</sup> Haemodynamic monitoring is useful for early detection of haemodynamic instability, to evaluate treatment efficacy, as well as for the early detection of complications. For instance, in percutaneous mitral valve repairs, changes in left atrial pressures reflect modifications of the regurgitant volume whilst gradients across the valve that can be used to evaluate for the presence of mitral stenosis.

Peri-procedural complications can happen at each procedural step. The SHD interventional imager must know their haemodynamic manifestations and echocardiographic features and be able to rapidly assess them via the appropriate imaging views and modalities. They must also be able to effectively communicate these findings to the interventionalists and anaesthesiologists and to discuss with them the potential therapeutic solutions.

### Clinical and technical competencies for post-procedural follow-up

With the increased number of percutaneous procedures, the number of patients who will need mid and long-term follow-up will proportionally grow up.

Assessment of device performance and function, as well identification of possible relapse of the original defects and the late complications using a multi-modality imaging approach (TTE, TOE, CT, CMR, positron emission tomography-CT) must be part of skills of SHD interventional imager.

## Training programme in SHD imaging

Current training in SHD imaging is fragmented, incomplete, and not formalized. Training in SHD, including imaging, is currently undertaken in several ways<sup>16</sup> (Figure 3): (i) fellowship training; (ii) industry-sponsored device-specific courses that include theoretical and

hands-on training; (iii) on-site proctors; (iv) courses endorsed by scientific society that include live cases and workshops with hands-on training; and (v) simulation training.

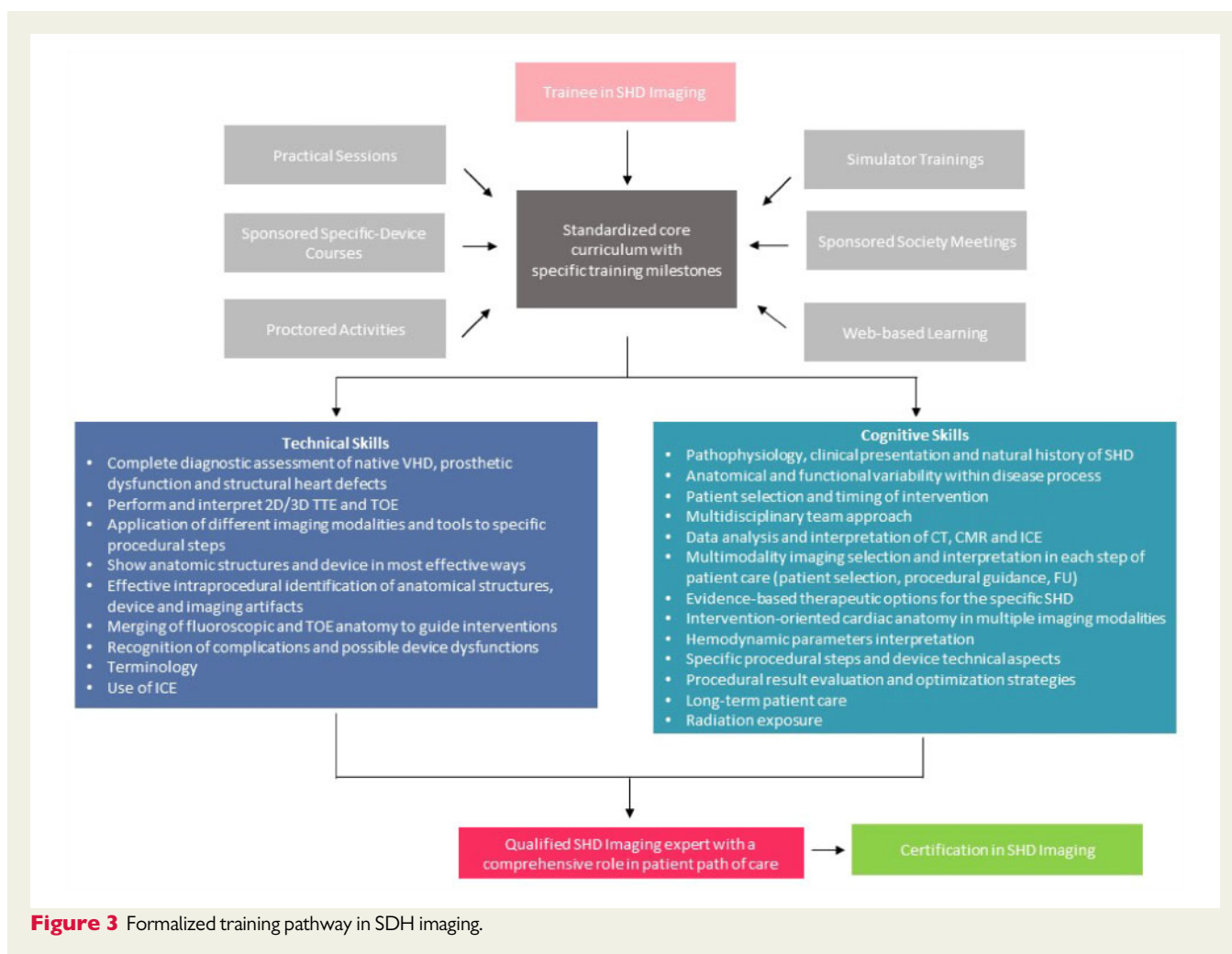
The development of SHD imaging programmes is challenging, there is a clear and unmet need for organizing a well-defined training syllabus outlining the requirements and competencies for physicians intending to perform SHD imaging.<sup>16</sup> Indeed, there are several unique issues to SHD that infer specific challenges to training. The first issue is that the field continues to evolve and expand with almost continuous updates in the medical literature, devices and how the procedures are performed. This implies a need for continuous education in the training curriculum. A second issue relates to the need for adequate exposure to a sufficient volume and a variety of patients and procedures in order to build enough imaging experience. Compared to the volume of coronary procedures per year, the number of SHD procedures is much lower and is often concentrated in a limited number of centres.<sup>17</sup> This has important consequences for the training and dissemination of this imaging subspecialty, with a key aim being to ensure a minimum common international standard in the knowhow of an SHD interventional imager. Indeed, many imaging trainees will not be able to gain sufficient experience during their training to plan and guide SHD procedures independently, and once completed, will also struggle to attain the required volume of experience to remain up-to-date and skilled.<sup>17</sup>

Training in SHD imaging should be reserved for learners who already have advanced level of competence in echocardiography (entrustable professional activity (EPA) level 5 in TTE and TOE), but who also want to become competent in SHD imaging (EPA levels 3, 4, or 5).<sup>18</sup>

The trainee in SHD imaging should follow a structured training programme to acquire the core multi-modality competencies for addressing the learning objectives for patient selection, pre-procedural planning, intra-procedural guidance, and follow-up of SHD interventions.

The training programme should include theoretical educational activities, practical training, and ideally research activities. It has to be comprehensive and should include apart from acquiring knowledge and technical skills development of appropriate behaviours and





attitudes to safely and effectively care for the SHD patients at all points during their care pathway.

During the training period, trainees should regularly attend departmental meetings reviewing topics, presenting and discussing cases, indications, results, procedure-related complications, and data from multimodality imaging techniques. In a complementary approach, other training opportunities such as attending national and/or international accredited imaging meetings, web-based online educational programmes and products, device-specific training, case proctoring, simulation, can be integrated into a standardized training curriculum. Procedural simulation is an alternative way to give technical proficiency and is particularly useful for difficult or uncommon procedures.<sup>16</sup> Although the training duration and the number of the cases are important, the emphasis remains not on these specific metrics but rather on obtaining the required expertise and competencies and in gaining experience across a wide range of procedures, complications, and potential therapeutic options.

Since SHD interventional imager competencies differ substantially from traditional imaging, this subspecialty requires training in advanced centres with structural heart programme comply with local standards according to national regulation bodies, including minimal procedural volumes.<sup>19</sup> The echocardiography laboratories in which training is undertaken should fulfil the EACVI recommendations,

preferably those for an advanced level, equipped with the faculty, facilities, case volume, variety of SHD, and educational services essential to achieve full SHD competency.<sup>19</sup> The training may be integrated in a cardiac imaging department and invasive services (e.g. interventional cardiology, electrophysiology, cardiac surgery), allowing the trainee to be exposed to a full range of imaging techniques and procedures. The commitment of training staff is of paramount importance for training quality supervising, criticizing, and correcting the performance and interpretation of studies.

## Training requirements

A standardized curriculum with specific milestones, core competencies, procedural volume and a formal certification would ensure the optimal approach for imagers to enter this field (Figure 3).

Even though the device companies have their own minimum procedural volume and certification process under supervision of a proctor to become competent for guiding the specific procedure, the requirements of EACVI have intended to provide higher and standardized level of expertise for SHD interventional imager.

What should constitute the minimal portfolio of procedures, their degree of complexity, the number of cases performed for procedural

**Table 3** Proposed building blocks

AV interventions
<ul style="list-style-type: none"> <li>• Aortic valvuloplasty</li> <li>• TAVI</li> <li>• Aortic ViV</li> <li>• Aortic PVL closure</li> </ul>
MV interventions
<ul style="list-style-type: none"> <li>• TSP</li> <li>• PMC</li> <li>• Edge-to-edge repair</li> <li>• Direct and indirect annuloplasty</li> <li>• Chordal repair</li> <li>• Mitral PVL closure</li> <li>• Mitral ViV and ViR</li> <li>• TMVR (transapical and transseptal)</li> </ul>
TV interventions
<ul style="list-style-type: none"> <li>• Edge-to-edge repair</li> <li>• Direct annuloplasty</li> <li>• Tricuspid ViV and ViR</li> <li>• Transvenous TTVI</li> </ul>
Devices for heart failure
<ul style="list-style-type: none"> <li>• InterAtrial shunt devices</li> <li>• LV reconstruction devices</li> </ul>
Other
<ul style="list-style-type: none"> <li>• TSP</li> <li>• LAA closure</li> <li>• PFO closure</li> <li>• ASD closure</li> </ul>

Each procedure within blocks may be assessed and certified for each EPA level (3, 4, or 5) separately.

ASD, atrial septal defect; EPA, entrustable professional activity; LAA, left atrial appendage; PFO, patent foramen ovale; PMC, percutaneous mitral commissurotomy; PVL, paravalvular leak; TAVR, transcatheter aortic valve replacement; TMVR, transcatheter mitral valve replacement; TSP, transseptal puncture; TTVI, transcatheter tricuspid valve implantation; ViR, valve-in-ring; ViV, valve-in-valve.

planning and for intra-procedural guidance to achieve adequate proficiency in SHD imaging are still to be defined. The European viewpoint is that it is not enough for the trainee to perform a specific number of procedures for acquiring the necessary competence. Therefore, although it may be reasonable to ask for a minimum exposure as a prerequisite, the Task Force decided to not focus on numbers but rather on the goal of developing knowledge, well-defined skills, behaviour, and attitudes.<sup>19</sup> However, taking into account the great variability in the level of exposure to different procedures and their complexity, the threshold number of cases needed to achieve a safe level of competence should be set accordingly. Indeed, percutaneous edge-to-edge mitral valve repair, left atrial appendage closure, transcatheter aortic valve implantation (TAVI), transseptal puncture, patent foramen ovale or atrial septal defect closure are more commonly performed, making the level of exposure enough for adequate training in a shorter time. On the contrary, procedures such as paravalvular leak

(PVL) closure, transcatheter mitral valve replacement (TMVR), and percutaneous tricuspid interventions are more complex and less frequently performed, and therefore, the level of exposure is lower and the minimal requirement to achieve competence would necessarily be longer than other procedures.

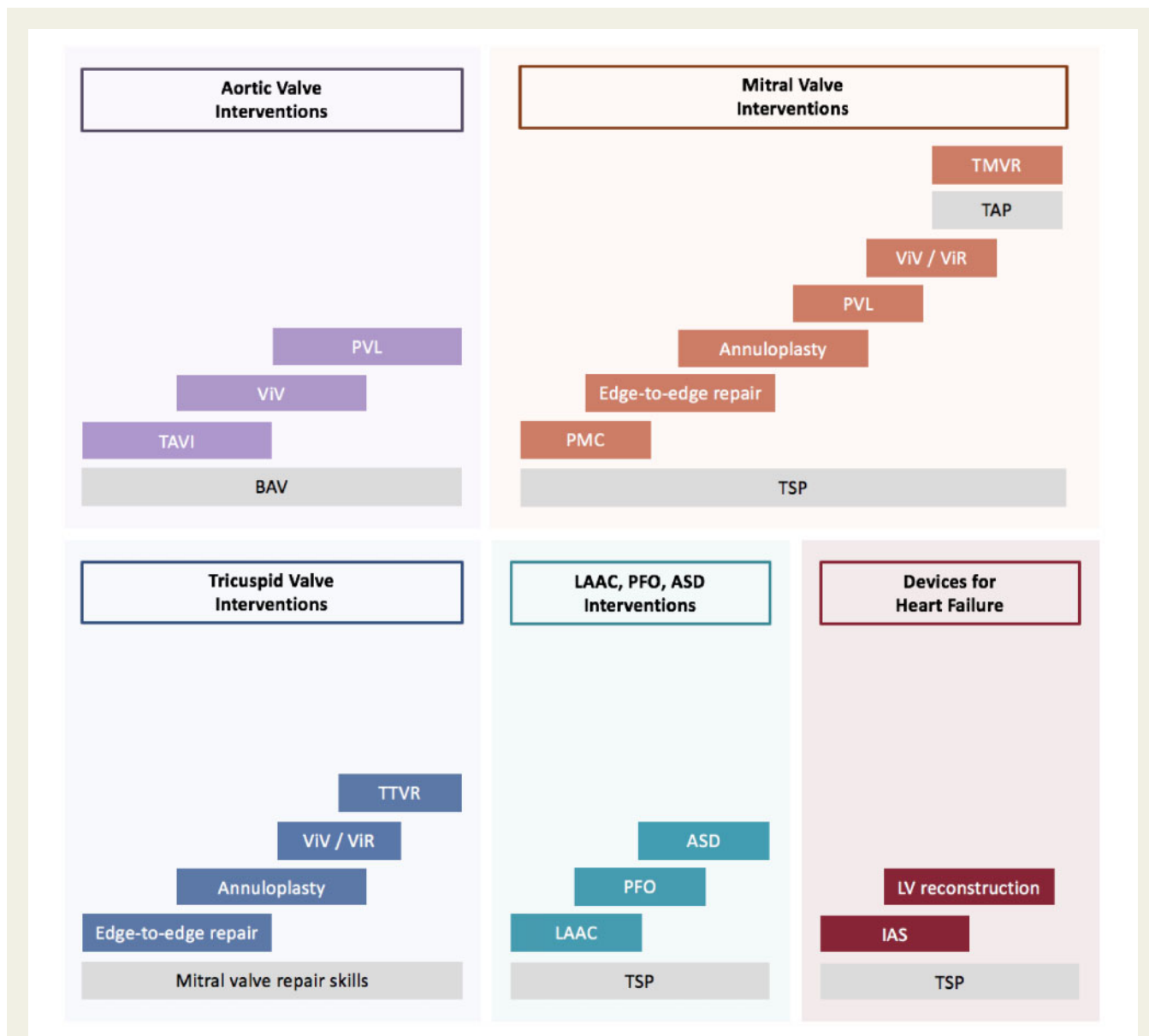
Thus, to overcome these limitations, a modular approach to the core curriculum that considers each procedure within building blocks could be proposed<sup>9</sup> (Table 3, Figure 4). The competency in each procedure within each block may be taught, assessed, and certified separately until independent practice is achieved. Indeed, not every structural interventionist and SHD interventional imager will master all procedures, but they are expected to have acquired the full spectrum of knowledge and technical skills in the core curriculum. Although some procedures can be learned in parallel with others, the mastery of some procedures (steps), such as transseptal puncture or mitral valve repair, is preparatory to more complex procedures consequently the learning and certification process should be organized according to a stepwise model. A strength of this approach is that even with small numbers of specific procedures, procedural competency may be acquired because the skills have already been achieved during other procedures.<sup>9</sup> Furthermore, this approach offers the foundation enabling the SHD imager to adapt quickly to new procedures, devices, and clinical scenarios as they develop and provides a platform for lifelong learning.<sup>9</sup>

In addition to intra-procedural monitoring, training requirements should encompass examination, data analysis, and interpretation during the patient selection and pre-procedural planning stages, including knowledge regarding other imaging modalities for procedures that require them (e.g. CT for TAVR, TMVR, PVL closure, direct mitral valve annuloplasty).<sup>20</sup> Furthermore, the trainee should be exposed to a range of peri-procedural complications. However, the complications are rare and the possibility to face them during training period is by chance. It is recommended that training centres build a library of peri-procedural complications to give the chance to review cases with supervisors. These case reviews should be logged, and the supervisor should certify that the trainee is independently able to recognize these complications.

The supervisor should be an experienced SHD interventional imager with national and or preferably EACVI certification who has been performing unsupervised structural imaging for a minimum of 5 years in an advanced centre.<sup>1</sup> The supervisor should hold national and/or preferably EACVI certification.<sup>19</sup>

Competence assessment requires that the candidate has adequate knowledge, skills, and attitudes which can be assessed in a number of ways<sup>19</sup>: (i) Record of clinical experience (logbooks) and/or Direct Observation of Practical Skills (DOPS); (ii) Participation in imaging review meetings and MultiDisciplinary Teams (MDTs); (iii) Achievement of certifications (examinations). For this subspecialty, the DOPS seems the most appropriate assessment tool giving to the local expert supervisor the responsibility to guarantee competence and assure quality. With this assessment tool, the skills are assessed directly by the supervisor who provides an immediate feedback to identify strengths and areas for development.

The maintenance of individual competence requires evidence of continuing practice (statement from laboratory head) and also evidence of CME activity (e.g. certificates of attendance). The SHD interventional imager should perform procedures contained in building blocks regularly. However, rare procedures are usually executed in specialized centres which are performing these procedures regularly.



**Figure 4** Training requirements and stepwise certification model. SHD and procedures are expressed as component building blocks. Some procedures (i.e. TSP or balloon aortic valvuloplasty) underlie other SHD procedures that may be mastered individually and combined into complete procedures. In this way, SHD imager with experience of edge-to-edge mitral valve repair may extend skills to other most complex procedures on mitral valve. ASD, atrial septal defect; LAA, left atrial appendage; PFO, patent foramen ovale; PMC, percutaneous mitral commissurotomy; PVL, paravalvular leak; TAVR, transcatheter aortic valve replacement; TMVR, transcatheter mitral valve replacement; TSP, transseptal puncture; TTVI, transcatheter tricuspid valve implantation; ViR, valve-in-ring; ViV, valve -in-valve.

For new or rare procedures and where the procedural volume is low, proctoring, and the use of simulators may be helpful. Furthermore, individuals and labs are encouraged to have regular lab meetings to review cases and to discuss new publications and technologies.

## Conclusion

There is an increasing awareness and clinical interest in this interventional imaging subspecialty that requires advanced expertise of

SHD, knowledge of therapeutic options for SHD as well as competencies of multimodality imaging applied to SHD. The training pathway in this subspecialty diverges from, yet is complementary to, that of traditional cardiovascular imaging. There is a vital need for training and certification in this evolving field to become formalized, structured, and standardized. The purpose of this document is to outline the need for a specific training pathway and set of competencies in SHD imaging as well as providing a starting point for the official certification process for SHD interventional imaging.



**Conflict of interest:** E.A.: speaker and proctoring fees, research and educational grant from Philips, Edwards, Abbott, GE, and Siemens. E.B.: Proctoring fees from Abbott. M.D.: speaker fees from Pfizer and have participated on advisory boards for Novartis. F.F.: speaker's fees from Philips. P.M.-H.: Shareholder of Neumann Medical Ltd. M.S.: lecturer/proctor for Abbott Vascular, Boston Scientific, Philips Healthcare, and Bioventrix inc. R.S.V.B.: Trials (unpaid): IIT IZKS University of Göttingen, Abbott Vascular, Bioventrix, Boston Scientific, Edwards Lifesciences, Medtronic; Speaker/Advisory: Abbott Lifesciences, Bioventrix, Boston Scientific, Cardiac Dimensions, Edwards Lifesciences, and Philips. J.-L.Z.: research grants from Abbott. Speaker fee Daichii Sankio, Pfizer. B.A.P.: research grants and lecture fees from GE Healthcare and Hitachi-Aloka.

## References

- Hahn RT, Mahmood F, Kodali S, Lang R, Monaghan M, Gillam LD et al. Core competencies in echocardiography for imaging structural heart disease interventions. *JACC Cardiovasc Imaging* 2019;**12**:2560–70.
- Grapsa J, Kunadian V, Capodanno D, Vidal-Perez R, Radu M, Christia P et al. Joint EACVI HIT/EAPCI young survey/ESC CoT survey: training and education for 'multimodality imaging in structural interventions': the rise of a new subspecialty? *Eur Heart J Cardiovasc Imaging* 2016;**17**:1432–3.
- Swaminathan M. Steve jobs and the value of interventional imagers. *J Am Soc Echocardiogr* 2019;**32**:A17–8.
- Faza NN, Toko MD, Hahn, RT. Imaging in structural heart disease. The evolution of a new subspecialty. *J Am Coll Cardiol Case Rep* 2019;**1**:440–5.
- Wang DD, Geske J, Choi AD, Khalique O, Lee J, Atianzar K et al. Navigating a career in structural heart disease interventional imaging. *JACC Cardiovasc Imaging* 2018;**11**:1928–30.
- Salaun E, Carles S, Bigand E, Pankert M, Aldebert P, Jaussaud N et al. High radiation exposure of the imaging specialist during structural heart interventions with echocardiographic guidance. *JACC Cardiovasc Interv* 2017;**10**:626–7.
- Crowhurst JA, Scalia GM, Whitby M, Murdoch D, Robinson BJ, Turner A et al. Radiation exposure of operators performing transesophageal echocardiography during percutaneous structural cardiac interventions. *J Am Coll Cardiol* 2018;**71**:1246–54.
- Hirshfeld JW Jr, Ferrari VA, Bengel FM, Bergersen L, Chambers CE, Einstein AJ et al. 2018 ACCI/HRS/NASCI/SCAI/SCCT expert consensus document on optimal use of ionizing radiation in cardiovascular imaging: best practices for safety and effectiveness: a report of the American College of Cardiology Task Force on Expert Consensus Decision Pathways. *J Am Coll Cardiol* 2018;**71**:2829–55.
- Raphael CE, Alkhouli M, Maor E, Panaich SS, Alli O, Coylewright M et al. Building blocks of structural intervention: a novel modular paradigm for procedural training. *Circ Cardiovasc Interv* 2017;**10**:e005686.
- Cavalcante JL, Wang DD. Structural heart interventional imagers—the new face of cardiac imaging. *Arq Bras Cardiol* 2018;**111**:645–7.
- Speidel MA. Inverse geometry x-ray imaging: application in interventional procedures. *J Am Coll Radiol* 2011;**8**:74–7.
- Faletra FF, Ramamurthi A, Dequarti MC, Leo LA, Moccetti T, Pandian N. Artifacts in three-dimensional transesophageal echocardiography. *J Am Soc Echocardiogr* 2014;**27**:453–62.
- Alkhouli M, Hijazi ZM, Holmes DR Jr, Rihal CS, Wiegers SE. Intracardiac echocardiography in structural heart disease interventions. *JACC Cardiovasc Interv* 2018;**11**:2133–47.
- Bartel T, Muller S, Biviano A, Hahn RT. Why is intracardiac echocardiography helpful? Benefits, costs, and how to learn. *Eur Heart J* 2014;**35**:69–76.
- Alqahtani F, Bhirud A, Aljohani S, Mills J, Kawsara A, Runkana A et al. Intracardiac versus transesophageal echocardiography to guide transcatheter closure of interatrial communications: nationwide trend and comparative analysis. *J Intervent Cardiol* 2017;**30**:234–41.
- Kavinsky CJ, Poulin MF, Mack MJ. Training in structural heart disease: call to action. *Circulation* 2018;**138**:225–8.
- Steinberg DH, Staubach S, Franke J, Sievert H. Defining structural heart disease in the adult patient: current scope, inherent challenges and future directions. *Eur Heart J Suppl* 2010;**12**:E2–9.
- Tanner FC, Brooks N, Fox KF, Gonçalves L, Kearney P, Michalis L et al. ESC core curriculum for the cardiologist. *Eur Heart J* 2020;**41**:3605–92. doi: 10.1093/eurheartj/ehaa641.
- Popescu BA, Stefanidis A, Fox KF, Cosyns B, Delgado V, Di Salvo G et al. Training, competence, and quality improvement in echocardiography: the European Association of Cardiovascular Imaging recommendations. *Eur Heart J - Cardiovasc Imaging* 2020;**21**:1305–19.
- Pontone G, Moharem-Elgamal S, Maurovich-Horvat P, Gaemperli O, Pugliese F, Westwood M, Document reviewers et al. Training in cardiac computed tomography: EACVI certification process. *Eur Heart J - Cardiovasc Imaging* 2018;**19**:123–6.