

Evaluation of the Appearance, Location and Morphology of Lingual Foramens in Dentates and Edentulous Mandibles Using CBCT

Lingual Foramenin Dişli ve Dişsiz Çenelerde Görünüm, Lokalizasyon ve Morfolojisinin KIBT ile Değerlendirilmesi

✉ Mesude Çıtır¹, ✉ Hazal Karslıoğlu², ✉ Ayşe Pınar Sümer³, ✉ Pelin Kasap⁴

¹Gaziosmanpaşa University Faculty of Dentistry, Department of Dentomaxillofacial Radiology, Tokat, Turkey
²Başkent University Faculty of Dentistry, Department of Dentomaxillofacial Radiology, Ankara, Turkey
³Ondokuz Mayıs University Faculty of Dentistry, Department of Dentomaxillofacial Radiology, Samsun, Turkey
⁴Ondokuz Mayıs University Faculty of Science, Department of Statistics, Samsun, Turkey



Keywords

Dental implant, CBCT, lingual, mandible, vascular

Anahtar Kelimeler

Diş implantı, KIBT, lingual, mandibula, vasküler

Received/Geliş Tarihi : 17.07.2020

Accepted/Kabul Tarihi : 08.02.2021

doi:10.4274/meandros.galenos.2021.97658

Address for Correspondence/Yazışma Adresi:

Mesude Çıtır MD,
 Gaziosmanpaşa University Faculty of
 Medicine, Department of Dentomaxillofacial
 Radiology, Tokat, Turkey
 Phone : +90 356 212 42 22 - 7913
 E-mail : mesudectr@hotmail.com
 ORCID ID: orcid.org/0000-0003-2015-8879

Abstract

Objective: The lingual foramen (LF) in the anterior mandibular region is important for surgical planning. Our aim was to assess the anatomical variations of the mandibular LF and canals using cone beam computed tomography (CBCT).

Materials and Methods: CBCT images of 148 patients were evaluated. The LF presence, number, position, diameter and trajectory was established. The relationship between the findings and gender, dental status was evaluated using Mann-Whitney U, independent samples t-test, and Spearman correlation.

Results: Of 102 patients, 5.9% had the inferior foramen, 60.8% had the superior foramen, and 33.3% had two foramina. The average diameter of the inferior LF was 1.08 mm and superior LF was 1.21 mm. There is a statistical difference between genders according to the diameter of the inferior LF ($p=0.031$).

Conclusion: Due to the prevalence of foraminae of different sizes and locations, we recommend assessing with CBCT before surgical procedures.

Öz

Amaç: Anterior mandibular bölgede lingual foramen (LF) cerrahi planlama açısından önemlidir. Bu çalışmanın amacı mandibular LF ve kanallarının anatomik varyasyonlarını dişli ve dişsiz çenelerde, konik ışınli bilgisayarlı tomografiyi (KIBT) kullanarak değerlendirmektir.

Gereç ve Yöntemler: Yüz kırk sekiz hastanın KIBT görüntüleri incelendi. LF varlığı, sayısı, pozisyonu, çapı ve seyri belirlendi. Bulgular ile cinsiyet, dişlilik durumu arasındaki ilişki, Mann-Whitney U, bağımsız örneklem t-testi ve Spearman korelasyonu kullanılarak değerlendirildi.

Bulgular: Toplam 102 hastanın %5,9'unda inferior foramen, %60,8'inde superior foramen ve %33,3'ünde iki foramen vardı. Ortalama çap inferior LF için 1,08 mm, superior LF için 1,21 mm idi. Inferior LF çapı açısından cinsiyetler arasında istatistiksel açıdan anlamlı bir fark vardı ($p=0,031$).

Sonuç: Orta hatta farklı boyut ve lokalizasyondaki foramenlerin yaygınlığı nedeniyle, cerrahiden önce, KIBT ile değerlendirme öneriyoruz.

Introduction

The lingual foramen (LF) and lingual canal (LC) are located at the internal surface of the anterior region of the mandible. The LF is also defined with various names such as medial LC, lingual vascular canal, lateral LC, mandibular LF. It is called superior genial spinal foramen if it is at the level or above the mental or genial spines, inferior genial spinal foramen if it is below the mental or genial spines, foramen supra spinosum if it is above the mental or genial spines, foramen interspinosum if it is at the level of the mental or genial spines, foramen infrapinosum if it is below the mental or genial spines (1,2).

The descriptions of LF, their canals sizes and locations are critical for better surgical planning and to prevent various complications that may occur pending anterior mandibular dental surgery such as implant, genioplastic, grafting procedures (3). Many authors have reported that damage to the LF vessels during implant procedures results in massive swelling of the floor of the mouth leading to severe upper airway obstruction, as well as life-threatening hemorrhage and the formation of a large hematoma (4,5). Surgery in this region may also affect the branches of the mylohyoid nerve, resulting in paresthesia or hypoesthesia. Therefore, an appropriate radiological evaluation should be performed by dentomaxillofacial radiologists before surgical procedures in this region of the mandible.

LF in the mandible, which is almost invisible on two-dimensional panoramic radiography, can be seen with three-dimensional evaluation on cone beam computed tomography (CBCT) images (6).

The purpose of this study was to evaluate the anatomical variations of LF with cone beam computed tomography imaging in a Turkish population. In addition to evaluating similar parameters in previous studies, we also examined LF according to dental status.

Materials and Methods

In present study, CBCT images of 148 patients were analyzed. The patients ranged in age from 18-71 years with a mean age of 46.22 ± 13.2 years. The approval for the this study was acquired from the Clinical Research Ethics Committee of Ondokuz Mayıs University

(decision number: 2018/500, date: 25.10.2018). All patients signed an informed consent form allowing the use of these records.

The inclusion criteria in this study included the age above 18 years old, no severe atrophy of the mandible and no impacted teeth in the mandible. Exclusion criteria included bone deformities in the mandible and inadequate CBCT image quality.

CBCT images were obtained with the Galileos Comfort Plus CBCT device and the Galaxis viewer program, which is the internal viewer software of the CBCT unit, was used to display the data (Sirona Dental Systems Inc., Bensheim, Germany). The settings were 98 kVp; 25 mAs; 15.4 cm spherical imaging volume field of view, 14 seconds exposure time and 0.25 mm isotropic voxel size. The images are evaluated on RadiForce MX270W, 27" and 3.7 MP color medical LCD monitor (Eizo Nanao Corporation, Ishikawa, Japan).

LF was assessed in 148 patients. Foramen were grouped as superior lingual foramen (SLF) or inferior lingual foramen (ILF) in accordance with to their vertical position relative to the mental spine in 102 patients. Eighty-two of the 102 patients were dentate; 20 of them were edentulous patients. The following items were measured in the 102 CBCT images that LF morphology was proper for all measurements. According to Ali and Ahmad (7) morphological classification, all measurements were made in types A, B and C (Figure 1). Other morphology types were not included in the measurements (Figure 2).

- 1- Diameter of the LF,
- 2- The length of the LC,
- 3- The distance between each foramen to the inferior border of the mandible,
- 4- The distance between from both foramens to the alveolar crest,

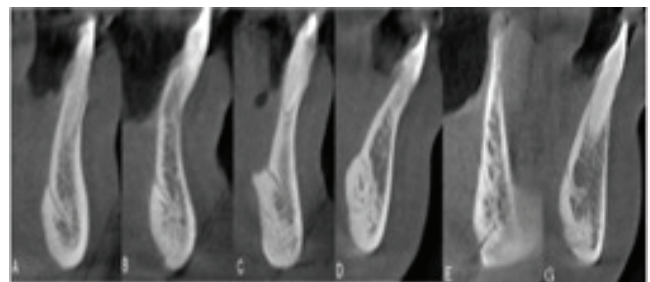


Figure 1. According to Ali and Ahmad (7) anatomical variations of LF morphology
LF: Lingual foramen

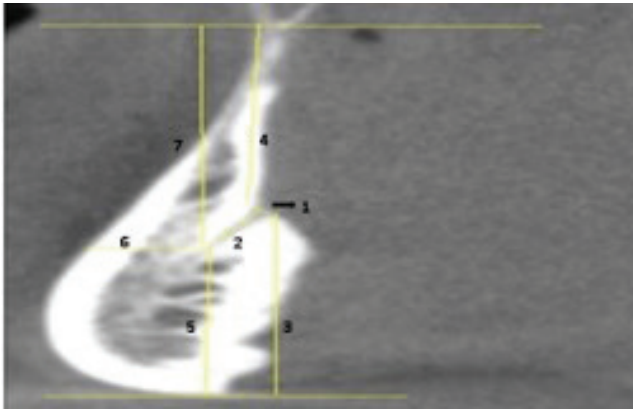


Figure 2. Distance measurements are shown: 1. Diameter of the LF, 2. The length of the LC, 3. The distance LF to the inferior border of the mandible, 4. The distance LF to the alveolar crest, 5. The distance the terminal end of LC from the inferior border of the mandible, 6. The distance the terminal end of LC from buccal plate, 7. The distance the terminal end of LC from alveolar crest

LF: Lingual foramen, LC: Lingual canal

5- The distance between the terminal end of LC from the inferior border of the mandible,

6- The distance between the terminal end of LC from buccal plate,

7- The distance between the terminal end of LC from alveolar crest,

8- Diameter terminal end of LC.

The anatomical variations of LF morphology were carefully categorized according to Ali and Ahmad (7) morphological classification in the 148 CBCT images.

Image Evaluation

The sagittal images were used for measurements. CBCT images were evaluated by one oral and maxillofacial radiologists with more than 5 years of experience and all images were reevaluated after 2 weeks. For distance measurements, one tangent line to the alveolar crest and another one to the inferior border of the mandible were traced; measurements in millimeters were made by drawing a vertical line to these horizontal lines.

Statistical Analysis

Statistical analyses were performed with IBM SPSS statistics 21.0 for Windows PC (IBM Corp., Armonk, NY, USA). Mann-Whitney U, independent sample t-tests and Spearman's Rho correlation were used. P values less than 0.05 was regarded to be significant. The intraobserver agreement assessed by the Kappa.

Results

For the anatomical variations of LF morphology 68 foramens were type A, 30 foramens were type B, 4 foramens were type C, 21 foramens were type D, 10 foramens were type E and 15 foramens were type G (Figure 2).

A total of 102 patients had one or two LF. Six (3 female, 3 male) of patients had ILF, 62 patients (27 male, 35 female) had SLF. Thirty four patients (14 male, 20 female) had two LF. So 136 LF were detected, totally. Four of patients who had only ILF showed a dentate anterior mandible and two of the patients were edentulous. Fifty two of patients who had only SLF showed a dentate anterior mandible and ten of the patients were edentulous. Of the patients with two LFs, 26 were dentate and eight were edentulous. The mean measurements for ILF and SLF are shown in Table 1. For superior and inferior LF types, Table 2 shows the mean distances and diameter measurements in male and female. The mean diameter of the ILF was 1.29 ± 0.58 mm in male patients; 0.92 ± 0.40 mm in female patients. There is a statistically significant difference between genders according to the diameter of the ILF ($p=0.031$; Table 2).

The mean length of the inferior canal 5.74 ± 2.49 mm and length of superior type canal is 6.81 ± 1.98 mm. The average distance from SLF to the inferior border of mandible is 14.10 ± 2.77 mm. There is a statistically significant difference between genders ($p=0.002$; Table 2).

Table 1. Average measurement values of SLF and ILF		
	SLF	ILF
	Mean (mm) \pm SD	Mean (mm) \pm SD
The diameter of LCs	1.21 ± 1.42	1.08 ± 0.52
The length of the LC	6.81 ± 1.98	5.74 ± 2.49
The distance between LF and inferior border of mandible	14.10 ± 2.77	4.16 ± 2.65
The distance between LF and alveolar crest	14.73 ± 3.17	23.51 ± 5.02
The diameter end of LC	0.75 ± 0.28	0.68 ± 0.35
The distance between the terminal end of LC from buccal plate	5.72 ± 2.07	5.36 ± 1.58

SLF: Superior lingual foramen, ILF: Inferior lingual foramen, LC: Lingual canal, LF: Lingual foramen, SD: Standard deviation

Table 2. Measurements according to gender in the ILF and SLF

	Male				Female				p	
	Med (min-max)		Mean (mm) ± SD		Med (min-max)		Mean (mm) ± SD		ILF	SLF
	Inferior	Superior	Inferior	Superior	Inferior	Superior	Inferior	Superior		
The diameter of LC	1.01 (0.55-2.26)	0.92 (0.48-3.45)	1.29±0.58	1.12±0.54	0.86 (0.32-1.81)	0.91 (0.42-10.74)	0.92±0.40	1.28±1.82	0.030 ^b	0.201 ^a
The length of LC	5.61 (2.4-12.96)	6.95 (3.10-11.59)	5.75±2.87	7.12±2.07	9.12 (2.49-10.00)	6.63 (2.88-12.12)	5.73±2.24	6.57±1.90	0.984 ^b	0.183 ^b
The distance between LF and inferior border of mandible	4.02 (0.98-13.58)	14.6 (12.12-18.72)	4.74±3.34	14.81±1.62	3.59 (1.03-10.03)	13.58 (0.76-27.59)	4.03±2.37	13.57±3.30	0.665 ^a	0.002 ^a
The distance between LF to alveolar crest	23.47 (15.14-34.01)	15.44 (8.85-23.46)	23.94±5.8	15.27±3.21	24.13 (11.96-31.32)	14.39 (3.87-20.52)	23.20±4.47	14.33±3.12	0.650 ^b	0.265 ^a
The distance between the terminal end of LC from buccal plate	6.09 (1.83-9.17)	5.76 (2.61-13.35)	5.75±2.02	6.11±2.36	5.07 (3.20-7.20)	5.55 (0.54-10.96)	5.07±1.13	5.43±1.78	0.221 ^b	0.111 ^b

Min: Minimum, Max: Maximum, Med: Median, SD: Standard deviation, LC: Lingual canal, LF: Lingual foramen, ILF: Inferior lingual foramen, SLF: Superior lingual foramen, ^aMann-Whitney U test, ^bIndependent samples t-test

The mean distance between the terminal end of superior LC from the inferior border of the mandible is 11.74±2.92 mm in male, 9.74±2.22 mm in female patients (Table 2). For superior type, there is a statistically significant difference between the genders (p=0.000).

The relationship of distances and diameters with age was evaluated with Spearman's Rho correlation. There is no significant relationship between age and distances-diameters (p>0.05).

For the superior and inferior LF types, Table 3 presents the mean distance and diameter measurements in dentate and edentulous patients. For ILF type, there is a statistically significant difference with 95% confidence between the dentate and edentulous patients in terms of distance to alveolar crest (p=0.001; Table 3). For SLF type, there is a statistically significant difference with 95% confidence between the dentate and edentulous patients in terms of distance to alveolar crest (p=0.016; Table 3).

In the evaluation of the radiographic measurements, the intraobserver agreement was found to be excellent (k=0.90).

Discussion

It has been reported that the number of postoperative complaints has increased in parallel with the increasing use of implants in recent years. Thus, accurate and detailed radiological information about anatomical landmarks of mandibular interforaminal region related to dental implant placement is necessary for careful preoperative planning. Although it is known that the LF is located on the lingual side of the mandible, its location and number are defined variously and inconsequently (5). In different studies, LF was detected in approximately 99.0% of the mandible (1,8).

In Abesi et al. (9) the anatomical variations of LF morphology in the mandible were 39.5% type A, 54% type B, 1.5% type C, 0.5% type D, 1% type E, and 3.5% type G. Although in our study, the most common LF morphology was type A and the rarest was type C. Also, F-type foramen morphology was not observed.

We found that 67% patients had one LF and 33% patients had two LF. Sekerci et al. (8) reported that of 500 patients, 17% had one foramen, 28.2% had two foramen, 53% had more than two foramen and 1.8% had no foramen. Liang et al. (6) stated that 72% of

Table 3. Measurements according to dentate/edentulous in the ILF and SLF

	Dentate				Toothless				P	
	Med (min-max)		Mean (mm) ±SD		Med (min-max)		Mean (mm) ± SD		Inferior	Superior
	Inferior	Superior	Inferior	Superior	Inferior	Superior	Inferior	Superior		
The distance between LF and inferior border of mandible	3.18 (1.03-13.58)	14.27 (10.55-27.59)	4.25±3.00	14.49±2.30	4.03 (0.98-9.54)	13.64 (0.76-16.83)	4.59±2.50	12.43±3.92	0.469 ^a	0.053 ^a
The distance between LF to alveolar crest	25.12-25.19 (17.09-34.01)	14.70-15.06 (7.36-23.46)	24.98±4.39	15.24±2.68	18.04-19.90 (11.96-25.03)	13.18-13.36 (3.87-19.18)	19.09±4.27	12.53±4.17	0.001 ^b	0.016 ^b
The distance between the terminal end of LC from buccal plate	5.23-5.27 (2.70-9.17)	5.62-5.70 (0.54-13.35)	5.34±1.47	5.68±2.09	5.59-6.05 (1.83-8.14)	5.24-5.45 (3.09-9.43)	5.40±1.96	5.93±1.98	0.919 ^b	0.638 ^b
The diameter end of LC	0.63 (0.27-2.33)	0.68 (0.33-1.91)	0.68±0.39	0.75±0.29	0.58 (0.43-1.17)	0.68 (0.45-1.44)	0.70±0.23	0.78±0.26	0.469 ^a	0.693 ^a

Min: Minimum, Max: Maximum, Med: Median, SD: Standard deviation, LC: Lingual canal, LF: Lingual foramen, ^aMann-Whitney U, ^bindependent samples t-test

patients had a single foramen, 22% had two foramen and 4% had three foramen. These differences may be due to the limited number of patients and different racial characteristics.

The result of the present study as regards the localization of the LF, showing 91% of patients with one LF were of the superior type, is in consistent with previous studies. However, this finding creates a disadvantage for surgical operations performed in this region. In patients with a single inferior LC, canal localization allows deeper flap surgery or deep implant placement (10).

Large LF can cause severe bleeding in the floor of the mouth due to implants and other surgical procedures. Previous studies grouped the diameters of foramen as ≤1 mm and >1 mm to define the risk of severe bleeding (11,12). Even though it was reported that the average diameter of the canals was 0.86 mm, this measurement differs according to the racial characteristics in previous studies (8,13). In the study conducted by Sekerci et al. (8) the mean horizontal diameter was 0.89 mm and the mean vertical diameter was 1.16 mm in the Turkish population. In consistent with previous studies, we found that the mean diameter of ILF and SLF are 1.07 mm, 1.20 mm, respectively.

Similar to He et al. (1) and von Arx et al. (13), we stated that there was no statistically significant association between diameters of the LF and age. However, Abesi et al. (9) reported a significant relationship between LF diameter and age groups.

In previous studies, inferior canal length was reported between 4.25 and 6.33 mm, and superior canal length was reported between 5.81 and 7.83 mm (13-15). In our study, LC length was measured close to the literature and superior canal length was found higher than inferior, similar to literature.

Aoun et al. (16) reported the distance from the SLF to the alveolar crest in males was greater than in females. However, in this study there was no statistically significant difference between the genders. The distance between the LF and the alveolar crest is clinically important for implant surgery as it may limit the length of the implant to be placed (17). This distance should be evaluated more carefully, especially in atrophic crest.

In previous studies, the average distance from the superior LF to the inferior border of the mandible

was found between 12.58 and 14.12 mm (13,14,18), similar to us. Choi et al. (18) stated that the mean distances from the inferior border of the mandible to SLF was 12.65 mm. In our study, this value was higher than the literature. This distance should be considered when determining the length of the implant to be placed, especially in atrophic mandibles.

Sheikhi et al. (14) reported that the mean diameter of end of the ILF was greater in female patients, and for the SLF, the mean diameter was greater in male, similar to our results. Arun Kumar (19) investigated that the average distance from end of the LF to alveolar crest in male was 13.45 mm and in female 12.95 mm. The mean distance from end of the LF to inferior border of mandible in male was 8.20 mm and in female 7.70 mm. Sheikhi et al. (14) and we found these values higher in male, similar to Arun Kumar (19) results.

The number of the studies evaluating the relationship between dental status and LF morphology is limited. In a recent study, Trost et al. (20) stated that edentulous patients did not differ in terms of the presence of LF, but vertical bone dimensions decreased by 7 mm on CT image. Similarly we found a statistically significant difference between dentate and edentulous patients in terms of the distance of the LF to the alveolar crest. Despite similar results and the higher number of patients than ours, the high radiation dose in CT is an important disadvantage of their study. To our knowledge, our study may be the first retrospective study performing on patients' CBCT images evaluating the relationship between dental status and LF morphology.

Conclusion

Due to the prevalence of foramina of different sizes and locations in the midline, we recommend routine screening of the anterior mandible using CBCT for any surgical intervention that may damage the lingual cortical of the anterior mandible. Careful pre-operative planning and evaluation of anatomical structures accurately with the use of three-dimensional imaging may help to avoid surgical complications. Existing studies mostly belong to dentulous patients; but, edentulous patients need more implants. Further studies are required by increasing the number of dentate and edentulous patients.

Ethics

Ethics Committee Approval: The approval for the this study was acquired from the Clinical Research Ethics Committee of Ondokuz Mayıs University (decision number: 2018/500, date: 25.10.2018).

Informed Consent: All patients signed an informed consent form allowing the use of these records.

Peer-review: Externally and internally peer-reviewed.

Authorship Contributions

Surgical and Medical Practices: M.Ç., Concept: H.K., A.P.S., Design: A.P.S., Data Collection or Processing: M.Ç., Analysis or Interpretation: M.Ç., P.K., Literature Search: M.Ç., H.K., Writing: M.Ç., H.K.

Conflict of Interest: No conflict of interest was declared by the authors.

Financial Disclosure: The authors declared that this study received no financial support.

References

1. He X, Jang J, Cai W, Pan Y, Yang Y, Zhu K, et al. Assessment of the appearance, location and morphology of mandibular lingual foramina using cone beam computed tomography. *Int Dent J* 2016; 66: 272-9.
2. Sanomiya Ikuta CR, Paes da Silva Ramos Fernandes LM, Poleti ML, Alvares Capelozza AL, Fischer Rubira-Bullen IR. Anatomical Study of the Posterior Mandible: Lateral Lingual Foramina in Cone Beam Computed Tomography. *Implant Dent* 2016; 25: 247-51.
3. Jacobs R, Lambrichts I, Liang X, Martens W, Mraiwa N, Adriaenssens P, et al. Neurovascularization of the anterior jaw bones revisited using high-resolution magnetic resonance imaging. *Oral Surg Oral Med Oral Pathol Oral Radiol Endod* 2007; 103: 683-93.
4. Kawai T, Sato I, Yosue T, Takamori H, Sunohara M. Anastomosis between the inferior alveolar artery branches and submental artery in human mandible. *Surg Radiol Anat* 2006; 28: 308-10.
5. Mraiwa N, Jacobs R, Van Steenberghe D, Quirynen M. Clinical assessment and surgical implications of anatomic challenges in the anterior mandible. *Clin Implant Dent Relat Res* 2003; 5: 219-25.
6. Liang X, Jacobs R, Hassan B, Li L, Pauwels R, Corpas L, et al. A comparative evaluation of cone beam computed tomography (CBCT) and Multi-Slice CT (MSCT): Part On subjective image quality. *Eur J Radiol* 2010; 75: 265-9.
7. Ali A, Ahmad M. Anatomical variation of the lingual mandibular canals and foramina. *Northwest Dent* 2008; 87: 36-7.
8. Sekerci AE, Sisman Y, Payveren MA. Evaluation of location and dimensions of mandibular lingual foramina using cone-beam computed tomography. *Surg Radiol Anat* 2014; 36: 857-64.

9. Abesi F, Ehsani M, Haghanifar S, Sohaniand S. Assessing the Anatomical Variations of Lingual Foramen and its Bony Canals with CBCT. *IJSBAR* 2015; 20: 220-7.
10. Liang X, Jacobs R, Lambrichts I, Vandewalle G. Lingual foramina on the mandibular midline revisited: a macroanatomical study. *Clin Anat* 2007; 20: 246-51.
11. Yildirim YD, Güncü GN, Galindo-Moreno P, Velasco-Torres M, Juodzbaly G, Kubilius M, et al. Evaluation of mandibular lingual foramina related to dental implant treatment with computerized tomography: a multicenter clinical study. *Implant Dent* 2014; 23: 57-63.
12. Babiuc I, Tărlungeanu I, Păuna M. Cone beam computed tomography observations of the lingual foramina and their bony canals in the median region of the mandible. *Rom J Morphol Embryol* 2011; 52: 827-9.
13. von Arx T, Matter D, Buser D, Bornstein M. Evaluation of location and dimensions of lingual foramina using limited cone-beam computed tomography. *J Oral Maxillofac Surg* 2011; 69: 2777-85.
14. Sheikhi M, Mosavat F, Ahmadi A. Assessing the anatomical variations of lingual foramen and its bony canals with CBCT taken from 102 patients in Isfahan. *Dent Res J (Isfahan)* 2012; 9: 45-51.
15. Liang X, Jacobs R, Lambrichts I. An assessment on spiral CT scan of the superior and inferior genial spinal foramina and canals. *Surg Radiol Anat* 2006; 28: 98-104.
16. Aoun G, Nasseh I, Sokhn S, Rifai M. Lingual Foramina and Canals of the Mandible: Anatomic Variations in a Lebanese Population. *J Clin Imaging Sci* 2017; 7: 16.
17. Kilic E, Doganay S, Ulu M, Çelebi N, Yikilmaz A, Alkan A. Determination of lingual vascular canals in the interforaminal region before implant surgery to prevent life-threatening bleeding complications. *Clin Oral Implant Res* 2014; 25: 90-3.
18. Choi DY, Woo YJ, Won SY, Kim DH, Kim HJ, Hu KS. Topography of the lingual foramen using micro-computed tomography for improving safety during implant placement of anterior mandibular region. *J Craniofac Surg* 2013; 24: 1403-7.
19. Arun Kumar G. Anatomical variations of lingual foramen and it's bony canals with cone beam computerised tomography in south indian population—a cross sectional study. *Oral Health Care* 2017; 2: 1-6.
20. Trost M, Mundt T, Biffar R, Heinemann F. The lingual foramina, a potential risk in oral surgery. A retrospective analysis of location and anatomic variability. *Ann Anat* 2020; 231: 151515.